



:
 : 2002 3 2003 8 120 ,
 6
 (59 , 2 , 4).
 7F 0.035 0.016 가
 가
 : 5 가
 . 1 가
 :

5 가 , 1
 4 , 1 , 1
 (1, 2). 5 22G 1
 가 (3). 가
 7F
 0.035
 5 - 6 mm, 8 - 10 mm
 (Ultra - thin Diamond, Boston Scientific, Natick, MA)
 15 - 20 , 1 - 2
 가
 2002 3 2003 8 가 (Blue max
 120 20TM Boston Scientific, Natick, MA)
 가 6 2 , 4
 31 - 75 (: 59) , 0.035 5F
 (Torcon NB Advantage, Cook,

1
 2
 3
 2006 6 24 2006 8 18
 5F 0.035
 451
 Bloomington, IN) , 0.016
 (Wire Guide, Cook, Bloomington. IN)

0.016

(cephalic vein) 5 , 1 .
1 - 5 cm

가 3 . 5 4

(Fig. 1).

5F

가

가

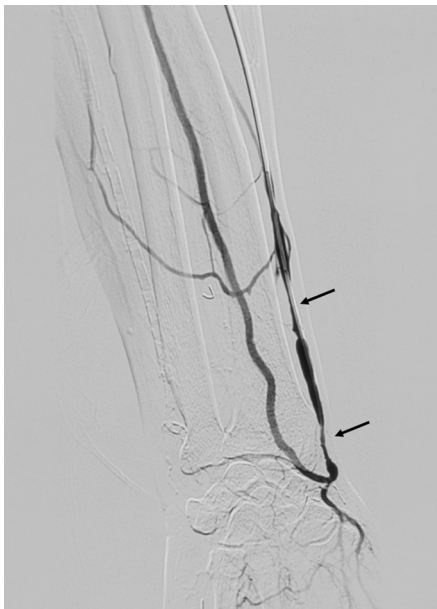(Fig. 2).

1

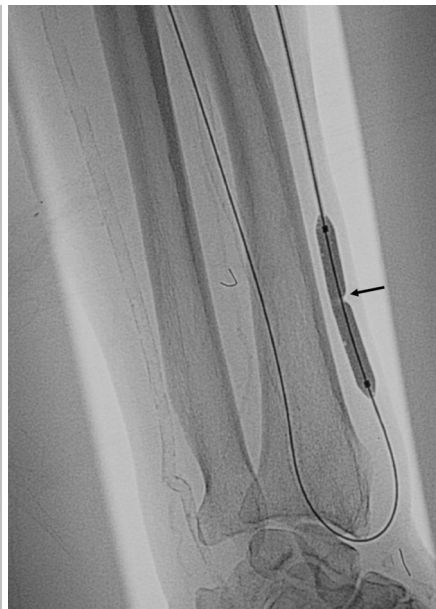8 mm

. 0.016

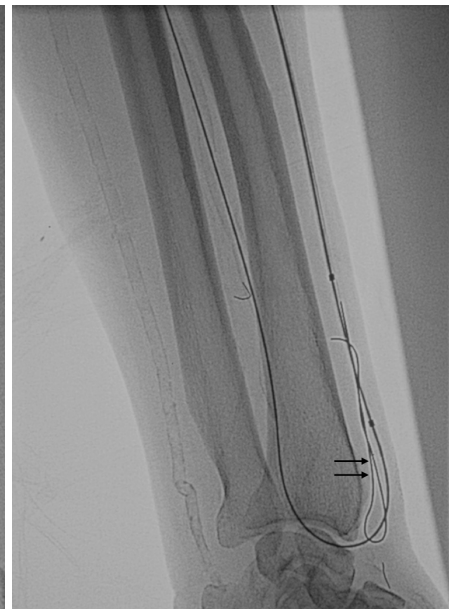8 mm



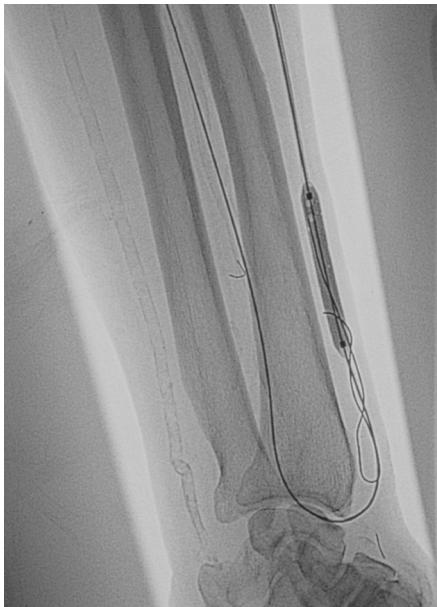A



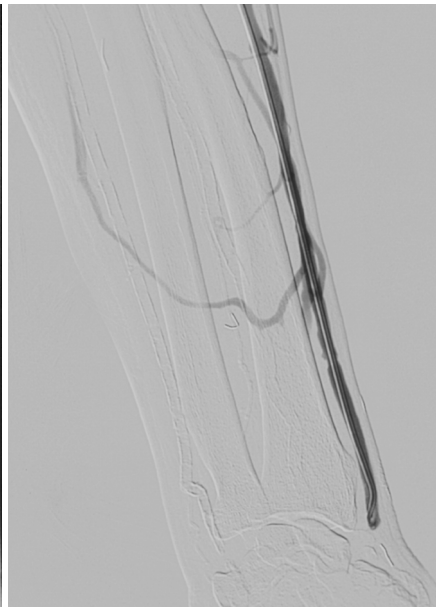B



C



D



E

Fig. 1. Left forearm hemodialysis fistula dysfunction in 59 years old patient.

A. Angiogram before PTA shows multifocal stenoses (arrows) in venous limb of native AVF.

B. Balloon indentation by a rigid stricture (arrow) was not resolved by repeated PTA beyond the rated burst pressure (20 atm).

C. Additional 0.016 inch microguide wire (double arrows) was inserted to the parallel to the balloon catheter across the rigid stricture of venous limb.

D. Balloon indentation was resolved by the parallel balloon angioplasty technique within the rate of burst pressure.

E. Postprocedural angiogram shows no residual stenosis or flow disturbance.

가

가

(4).

(Fig. 3). 6

5

6

가

(2,

5). 1993 Yazdanfar (6)

Table 1

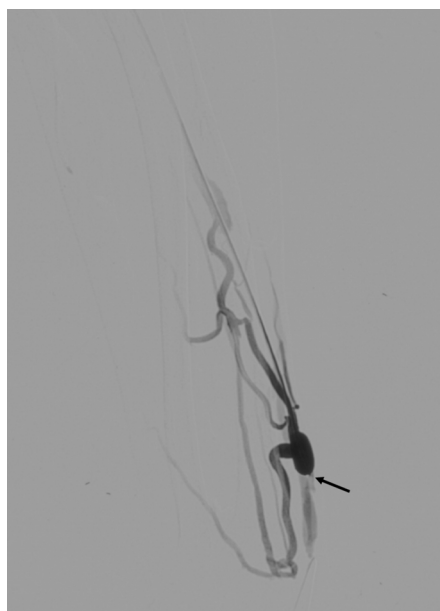
, 2000

Yamaya (7)

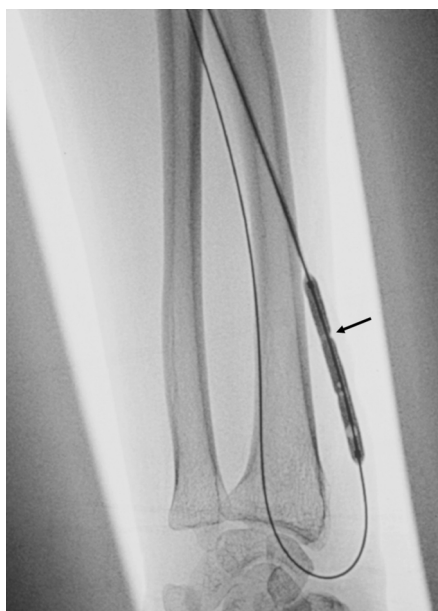가

3가

. Yamaya (7)



A



B

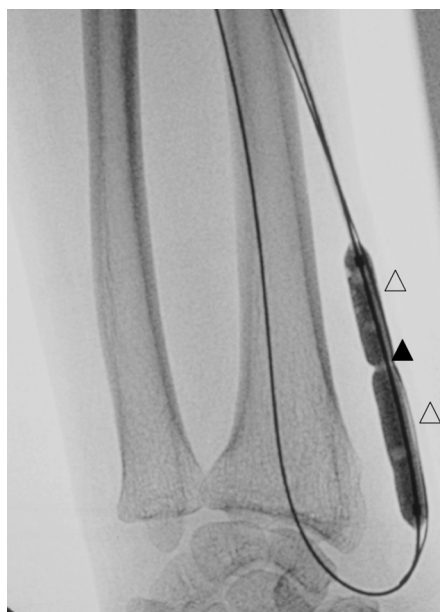
Fig. 2. Left radiocephalic fistula dysfunction in 31 years old patient.

A. Angiogram shows focal stenosis (arrow) at venous limb of AVF.

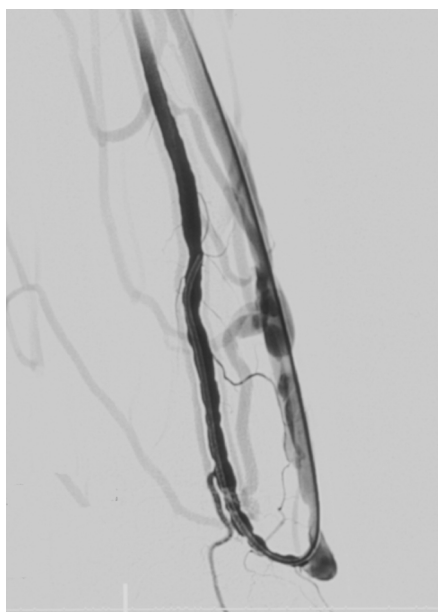
B. PTA with 5mm balloon catheter was performed but the waist (arrow) was not disappeared.

C. Microguide wire (blank arrow heads) was passed across the lesion but the balloon indentation (arrow head) was not lost, in spite of repeated balloon dilatation.

D. Final angiogram shows minimal residual stenosis but the flow was markedly improved.



C



D

:

Table 1. Summaries of Patients and Results of Parallel Wire Balloon Angioplasty Technique

No	Age/Sex	Type of Access	Lesion Site Severity	Technical / Clinical Success
1	M/59	Radio-cephalic fistula	Venous limb Stenosis	Yes / Yes
2	F/62	Radio-cephalic fistula	Venous limb Occlusion	Yes / Yes
3	F/61	Radio-cephalic fistula	Venous limb Occlusion	Yes / Yes
4	M/67	Radio-cephalic fistula	Venous limb Stenosis	Yes / Yes
5	F/75	Brachio-axillary graft	Axillary vein Occlusion	Yes / Yes
6	F/31	Radio-cephalic fistula	Venous limb Stenosis	No / Yes

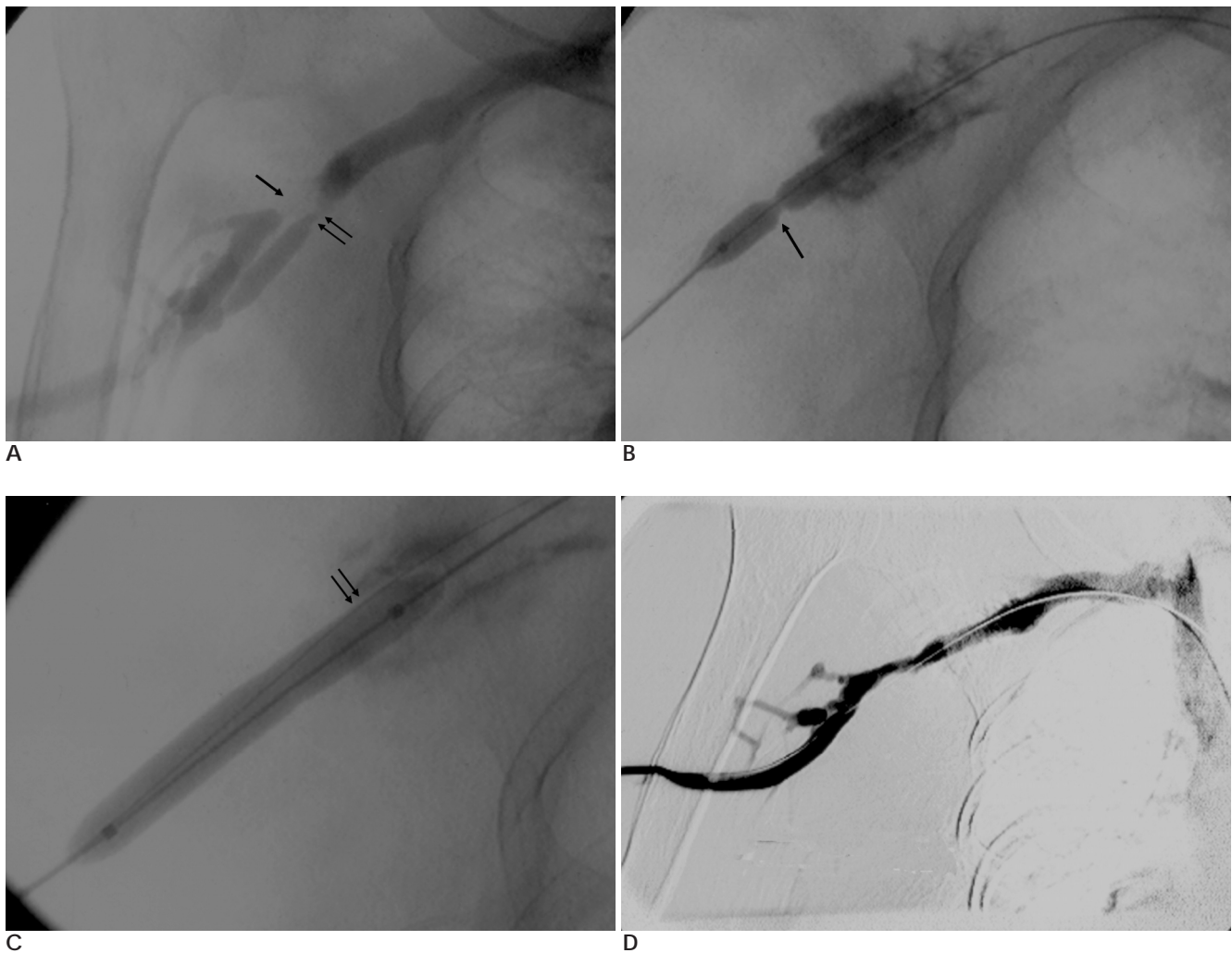


Fig. 3. Right brachioaxillary graft dysfunction in 75 years old patient.

A. Angiogram shows focal occlusion (arrow) and stenosis (double arrows) at distal portion of venous anastomosis.

B. PTA with 7 mm balloon catheter was performed, but balloon indentation (arrow) was not resolved.

C. Additional 0.016 inch microguide wire (double arrows) was inserted and PTA was performed. Balloon indentation was lost.

D. Final angiogram shows mild residual stenosis but the rapid flow is reestablished.

2 ,

가

(8).

Fukasawa (9)

U -

가

(cutting balloon)

3 - 4

(10),

(11, 12).

가 8 mm

가 . Trerotola (13)

30

(Atherectomy device)

가 (11).

1. McCarley P, Wingard RL, Shyr Y, Pettus W, Hakim RM, Ikizler TA. Vascular access blood flow monitoring reduces access morbidity and costs. *Kidney Int* 2001;60:1164-1172
2. NKF-DOQI clinical practice guidelines for vascular access. National Kidney Foundation-Dialysis outcomes and Quality Initiative. *Am J Kidney Dis* 1997;30(suppl 3):S150-S191
3. Bittl JA, Feldman RL. Cutting balloon angioplasty for undilatable venous stenoses causing dialysis graft failure. *Catheter Cardiovasc Interv* 2003;58:524-526
4. National Kidney Foundation. III. NKF-K/DOQI Clinical Practice Guide-lines for Vascular Access: update 2000. *Am J Kidney Dis* 2001;37(Suppl 1):S163-168
5. Glanz S, Gordon DH, Butt KM, Hong J, Lipkowitz GS. The role of percutaneous angioplasty in the management of chronic hemodialysis fistulas. *Ann Surg* 1987;206:777-781
6. Yazdanfar S, Ledley GS, Alfieri A, Strauss C, Kotler MN. Parallel angioplasty dilatation catheter and guide wire: a new technique for the dilatation of calcified coronary arteries. *Cathet Cardiovasc Diagn* 1993;28:72-75
7. Yamaya H, Horita Y, Nakazawa T, Taguchi T, Saitoh Y, Ichikawa I. Effectiveness of the parallel wire technique for stenotic hemodialysis fistula. *J Jpn Soc Dial Ther* 2000;33:127-131
8. Kamikou T, Tsunoda T, Ikeda Y, Manjou T, Harada T. The efficacy of parallel wire technique for the dilatation of stenotic hemodialysis fistula. *Kidney Dialysis Access* 2000;49:116-120
9. Fukasawa M, Matsushita K, Araki I, Tanabe N, Takeda M. Self-reversed parallel wire balloon technique for dilating unyielding strictures in native dialysis fistula. *J Vasc Interv Radiol* 2002;13:943-945
10. Sreenarasimhaiah VP, Margassery SK, Martin KJ, Bander SJ. Cutting balloon angioplasty for resistant venous anastomotic stenoses. *Semin Dial* 2004;17:523-527
11. Lee MS, Singh V, Nero TJ, Wilentz JR. Cutting balloon angioplasty. *J Invasive Cardiol* 2002;14:552-556
12. Singer-Jordan J, Papura S. Cutting balloon angioplasty for primary treatment of hemodialysis fistula venous stenoses: preliminary results. *J Vasc Interv Radiol* 2005;16:25-29
13. Trerotola SO, Stavropoulos SW, Shlansky-Goldberg R, Tuite CM, Kobrin S, Rudnick MR. Hemodialysis-related venous stenosis: treatment with ultrahigh-pressure angioplasty balloons. *Radiology* 2004;231:259-262

Parallel Wire Balloon Angioplasty for Undilatable Venous Stenosis in Hemodialysis Fistula¹

Tae-Beom Shin, M.D., Jin-Jong You, M.D., Jae-Min Cho, M.D., Dae-Seob Choi, M.D.,
Jae-Wook Ryoo, M.D., Kyung-Nyeo Jeon, M.D., Jae-Beom Na, M.D., Kyung-Soo Bae, M.D.,
Un-Suk Go, M.D., Sung-Hoon Chung, M.D. Jin-Soo Choi, M.D.², Yong-Joo Kim, M.D.³

¹Department of Diagnostic Radiology, Gyeongsang National University Hospital

²Department of Diagnostic Radiology, Kemyeong University Hospital

³Department of Radiology, Andong Hospital

Purpose: The purpose of this study was to assess the value of the parallel wire balloon angioplasty technique for treating dysfunctional hemodialysis fistula with rigid stenosis, and this type of lesion was resistant to conventional angioplasty.

Materials and Methods: Between March 2002 and August 2003, we included 6 patients (mean age: 59, males: 2, females: 4) who were treated via parallel the wire balloon angioplasty technique and their hemodialysis fistula has stenoses that were resistant to conventional angioplasty. We performed conventional angioplasty in all patients, but we failed to achieve sufficient dilatation. In the cases of highly resistant stenosis, an additional 0.016 inch wire was inserted into the 7 F vascular sheath. During angioplasty, a 0.016 inch guide wire was inserted between the balloon and the stenosis and then it was pushed to and fro until the balloon indentation disappeared. After the procedure, we performed angiography to identify the residual stenosis and the procedure-related complications.

Results: The undilatable stenoses in 5 patients were successfully resolved without complications via the parallel wire angioplasty technique. In one patient, indentation of balloon was not resolved, but the residual stenosis was both minimal and hemodynamically insignificant.

Conclusion: The parallel wire angioplasty technique seems to be a feasible and cost-effective method for treating a dysfunctional hemodialysis fistula with undilatable and rigid stenosis.

Index words : Dialysis

Arteries, transluminal angioplasty

Address reprint requests to : Tae Beom Shin, M.D., Department of Diagnostic Radiology, Gyeongsang National University Hospital,
90 Chilam-dong, Jinju 660-702, South Korea
Tel. 82-55-750-8216 Fax. 82-55-758-1568 E-mail: tbshinkr@yahoo.co.kr