

Diffuse Micronodular Pattern of Bronchiolitis Obliterans Organizing Pneumonia: A Case Report¹

In Jae Lee, M.D., Seung Hun Jang, M.D.², Kwang Seon Min, M.D.³,
Im Kyung Whang, M.D., Yul Lee, M.D., Sang Hoon Bae, M.D.

The typical radiographic findings of bronchiolitis obliterans organizing pneumonia (BOOP) are known to be patchy air-space consolidation that is often subpleural, and with or without ground-glass opacities. However, there are scant radiologic reports about the micronodular pattern of BOOP. We report here on a case of BOOP that manifested as diffusely scattered ill-defined centrilobular micronodules on HRCT.

Index words : Bronchiolitis obliterans organizing pneumonia
Computed tomography (CT), high-resolution

Bronchiolitis obliterans organizing pneumonia (BOOP) is pathologically characterized by the presence of granulation tissue within the lumens of the bronchioles and alveolar ducts, and by the presence of associated patchy areas of organizing pneumonia (1 - 3). Most cases are idiopathic. The typical imaging features of this syndrome have been widely documented and they consist of patchy air-space consolidation that is often subpleural, and with or without ground-glass opacities (1 - 7). To the best of our knowledge, there are scant radiologic reports about the diffusely scattered micronodular pattern of BOOP (4). We report here on a case of BOOP that manifested as diffusely scattered ill-defined centrilobular micronodules on high resolution computed tomography (HRCT).

Case Report

A 34-year-old woman presented to the outpatient department with a 7-year history of cough. This symptom has been aggravated for two months. She complained of white sputum and mild dyspnea. However, she denied fever, chill, rhinorrhea, sneezing or chest pain. The patient had no history of smoking, allergy, connective tissue diseases or other cardiovascular diseases. On physical examination, there were mild rales at both basal lung areas. Blood examination revealed no significant abnormalities with the normal levels of RA factor, IgG, IgA and IgM antibodies. The result of pulmonary function test was a mildly restrictive pattern with 2.33L for the FVC, 2.05L for the FEV1 and an 88% FEV1/FVC ratio. The patient refused bronchoscopic examinations, so bronchoalveolar lavage was not done.

The initial chest radiograph showed diffusely scattered faint small nodules with poorly defined margins in both lungs (Fig. 1A). On high resolution CT (HRCT) with 1.5-mm collimation, we observed diffusely scattered, ill-defined centrilobular small nodules (Fig. 1B). There was relative sparing of both the basal lung areas and the peripheral lung areas. The nodules were relatively the same in size and they were less than five mm

¹Department of Radiology, Hallym University Sacred Heart Hospital, Hallym University College of Medicine

²Department of Internal Medicine, Hallym University Sacred Heart Hospital, Hallym University College of Medicine

³Department of Pathology, Hallym University Sacred Heart Hospital, Hallym University College of Medicine

Received June 5, 2006 ; Accepted August 28, 2006

Address reprint requests to : In Jae Lee, M.D., Department of Radiology, Hallym University Sacred Heart Hospital, Hallym University College of Medicine, 896 Pyungchon-Dong, Dongan-Ku, Anyang-City, 431-070 Korea.

Tel. 82-31-380-3885 Fax. 82-31-380-3878

E-mail: ijlee2003@yahoo.co.kr

in diameter. Any significantly enlarged mediastinal lymph nodes or pleural effusion was not noted.

The patient underwent video assisted thoracic surgery for lung biopsy. On the surgical field, the surface of lung was diffusely nodular without pleural adhesion. The lung specimen showed centrilobular nodular lesions of organizing pneumonia (Fig. 1C). The nodular lesions were composed of variably dense airspace aggregates of loose fibroblasts in an immature collagen matrix with lymphocytes, plasma cells and histiocytes. The pathologic result was BOOP.

Treatment with corticosteroid was started. On the follow up CT three months later, the small nodules had decreased in size and number, but they were still there. The clinical symptoms also slowly improved.

Discussion

BOOP syndrome is characterized by an indolent onset of a flu-like illness accompanied with fever, non-productive cough, malaise, anorexia and weight loss. Dyspnea is common, but it is usually mild and it's evident only upon exertion (1, 4, 5, 8). In this case, the patient's symptoms were cough and mild dyspnea. This malady affects men and women equally and it occurs in middle-aged adults with a peak incidence in the sixth decade. No cause has been identified, although there is a suspicion that infection, viral or otherwise, may be the trigger in some cases; in particular, BOOP is not related to smoking. The mean duration of symptoms at presentation is variable, but in most cases it is less than three months (1, 4, 5, 8). In this case, the patient has been worked as officer, and there was no evident environ-

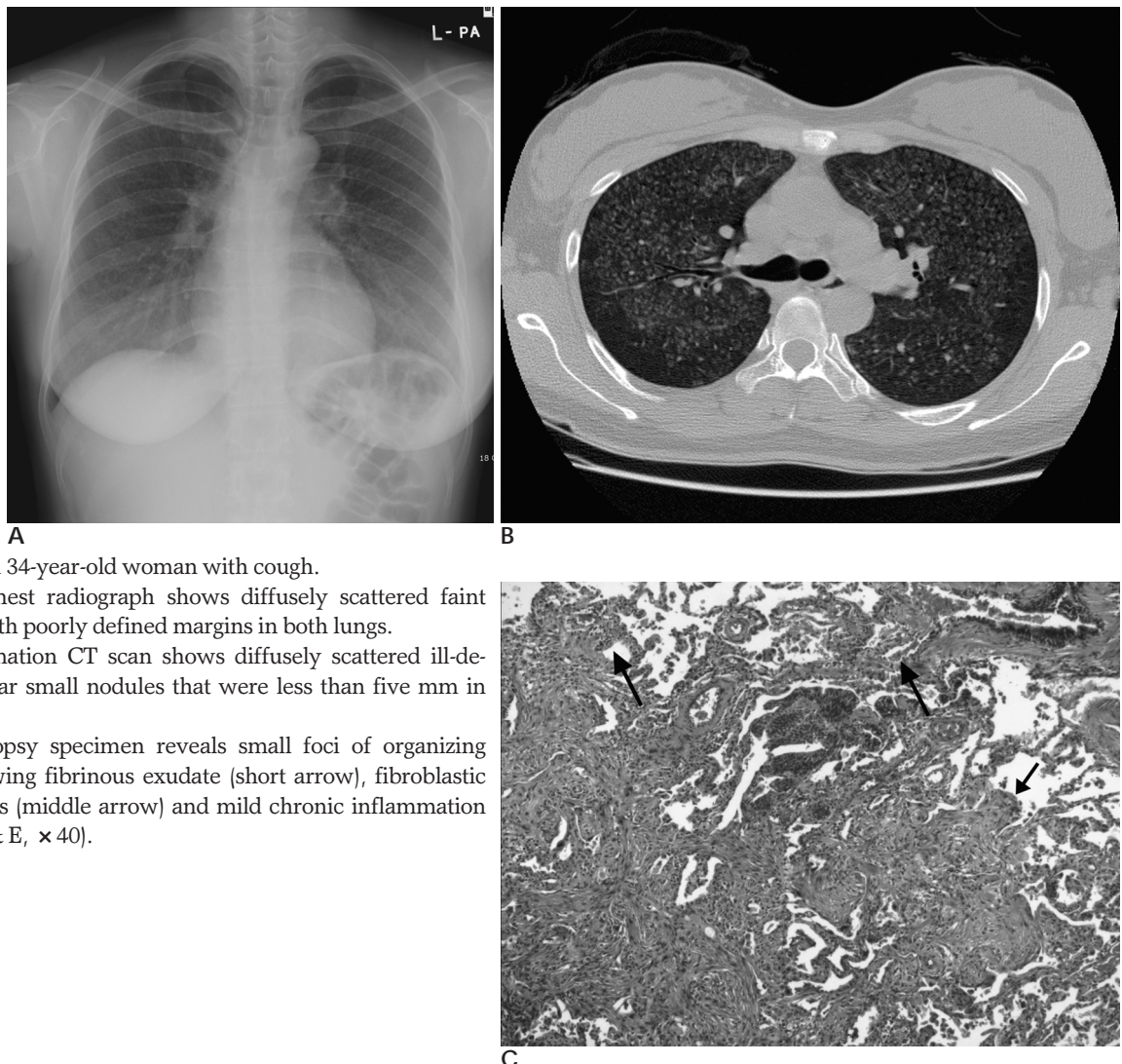


Fig. 1. BOOP in a 34-year-old woman with cough.
A. The initial chest radiograph shows diffusely scattered faint small nodules with poorly defined margins in both lungs.
B. 1.5-mm collimation CT scan shows diffusely scattered ill-defined centrilobular small nodules that were less than five mm in diameter.
C. The lung biopsy specimen reveals small foci of organizing pneumonia showing fibrinous exudate (short arrow), fibroblastic plugs in airspaces (middle arrow) and mild chronic inflammation (long arrow) (H & E, $\times 40$).

mental cause or history related to hypersensitivity pneumonitis.

The cardinal component of BOOP is the organizing pneumonia, and this is reflected by a restrictive, non-obstructive, functional deficit (4, 6, 7). To overcome this confusion, cryptogenic organizing pneumonia (COP) has been suggested as the preferred term for this clinico-pathological syndrome as it conveys the essential features of the entity (4 - 7). In this case, the results of the pulmonary function tests were a restrictive pattern.

The typical imaging features of this syndrome have been widely documented and they consist of patchy airspace consolidation that is often subpleural, with or without ground-glass opacities (1 - 4, 6, 7). However, in this case, the CT finding was diffusely scattered centrilobular micronodules (nodules < 4 mm) with poorly defined margins (4). This type of CT finding is more frequently encountered in the subacute stage of extrinsic allergic alveolitis (4). In a recent study, the presence of parenchymal nodules with ill-defined margins and a predominantly peripheral distribution were the most important discriminating CT features between organizing pneumonia and chronic eosinophilic pneumonia (4, 9). In a review article, Cordier has described a distinct bronchiolocentric distribution in which organizing pneumonia is limited to the alveoli immediately adjacent to the involved bronchioles, and so this giving a miliary pattern (4, 8). In this case, the lung specimen microscopically showed the centrilobular nodular lesions of organizing pneumonia. The nodular lesions were composed of variably dense airspace aggregates of loose fibroblasts in an immature collagen matrix with lymphocytes, plasma cells and histiocytes. This finding can be seen in cases of BOOP or hypersensitivity pneumonitis. However, there was no distinct microscopic evidence of hypersensitivity pneumonitis such as interstitial pneumonia with peribronchiolar accentuation, necrotizing granuloma or epithelioid histiocytes (10). So,

these findings supported the diagnosis of a centrilobular micronodular pattern of BOOP.

Response to corticosteroid treatment is prompt in most cases and relapse does not occur if sufficient therapy is given (4, 6). In this case the small nodules decreased in size with steroid treatment, but they persisted on follow up CT. The clinical symptoms also slowly improved.

In conclusion, the possibility of a micronodular pattern of BOOP might be considered in the cases that show diffusely scattered ill-defined centrilobular micronodules on CT.

References

1. Epler GR, Colby TV, McLoud TC, Carrington CB, Gaensler EA. Bronchiolitis obliterans organizing pneumonia. *N Engl J Med* 1985;312:152-158
2. Müller NL, Staples CA, Miller RR. Bronchiolitis obliterans organizing pneumonia: CT features in 14 patients. *AJR Am J Roentgenol* 1990;154:983-987
3. Gosink BB, Friedman PJ, Liebow AA. Bronchiolitis obliterans: roentgenographic-pathologic correlation. *AJR Am J Roentgenol* 1973;117:816-832
4. Oikonomou A, Hansell DM. Organizing pneumonia: the many morphological faces. *Eur Radiol* 2002;12:1486-1496
5. Hansell DM. What are bronchiolitis obliterans organizing pneumonia (BOOP) and cryptogenic organizing pneumonia (COP)? *Clin Radiol* 1992;45:369-370
6. Flowers JR, Clunie G, Burke M, Constant O. Bronchiolitis obliterans organizing pneumonia: the clinical and radiological features of seven cases and a review of the literature. *Clin Radiol* 1992;45:371-377
7. Lee KS, Kullnig P, Hartman TE, Müller NL. Cryptogenic organizing pneumonia: CT findings in 43 patients. *AJR Am J Roentgenol* 1994;162:543-546
8. Cordier JF. Organizing pneumonia. *Thorax* 2000;55:318-328
9. Arakawa H, Kurihara Y, Niimi H, Nakajima Y, Johkoh T, Nakamura H. Bronchiolitis obliterans organizing pneumonia versus Chronic eosinophilic pneumonia: high-resolution CT findings in 81 patients. *AJR Am J Roentgenol* 2001;176:1053-1058
10. Katzenstein AL. *Katzenstein and Askin's surgical pathology of non-neoplastic lung disease*. 3rd ed. Philadelphia: W. B. Saunders, 1997: 138-145

