

1

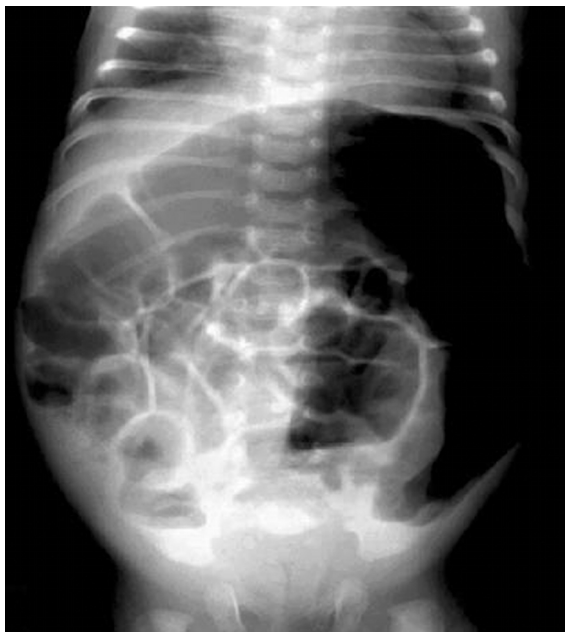.

:  
: 15  
가 ,  
-S  
가 , 24  
14 (93%) 가  
15 10 (67%)  
가 , 4 -S  
11 (3 , 7 , 1 )  
가  
-S , , 24

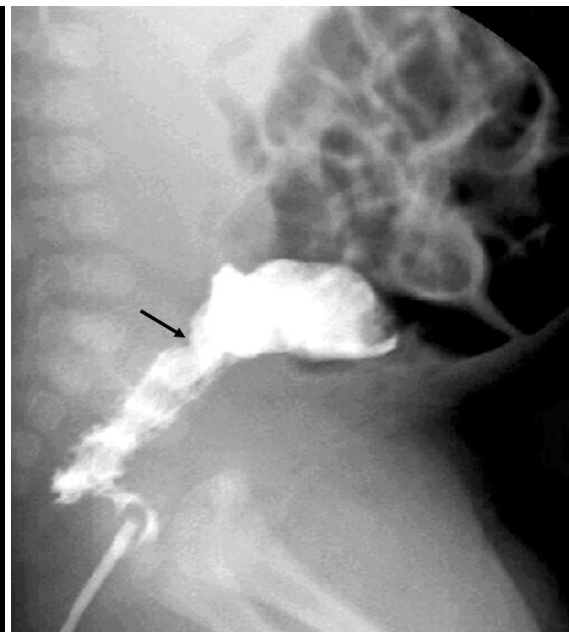(cow 's milk allergy) 2 - 3% 62 (barium enema)  
20% 15  
(1, 2).  
(1). 9 , 6 17 250  
74 . 8  
가 , 11 , 4  
(allergic colitis) (abdominal distension)  
가 가 12  
(necrotizing enterocolitis), 가 3 . 15  
(Hirschsprung 's disease), (infectious  
colitis) (3 - 7).  
1  
가 . 15  
13  
(barium reduction)  
(skin prick  
test) 5  
15  
2002 3 2005 6  
1 2006 1 8 2006 4 20  
가 (rectal gas)

(paralytic ileus),  
(mechanical obstruction)  
(spasm), -S  
(reversed rectosigmoid index)  
(mucosal irregularity), (transitional zone)  
가, 24 (barium  
retention)

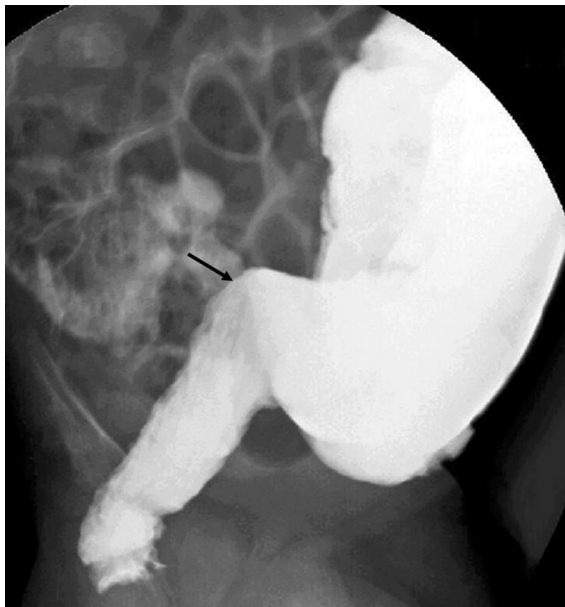
(Fig. 1),  
2  
가 9  
10 (Fig. 1-3) 가  
2 (Fig. 2),  
-S 4 (Fig. 1, 3), 1  
(Fig. 1). 24  
11, 3, 7  
, 1  
1  
(acetylcholine esterase  
activity)



A



B

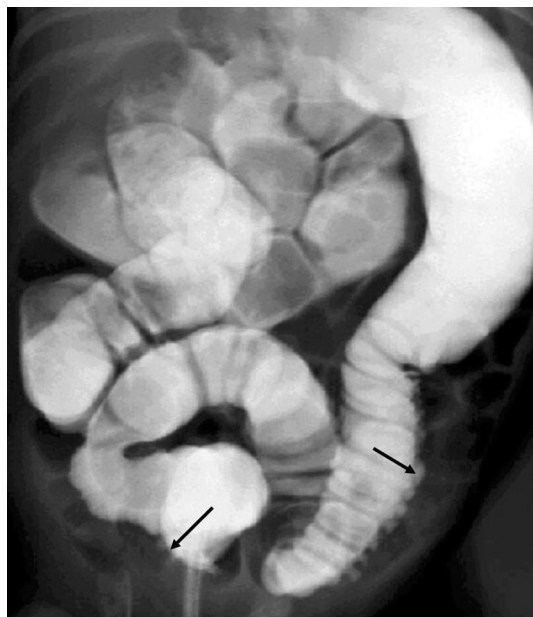


C

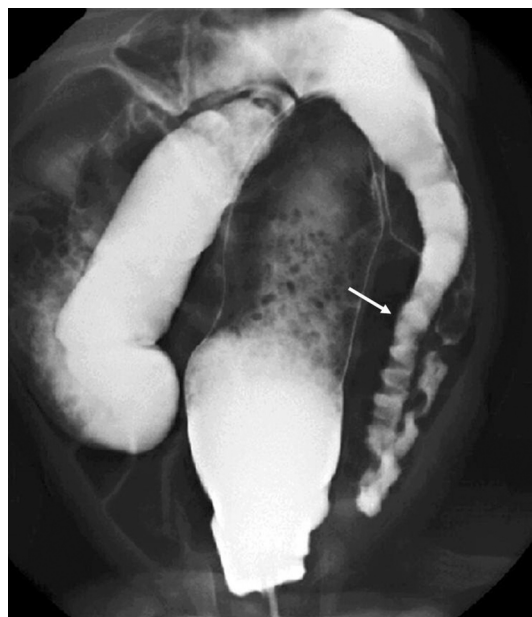
**Fig. 1.** A 47-day-old boy with chronic constipation and abdominal distension.

**A.** Erect view of the abdomen represents diffuse gaseous distension of the bowel with multiple air-fluid levels representing mechanical obstruction.

**B, C.** Lateral views of the barium enema reveal a transitional zone (arrows) in the distal sigmoid colon, reversed rectosigmoid index, and spasm of the rectum mimicking Hirschsprung's disease.



**Fig. 2.** A 17-day-old boy with abdominal distension. Frontal view of barium enema shows mucosal irregularity of the distal sigmoid and descending colon (arrows).



**Fig. 3.** A 44-day-old girl with constipation. Frontal view of the barium enema illustrates persistent spasm of the sigmoid and distal descending colon (arrow) with reversed rectosigmoid index. The spasm of those sites was first noted on the barium enema two weeks ago.

-S 4 ,  
(short segment) 가 ,  
가 .  
가  
2 - 3% (1). (8)  
32.2% 가 2 가  
(9) , McIlhenny (10)  
(local intestinal anaphylaxis)  
(5). 4 , 50 - 60%  
(1, 9). (80%)  
8 (20%)가 27 21  
(chronic idiopathic constipation) (78%) (11). Swischuk (3)  
-S , 가  
(6). (14).

IgE  
가, 가,  
가 가 , 가  
(1, 6, 10).  
가 60  
(12). 15  
, 1  
(10,  
(14 )  
13). 가 (9 ) 가  
, 가  
(14).

가 , S ,

, 24

2

(3, 5, 6, 13).

가

(aganglionic segment)

-S

. Bloom

(6)

-S

가

4

가

가

(4, 7). , 가

(gastroesophageal reflux)

(15).

가

(67%).

1. Host A. Frequency of cow 's milk allergy in childhood. *Ann Allergy Asthma Immunol* 2002;89(Suppl 1):33-37
2. Chong SK, Blackshaw AJ, Morson BC, Williams CB, Walker-Smith JA. Prospective study of colitis in infancy and early childhood. *J Pediatr Gastroenterol Nutr* 1986;5:352-358
3. Swischuk LE, Hayden CK Jr. Barium enema findings(segmental colitis) in four neonates with bloody diarrhea-possible cow 's milk allergy. *Pediatr Radiol* 1985;15:34-37
4. Kumar D, Repucci A, Wyatt-Ashmead J, Chelimsky G. Allergic colitis presenting in the first day of life: report of three cases. *J Pediatr Gastroenterol Nutr* 2000;31:195-197
5. Patenaude Y, Bernard C, Schreiber R, Sinsky AB. Cow 's-milk-induced allergic colitis in an exclusively breast-fed infant: diagnosed with ultrasound. *Pediatr Radiol* 2000;30:379-382
6. Bloom DA, Buonomo C, Fishman SJ, Furuta G, Nurko S. Allergic colitis: a mimic of Hirschsprung disease. *Pediatr Radiol* 1999;29:37-41
7. Fell JM. Neonatal inflammatory intestinal disease: necrotising enterocolitis and allergic colitis. *Early Hum Dev* 2005;81:117-122
8. . *Korean J Pediatr* 2004;47: 604-610
9. 1993;36:1383-1388
10. Mcilhenny J, Sutphen JL, Block CA. Food allergy presenting as obstruction in an Infant. *AJR Am J Roentgenol* 1988;150:373-375
11. Iacono G, Carroccio A, Cavataio F, Montalto G, Cantarero MD, Notarbartolo A. Chronic constipation as a symptom of cow milk allergy. *J Pediatr* 1995;126:34-39
12. Odze RD, Wershil BK, Leichtner AM, Antonioli DA. Allergic colitis in infants. *J Pediatr* 1995;126:163-170
13. Masumoto K, Takahashi Y, Nakatsuji T, Arima T, Kukita J. Radiologic findings in two patients with cow 's milk allergic enterocolitis. *Asian J Surg* 2004;27:238-40
14. Richards DG, Somers S, Issenman RM, Stevenson GW. Cow 's milk protein/soy protein allergy: gastrointestinal imaging. *Radiology* 1998;167:721-723
15. Ravelli AM, Tobanelli P, Volpi S, Ugazio AG. Vomiting and gastric motility in infants with cow 's milk allergy. *J Pediatr Gastroenterol Nutr* 2001;32:59-64

## Barium Enema Findings of Milk Allergy in Infants<sup>1</sup>

Gyoung Ju Kim, M.D., Mi Jeong Kim, M.D., Hee Jung Lee, M.D.

<sup>1</sup>*Department of Diagnostic Radiology, Keimyung University School of Medicine*

**Purpose:** We wanted to evaluate the barium enema findings of milk allergy in infants.

**Materials and Methods:** Retrospective evaluation of the plain abdominal radiography and barium enema findings was performed in fifteen young infants suffering with milk allergy. The presence of gaseous distension, rectal gas, paralytic ileus and mechanical obstruction was evaluated on the plain radiography. The presence of spasm, a transitional zone, a reversed rectosigmoid index and mucosal irregularity was analyzed on the barium enema; the presence of barium retention was also evaluated on 24-hour-delayed plain radiography.

**Results:** Paralytic ileus was the most common finding on the plain radiography (93%). On the barium enema, continuous spasm of the colon, ranging from the rectum to the descending colon, was revealed in ten infants (67%). A transitional zone was observed in one infant and a reversed rectosigmoid index was revealed in four. Mucosal irregularity was observed in two infants. Barium retention was demonstrated in 11 of fifteen cases: throughout the entire colon ( $n = 3$ ), from the rectum to the descending colon ( $n = 7$ ), and up to the transverse colon ( $n = 1$ ).

**Conclusion:** The most common barium enema finding of milk allergy in infants was spasm of the distal colon. The other findings were a transitional zone, a reversed rectosigmoid index, mucosal irregularity and barium retention.

**Index words :** Anaphylaxis and allergy  
Barium enema examination  
Infants, gastrointestinal tract  
Colitis  
Milk

Address reprint requests to : Hee Jung Lee, M.D., Department of Diagnostic Radiology, Dongsan Medical Center,  
Keimyung University College of Medicine, 194 Dongsan-dong, Jung-gu, Taegu 700-712, Korea.  
Tel. 82-53-250-7770 Fax. 82-53-250-7766 E-mail: hjlee@dsmc.or.kr