

Pharyngoesophageal (Killian-Jamieson) Diverticulum Mimicking Thyroid Nodule on Ultrasonography: A Case Report¹

Ki Hong Kim, M.D., Eun Ju Son, M.D., Eun-kyung Kim, M.D.,
Jin Young Kwak, M.D., Ki Keun Oh, M.D.

Pharyngoesophageal or Killian-Jamieson diverticulum is due to herniation of the mucosa and submucosa of the pharynx through a potentially weak area of the pharyngeal wall. It originates on the anterolateral wall just below the cricopharyngeus. It can be detected incidentally during thyroid ultrasonography (US). We present here a case report of pharyngoesophageal (Killian-Jamieson) diverticulum mimicking a thyroid nodule on US. We discuss the image findings that might be useful for the differential diagnosis and to prevent invasive procedures such as needle aspiration biopsy.

Index words : Esophagus, diverticula
Ultrasound (US)
Thyroid

Pharyngoesophageal or Killian-Jamieson diverticulum is the rare diverticulum of the esophagus (1). It is usually found incidentally when performing esophagography.

However, it can also be incidentally detected by thyroid ultrasonography. We report here on a case of the pharyngoesophageal diverticulum that was misdiagnosed as a suspicious thyroid nodule on the ultrasonography that was done outside of our hospital. We diagnosed Killian-Jamieson diverticulum with real-time ultrasonography (US) and using this modality can help avoid unnecessary needle aspiration biopsy (NAB).

Case Report

A 41-year-old man was transferred to our institute for

NAB of a thyroid nodule, which was found on US that was done outside our hospital. He had no symptoms. The US images showed a low-echoic 6 mm sized left thyroid nodule with a longer than wide shape. The other hospital's report was suspicious for nodule of the left thyroid and they recommended NAB. Before US guided fine needle aspiration biopsy (FNAB) of the left thyroid nodule, we performed pre-biopsy US.

The ultrasonography of the thyroid gland was performed using a real-time linear array unit with a 10 - 12 MHz transducer and a HDI 5000 machine (Advanced Technology Laboratories, Bothell, WA). The ultrasonography demonstrated a 5.6 × 5.5 mm sized low echoic nodule in the posterior medial aspect of the left thyroid gland. The nodule showed a longer than wide shape (Fig. 1A). When attempting to perform FNAB, the patient swallowed simultaneously to show incidental peristaltic contraction of the left thyroid hypoechoic nodule, and the longitudinal ultrasonographic scanning showed a connection to the proximal cervical esophagus; this suggested esophageal diverticulum (Fig. 1B).

The remaining tissue of the thyroid was of normal-

¹Department of Diagnostic Radiology The Research Institute of Radiological Science Yonsei University College of Medicine
Received July 12, 2006 ; Accepted September 21, 2006
Address reprint requests to : Eun Ju Son, M.D., Department of Radiology, Yonsei University, College of Medicine, Yong Dong Severance Hospital, 146-92 Dokok-dong, Kangnam-gu, Seoul 135-270, South Korea
Tel. 82-2-2019-3510 Fax. 82-2-3462-5472
E-mail: ejsonrd@yumc.yonsei.ac.kr

sized and echo-texture. No pathologic lymphadenopathy was noted along either of the internal jugular chains. So, we did not perform US guided FNAB for the left thyroid nodule and we recommended a barium swallow examination for confirmation. The esophagography showed a small sized barium outpouching just at the left lateral side above the upper esophageal sphincter; this suggested Killian-Jamieson diverticulum of the esophagus (Fig. 1C).

Discussion

Pharyngoesophageal or Killian-Jamieson diverticulum is due to herniation of the mucosa and submucosa of the pharynx through a potentially weak area of the pharyngeal wall just below the cricopharyngeus. Another similar pharyngoesophageal lesion, Zenker's diverticulum, is due to herniation through Killian's dehiscence (2). The

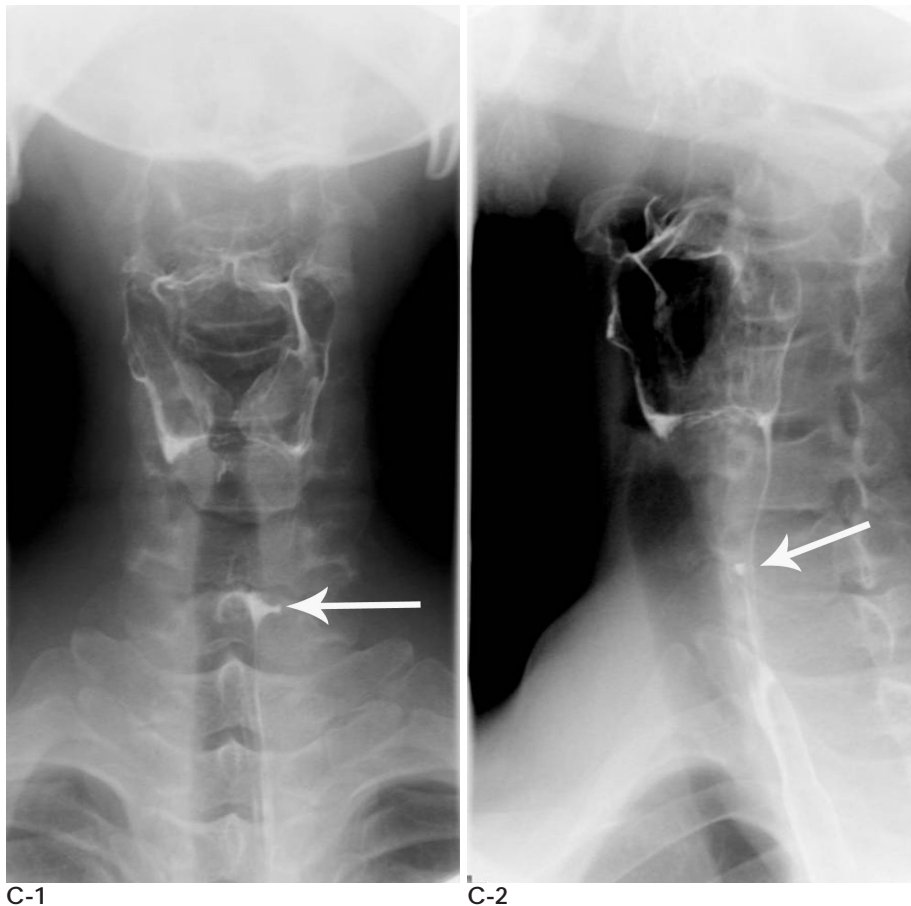
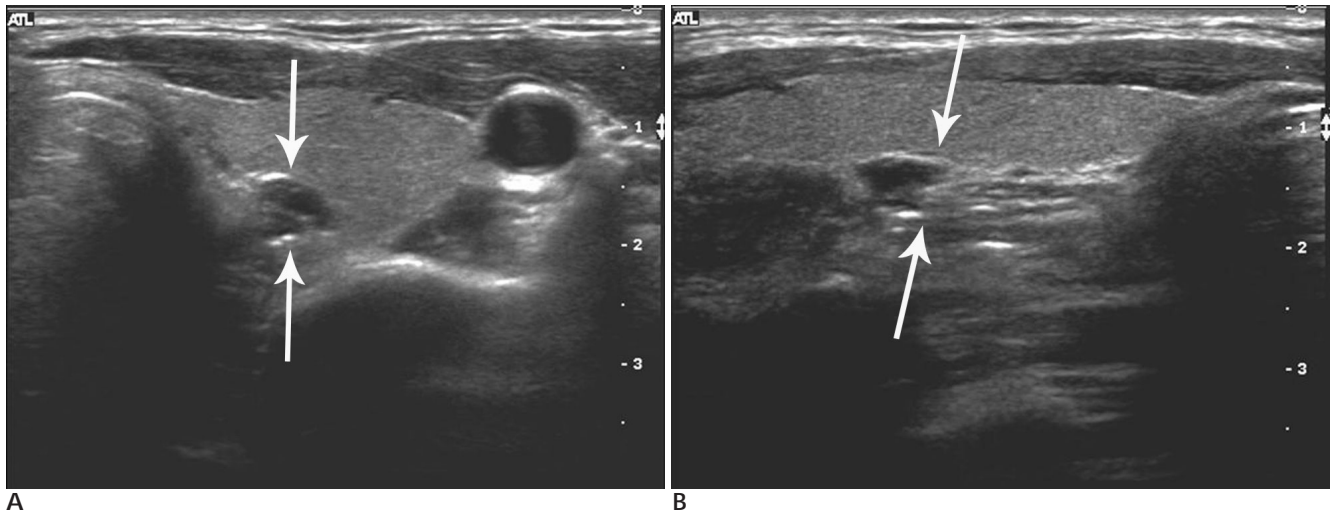


Fig. 1. A 41-year-old man with an incidentally found hypoechoic nodule at the left thyroid during ultrasonography (US).

A. On the US before the fine needle aspiration biopsy (FNAB) of left thyroid gland, there was a 5.3 mm sized well-defined low echoic nodule on the posteromedial aspect. There were band-like echogenic lines on the anterior and posterior portions of the hypoechoic nodule (white arrows).

B. The longitudinal scan showed connection between the left thyroid nodule and the proximal cervical esophagus (white arrows). We can also see the peristaltic movement of the nodule during incidental swallowing.

C. On barium swallow examinations, we noted a small, pit-like outpouching of the left proximal esophagus in the lateral direction (white arrow) and we confirm it as pharyngoesophageal diverticulum (Killian-Jamieson).

thyropharyngeous and cricopharyngeous make up the inferior constrictor muscle of the pharynx and esophagus. Zenker's diverticulum is thought to represent a pulsion diverticulum, which may occur as a result of spasms of the cricopharyngeous or pharyngeal muscle incoordination (3). The diverticulum initially protrudes posteriorly; however, as it enlarges, its backward extension is prevented by the prevertebral fascia, and it then projects to one side, usually the left side (3). The major differential diagnosis points between Killian-Jamieson and Zenker's diverticulum are the typical location with considering the cricopharyngeous and the projecting directions. Killian-Jamieson diverticulum originates on the anterolateral wall just below the cricopharyngeous. Zenker's diverticulum originates on the posterior wall of the pharyngoesophageal segment in a mid line area of weakness just above the cricopharyngeous (1). So, the importance of the lateral image of barium contrast is to make the differential diagnosis between these lesions.

Because of the proximity of the upper esophagus to the thyroid gland, esophageal abnormality can mimic thyroid disease on ultrasonography.

The sonographic appearance of a pharyngeal pouch has been previously reported on (4 - 7). The principle sonographic features are a mass with a hypoechoic wall or internal or peripheral echogenic foci and a boundary hypoechoic zone at the posterior portion of the thyroid gland.

In our case, the pharyngoesophageal diverticulum was initially misdiagnosed as a suspicious thyroid nodule on another hospital's US; the patient was then transferred to our hospital for US-guided FNAB. Real time

US can show the peristaltic movement of the diverticulum. An additional longitudinal scan revealed the connection to the esophageal wall by the diverticulum.

The diagnosis of pharyngoesophageal diverticulum could be confirmed by employing a barium swallow study, which would demonstrate a protruding pouch filled with barium.

When a hypoechoic nodule with surrounding peripheral echogenic foci on the posterolateral aspect of the left thyroid is found during neck ultrasonography, we should not exclude the possibility of a pharyngoesophageal diverticulum that mimics thyroid nodules. We can diagnose esophageal diverticulum by observing the change of shape when the patient swallows. The additional longitudinal scan is also useful to confirm the diverticulum.

References

1. Mercer D, Blachar A, Khafif A, Weiss J, Kessler A. Real-time Sonography of Killian-Jamieson Diverticulum and its differentiation from thyroid nodules. *J Ultrasound Med* 2005;24:557-560
2. McMinn RMH, *Last's anatomy-regional and applied*. 8th ed Edinburgh: Churchill Livingstone ; 1990. p 487-488
3. Ellis H. *Clinical anatomy. A revision and applied anatomy for clinical students*. 7th ed. Oxford: Blackwell Scientific, 1983:303-304
4. Biggi E, Derchi LE, Cicio GR, Neumaier CE. Sonographic findings of Zenker's diverticulum. *J Clin Ultrasound* 1982;10:395
5. Hayshi N, Tamaki N, Konishi J, Endo K, Misaki T, Torizuka K, et al. Lateral pharyngoesophageal diverticulum simulating thyroid adenoma on sonography. *J Clin Ultrasound* 1984;12:592
6. DeFriend DE, Dubbins PA. Sonographic demonstration of a pharyngoesophageal diverticulum. *J Clin Ultrasound* 2000;28:485-487
7. Kwak JY, Kim EK. Sonographic findings of Zenker Diverticula. *J Ultrasound Med* 2006;25:639-642

2006;55:447 - 449

Killian - Jamieson :

1

1

Killian - Jamieson

41

Killian - Jamieson