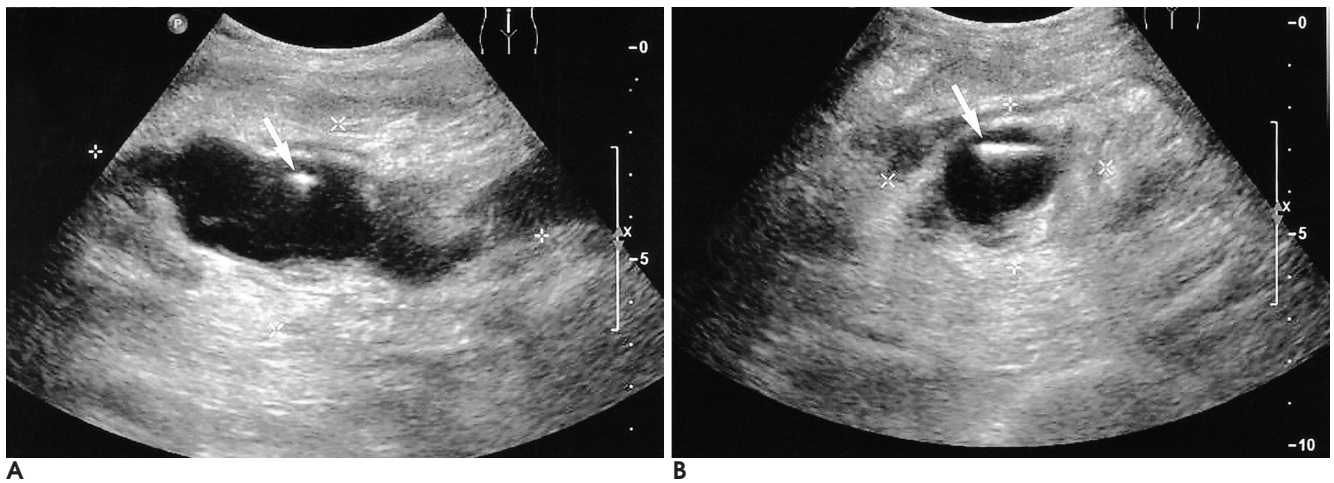
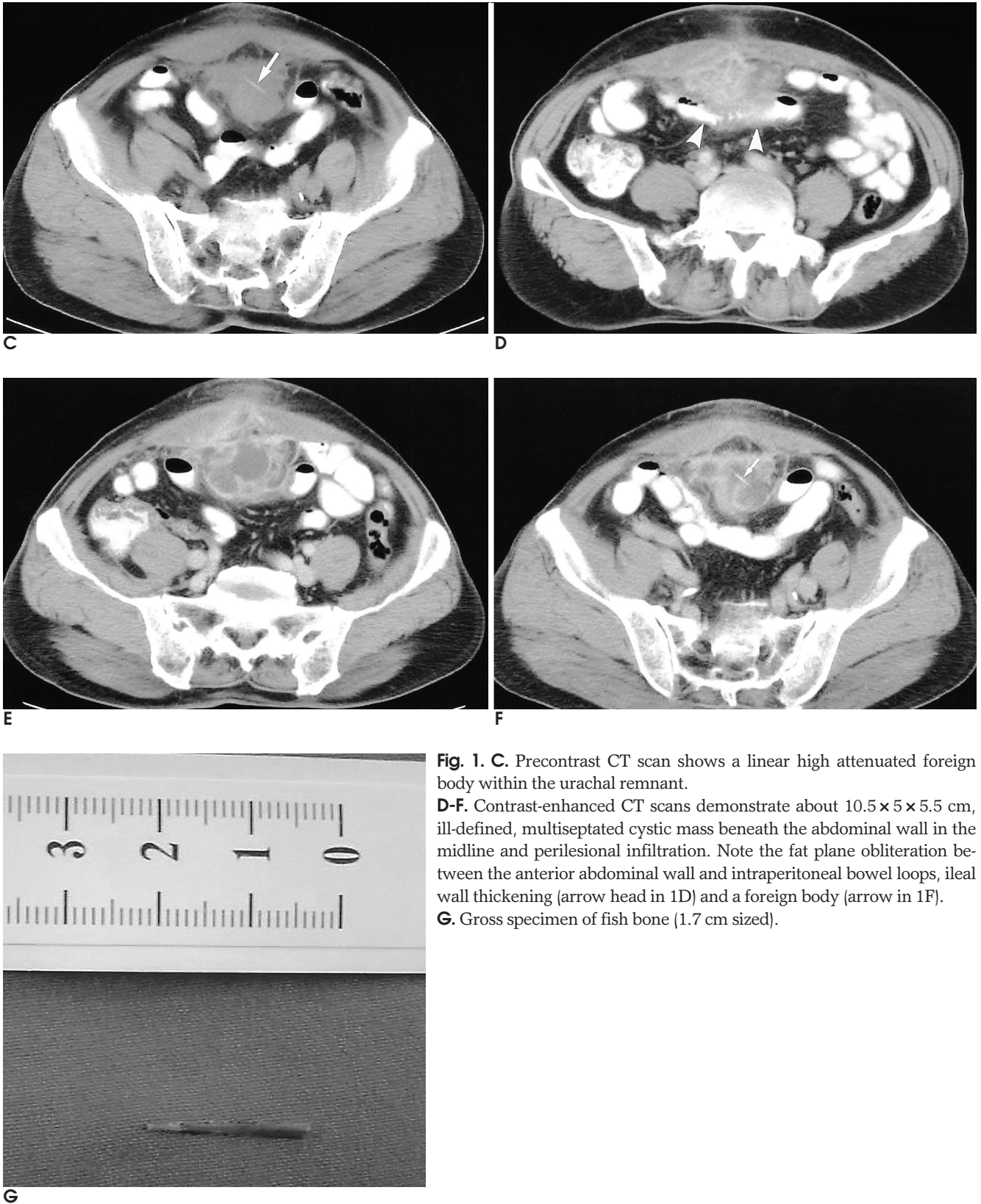


3 . 68  
(fistula)  
1 .  
50% 가 ,  
30%, 15%, 5% - - (KUB)  
(1), 3% , 가 10.6×5.1×5.3 cm  
(2).  
1.7 cm 가  
(Fig. 1A and 1B).  
4 (computed tomography,  
가 (3, 4). CT )  
가 (Fig. 1C). CT  
68  
1  
1F). 가 (Fig. 1D -  
(voiding cystourethro - graphy)  
1 가 63  
가 2 cm  
(Fig. 1G),  
가  
Penrose  
(14,720 × 10<sup>3</sup>/mm<sup>3</sup>)



**Fig. 1. A, B.** Longitudinal (Fig. 1A) and transverse (Fig. 1B) US image shows a linear echogenic foreign body (arrow) within complex cystic lesion lying along the midline course of the urachus between the bladder and the umbilicus. The lesion demonstrates a thick outer wall with marked inflammatory change.



**Fig. 1. C.** Precontrast CT scan shows a linear high attenuated foreign body within the urachal remnant.

**D-F.** Contrast-enhanced CT scans demonstrate about 10.5 × 5 × 5.5 cm, ill-defined, multiseptated cystic mass beneath the abdominal wall in the midline and perilesional infiltration. Note the fat plane obliteration between the anterior abdominal wall and intraperitoneal bowel loops, ileal wall thickening (arrow head in 1D) and a foreign body (arrow in 1F).

**G.** Gross specimen of fish bone (1.7 cm sized).

CT

가

1. Congenital anomalies of the urachus and bladder. In Pollack HM. *Clinical urography: an atlas and textbook of urological imaging*. Philadelphia: Saunders, 1990;711
2. Schubert GE, Pavkovic MB, Bethke-Bedurftig BA. Tubular urachal remnants in adult bladders. *J Urol* 1982;127:40-42
3. Goldman IL, Caldamone AA, Gauderer M, Hampel N, Wesselhoeft CW, Elder JS. Infected urachal cysts: a review of 10

- cases. *J Urol* 1988;140:375-378
4. Patrick CW, Ruben FG, Alan DP, Thomas AS. *Campbell's urology*. 5th ed. Philadelphia: Saunders, 1986:1915-1918
  5. DiSantis DJ, Siegel MJ, Katz ME. Simplified approach to umbilical remnant abnormalities. *Radiographics* 1991;11:59-66
  6. Yu JS, Kim KW, Lee HJ, Lee YJ, Yoon CS, Kim MJ. Urachal remnant diseases: spectrum of CT and US findings. *Radiographics* 2001;21:451-461
  7. Spataro RF, Davis RS, McLachlan MS, Linke CA, Barbaric ZL. Urachal abnormalities in the adult. *Radiology* 1983;149:659-663
  8. MacMillian RW, Schullinger JN, Santulli TV. Pyourachus: an unusual surgical problem. *J Pediatr Surg* 1973;8:387-389
  9. *Urachal carcinoma*. In Dahnert W. *Radiology review manual 3rd ed*. Baltimore: Williams & Wilkins, 1996:706-707
  10. Korobkin M, Cambier L, Drake J. Computed tomography of urachal carcinoma. *J Comput Assist Tomogr* 1988;12:981-987

J Korean Radiol Soc 2006;54:297 - 300

## Fish-bone Associated Infected Urachal Cyst: A Case Report<sup>1</sup>

Chae Hoon Kang, M.D., You Me Kim, M.D.

<sup>1</sup>Department of Radiology, Dankook University Hospital

Congenital urachal abnormalities are more common in children, but urachal cyst is more frequently seen in adults. Infection within a cyst produces significant symptoms, which may explain the fact that three times as many infected cysts as uninfected urachal cysts are detected in adults. We report here on a case of infected urachal cyst with a fish bone and also the fistular formation between the ileum and urachus in a 63-year-old male with a history of urinary frequency and a tender mass at the lower abdominal quadrant.

**Index words :** Urachus

Computed tomography (CT)

Ultrasound (US)

Cyst

Fistula

Address reprint requests to : You Me Kim, M.D., Department of Radiology, Dankook University Hospital  
29 Anseodong, Cheonan, Choongnam, 330-715 Korea.  
Tel. 82-41-550-6921 Fax. 82-41-552-9674 E-mail: sirenos@naver.com