

Radiological Evaluation of Percutaneous Endoscopic Lumbar Discectomy: A Three-Year Follow-Up Study¹

Seung-Eun Chung, M.D., Sang-Ho Lee, M.D., Ph.D.², Tae-Hong Kim, M.D.³, Yong Ahn, M.D.², Song-Woo Shin, Ph.D.², Byung-June Jo, M.D., Jee-Young Park, M.D.

Purpose: We wanted to analyze the radiological changes of the patients who underwent percutaneous endoscopic lumbar discectomy (PELD) for treating soft disc herniation.

Materials and Methods: We retrospectively reviewed 30 patients (32 cases) who were observed for a minimum of 3 years after they underwent PELD. The authors investigated the postoperative radiological changes after PELD and the related clinical outcomes. All the patients received plain X-rays, CT and MRI both preoperatively and at the final follow-up. The radiological parameters were evaluated, including the disc height, the disc signal intensity, the subchondral marrow signal intensity, the sagittal plane instability and the facet joint osteoarthritis.

Results: The average amount of removed disc was 1.363 g and a significant correlation was detected between the narrowing of disc height and the amount of removed disc. Although the disc height and the disc height ratio were significantly decreased (- 0.97 mm and 86.9%, respectively), the angle of sagittal rotation was well maintained. There were 18 (56.3%) cases of disc signal changes, six cases (18.8%) of subchondral marrow signal changes, and three cases (9.4%) of facet joint osteoarthritis. The success rate was 90.6%.

Conclusion: Although disc height narrowing was observed, there was no postoperative instability and the overall clinical outcome was satisfactory. Our results show that PELD is a useful and minimal invasive procedure for the selected patients who are suffering with lumbar disc herniation.

Index words : Spine, surgery
Spine, intervertebral disks
Spine, MR
Spine, CT

¹Departments of Diagnostic Radiology and ²Neurosurgery, Wooridul Spine Hospital, Seoul, Korea

³Department of Neurosurgery, Sanggye Paik Hospital, Inje University College of Medicine, Seoul, Korea

Received December 16, 2005 ; Accepted February 22, 2006

Address reprint requests to : Seung-Eun Chung, M.D., Department of Diagnostic Radiology, Wooridul Spine Hospital, 47-4 Chungdam-dong Kangnam-gu, Seoul 135-100, Korea.

Tel. 82-2-513-8197 Fax. 82-2-513-8146 E-mail: eunrad@dreamwiz.com

There are many surgical approaches for treating lumbar disc herniation. Many surgeons prefer to perform the standard open discectomy, and favorable outcomes for lumbar disc herniations have been reported (1 - 5); however, some radiological studies have demonstrated a loss of disc height after the operation. Narrowing of the disc space changes the load transmission to the corresponding facet joints and this ultimately leads to post-operative degenerative spondylotic changes and worsening of the back pain (6 - 10).

Various types of minimally invasive spinal surgery have recently been performed under local anesthesia to accomplish direct removal of the pathological disc fragments while preserving the healthy musculoskeletal structures (11 - 13).

Percutaneous endoscopic lumbar discectomy (PELD) is a new procedure that has been developed for the removal of soft disc materials in selected cases (14 - 19). According to recent reports, the clinical results of PELD are comparable to those of traditional open microdiscectomy (18 - 20). In 1997, Casey *et al.* reported on the post-operative imaging changes in the external geometry of the annulus and for the canal clearance after performing arthroscopic microdiscectomy; they suggested that this was convincing evidence showing the superiority of retrieving disc fragments via a posterolateral approach under arthroscopic control (21). However, our current study is rather different from their study in that we evaluated the radiological parameters including the disc

height, the disc signal intensity, the subchondral marrow signal intensity, the sagittal plane instability and the facet joints' osteoarthritis, and we also examined the correlation of these factors to the clinical outcome.

Materials and Methods

Patient selection

Between January 2000 and December 2000, 369 patients underwent PELD at the Wooidul Spine Hospital. The PELD indication criteria were as follows: 1) unilateral radicular leg pain rather than back pain, 2) soft lumbar disc herniations that did not occupy more than 25% of the spinal canal without any sequestered disc fragment or spinal stenosis and no previous surgery, as was confirmed by the findings on the computed tomographic (CT) scan and the magnetic resonance imaging (MRI) 3) the patients were without definite segmental instability, and 4) the patients has been unsuccessfully treated with conservative treatment for at least three months. Although there were a total 369 patients that fulfilled these requirements, only 30 patients were observed for a minimum of 3 years and they had undergone postoperative CT and MRI.

We retrospectively reviewed these 30 patients (32 cases, 24 males and 6 females with a mean age of 36.5 years, age range: 19 to 64 years). The average duration of symptoms was 25.6 months. The levels of herniation were L4-5 in 26 cases, L5-S1 in 3 cases, L3-4 in 2 cases

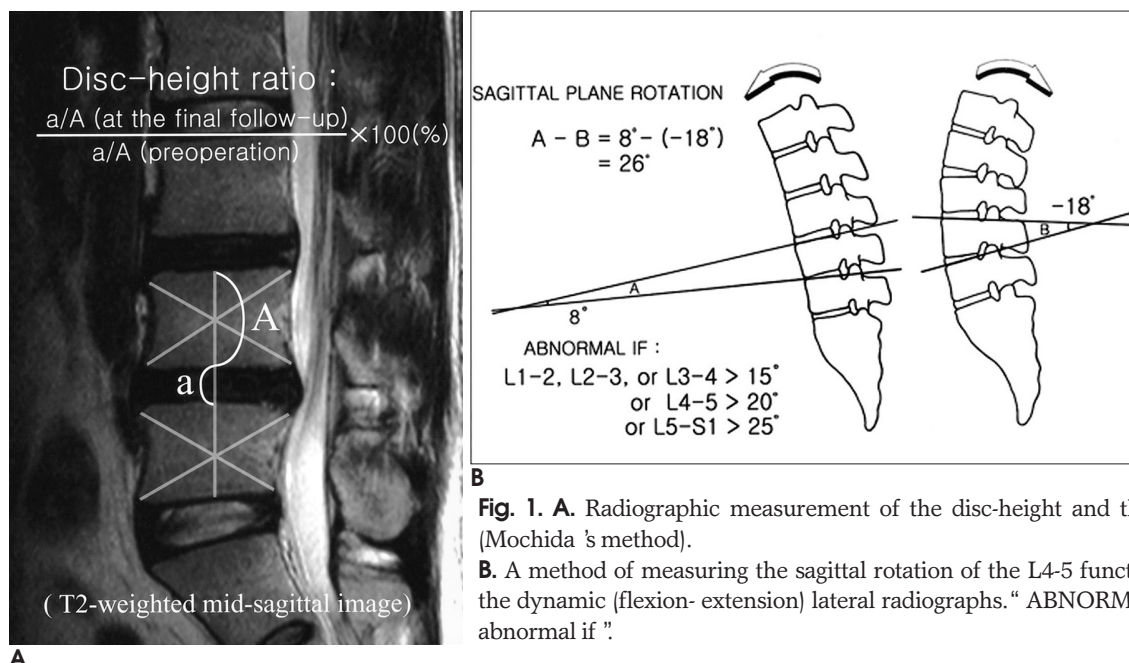


Fig. 1. A. Radiographic measurement of the disc-height and the disc height ratio (Mochida's method).

B. A method of measuring the sagittal rotation of the L4-5 functional spinal unit on the dynamic (flexion- extension) lateral radiographs. " ABNORMAL IF " means " It is abnormal if ".

and L2-3 in 1 case. Two patients had herniation at two levels: L4-5 and L5-S1. We used a modified MacNab classification (22) to classify the herniation type: protrusion, subligamentous disc extrusion (torn annular fibers and herniated fragments contained by the posterior longitudinal ligament), transligamentous disc herniation (ruptured posterior longitudinal ligament), and sequestration. There were 7 cases classified as protrusion and 25 cases as subligamentous disc extrusion.

The clinical outcomes were evaluated using the modified MacNab's criteria (23).

Radiological evaluation

The radiological evaluation of these patients included plain x-rays, CT and MRI, and these procedures were done both preoperatively and at the final follow-up. The MR imaging was performed on a 1.5T imager (Magnetom Symphony Ultragradiant system, Siemens, Erlangen, Germany); these images including a sagittal T1-weighted spin echo sequence (TR range/TE range: 550 - 750/12), a sagittal T2-weighted fast spin-echo sequence (TR range/TE range: 3500 - 4300/130 - 140/2), and a fast low-angle shot (FLASH) axial sequence (TR range/TE range: 49/25), with a flip angle of 30°. The section thickness was 4 mm with a 3.2 mm gap, a matrix size of 256 × 512 and a field of view (FOV) of 260 mm.

The CT examinations were performed on a Somatom Plus Sensation 4 scanner (Siemens, Erlangen, Germany), with a section thickness and interval of 2.5 mm, respectively.

The radiological findings we evaluated included the disc height, the disc signal intensity, the subchondral marrow signal intensity, the range of motion and the facet joints' osteoarthritis. The disc height and its ratio were measured on the T2-weighted mid-sagittal image according to the modified Mochida's method (Fig. 1A) (24). The angle of sagittal plane rotation was measured on the plain dynamic (flexion-extension) lateral radiographs using the method of White and Panjabi (Fig. 1B) (25). Disc degeneration was classified into five grades with using the T2-weighted mid-sagittal images according to the grading system proposed by Pearce et al (Table 1, Fig. 2) (26). Degenerative changes in the subchondral marrow were evaluated on both the T1- and T2 weighted MRI scans with using Modic's criteria (27). Type I changes were characterized by a decreased signal on the T1W sequence and an increased signal on the T2W sequence. Type II changes were characterized by an increased signal relative to normal bone marrow on the T1W sequence and a slight increased signal or isointensity on the T2W sequence. Type III changes were characterized by a decreased signal on both the T1W

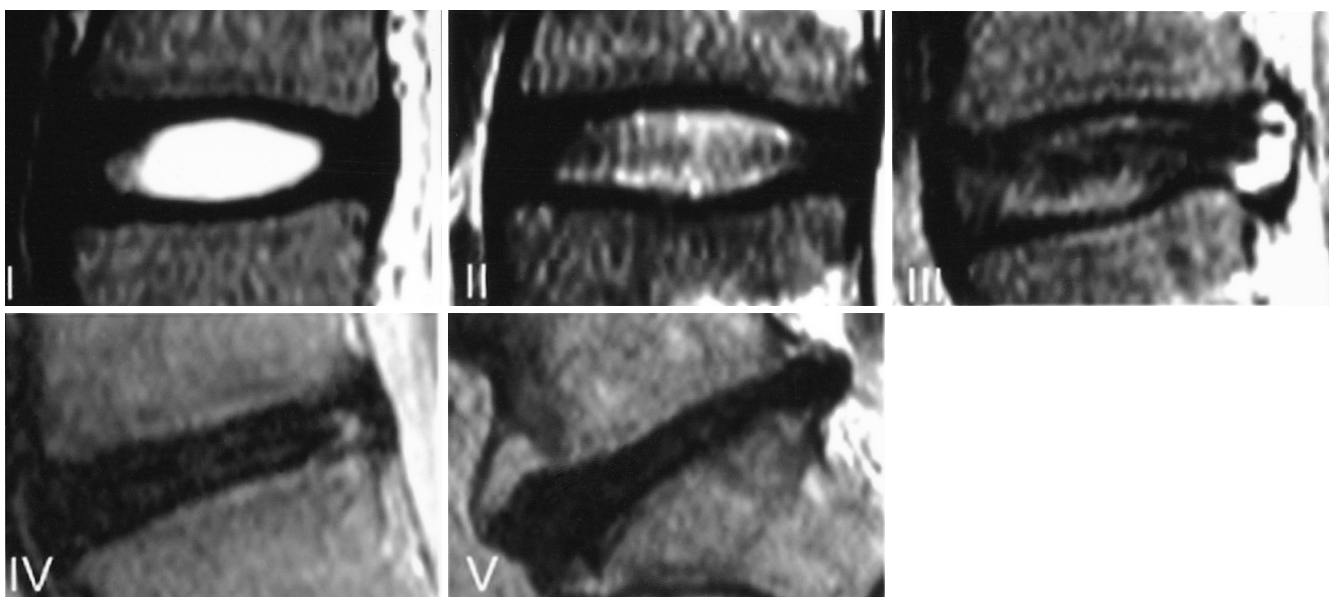


Fig. 2. I - V, Grade of the disc degeneration on the T2- weighted mid-sagittal image.

Grade I: homogenous, hyperintense signal intensity. Grade II: hyperintense signal intensity with a horizontal gray band. Grade III: inhomogenous, intermediate gray signal intensity. The distinction between the nucleus and annulus is unclear, and the disc height is normal or there is a slightly decreased disc height. Grade IV: inhomogenous decreased signal intensity. The distinction between the nucleus and annulus is lost, and the disc height shows a normal to moderate decrease. Grade V: inhomogenous, hypointense black signal intensity and collapsed disc height.

and T2W sequences. Facet joint osteoarthritis was divided into four grades via the MR images and the CT scans, and according to the grading system proposed by Fujiwara *et al* (28). Grade 1 indicated normal findings, grade 2 indicated mild osteoarthritis (joint space narrowing or mild osteophyte), grade 3 was moderate osteoarthritis (sclerosis or moderate osteophyte), and grade 4 was severe (marked osteophyte) osteoarthritis.

We also investigated the correlation between the narrowing of the disc height and the amount of disc removed, and the correlation between the disc signal changes and back pain.

Three radiologists who were “blinded” to the details of the cases retrospectively reviewed the imaging studies. Changes in the disc height, the disc height ratio and the range of motion were measured by computerized digitization, and the mean of the three measurements was then calculated. In addition, the disc signal intensity, the subchondral marrow signal intensity and the facet joint arthritis were assessed with interpretations determined by consensus of the radiologists. Statistical analysis was performed using independent sample t-tests, paired sample t-tests, chi-squared tests, Pearson correlation coefficient and Fisher’s exact tests. All P values less than 0.05 were determined to be statistically significant.

Surgical technique

Three surgeons performed all the surgeries. PELD was performed under local anesthesia with the patients in the prone position. The patient was kept conscious

during the procedure to allow monitoring of any changes in the signs and symptoms. A spinal needle was then inserted into the disc space and the intraoperative discography was performed using a contrast mixture of 6ml of telebrix and 1ml of indigo carmine. The goal of the intraoperative discogram was to stain the herniated disc and to provoke the patient’s symptom. A guidewire was inserted through the needle channel into the annulus and a small skin incision was then made. The following step was sequential dilatation with a 1-mm dilator and a 2-mm dilator, and the final 5-mm working cannula was then inserted. The herniated disc fragment was removed by using microforceps under the direct endoscopic view. A Holmium yttrium-aluminum-garnet (Ho: YAG) laser was used to ablate and shrink the herniated disc, and the procedure was finally completed with performing an endoscopic examination. The patient was directly asked whether the pain had decreased or disappeared after the removal of the disc material and decompression of the nerve root.

Results

Radiological Findings

1. Changes in the disc height and the disc height ratio: The mean preoperative disc height at the L4-5 level was

Table 1. Classification of the Disc Degeneration (Modified from Pearce)

Grade	Structure	Distinction of Nucleus and Annulus	Signal Intensity	Disc Height
	Homogeneous, bright white	Clear	Homogenous, hyperintense signal intensity	Normal
	Inhomogeneous with horizontal bands	Clear	Hyperintense signal intensity with horizontal gray band	Normal
	Inhomogeneous, gray	Unclear	Inhomogenous, intermediate gray signal intensity	Normal to slightly decreased
	Inhomogeneous, gray to black	Lost	Intermediate to hypointense	Moderately decreased
	Inhomogeneous, black	Lost	Hypointense	Collapsed disc

Table 2. Disc-height Ratio and Disc Height

Levels	Average of Preoperative Disc Height (mm)	Average of Disc Height at Final Follow-up (mm)	Average of Disc Height Ratio (%)	p-value
L2-3	9.90	9.90	100.00	
L3-4	12.40	11.30	90.55	0.05
L4-5	10.90	10.52	89.67	0.00
L5-S1	10.00	7.98	83.11	0.07
Overall	10.90	9.93	86.90	0.00

Table 3. The Narrowing of Disc Height and the Disc-height Ratio According to Age

	Age (yr)				
	20 (n=10)	30 (n=6)	40 (n=9)	50 (n=4)	60 (n=3)
Average of disc height ratio (%)	90.83	88.11	88.82	93.70	85.79
Average of preoperative disc height (mm)	11.13	10.83	10.62	10.26	12.63
Average of postoperative disc height (mm)	9.66	9.55	9.41	9.51	10.99
Average of disc height loss (mm)	1.44	1.28	1.21	0.75	1.64

10.90 mm, but this was reduced to 10.52 mm at the final follow-up assessment (-0.38 mm; $p < 0.01$). Overall, the mean preoperative disc height was decreased from 10.90 to 9.93 mm (-0.97 mm) at the final follow up examination; this was statistically significant ($p < 0.01$). The mean disc height ratio at the L3-4, L4-5 and L5-S1 levels were 90.6, 89.7 and 83.1%, respectively (Table 2). The average amount of disc that was removed was 1.363 g and significant correlation was detected between narrowing of the disc height and the amount of removed disc ($p < 0.01$). However, there was no statistically significant correlation between the disc degeneration and the narrowing of the disc height or its ratio in the different age groups (Table 3).

2. Changes of disc signal intensity: Changes of the disc signal intensity were observed in 18 cases (56.3%): 9 cases (28.1%) changed from grade II to III, 2 cases (6.3%) changed from grade II to IV, and 7 cases (21.9%) changed from grade III to II (Fig. 3). The remaining 14

cases were grade III, and no change of the signal intensity was observed. We then investigated the correlation between the disc signal changes and back pain. Two patients with disc signal decreases had worsened back pain, but the remaining 16 cases were improved. There was no statistically significant correlation between the disc signal changes and back pain.

3. Changes in the subchondral marrow signal intensity: Six cases (18.8%) showed change of the subchondral marrow signal: normal to Modic type II changes were seen at the L4-5 level in 5 cases (Fig. 4) and normal to Modic type I change was seen at the L5-S1 level in one case.

4. Changes in range of motion (ROM): The mean preoperative ROM was increased from 12.26° to 12.51° ($+0.25^\circ$) at the L4-5 level at the final follow-up examination, while those at the other levels were decreased. Overall, the mean ROM was decreased from 13.23° to 13.14° , but this result was so small as to be statistically insignificant. At the final follow-up examination, none of the patients had developed instability. The radiological changes are summarized in Table 4.

5. Osteoarthritic changes in the facet joints: There were 3 cases (9.4%) showing facet joint changes at the L4-5 level: grade II to III change was noted in 2 cases (6.3%) (Fig. 5) and grade III to IV change was noted in 1 case (3.1%). All three cases had worsened by one grade compared to before the surgery.

Table 4. Sagittal Instability (sagittal plane rotation)

Level	Case No.	Average of Preoperative Sagittal Instability	Average of Postoperative Sagittal Instability	p-value
L2-3	1	12.12	9.07	
L3-4	2	13.03	12.81	0.855
L4-5	26	12.26	12.51	0.760
L5-S1	3	22.18	20.22	0.554
Total	32	13.23	13.14	0.896

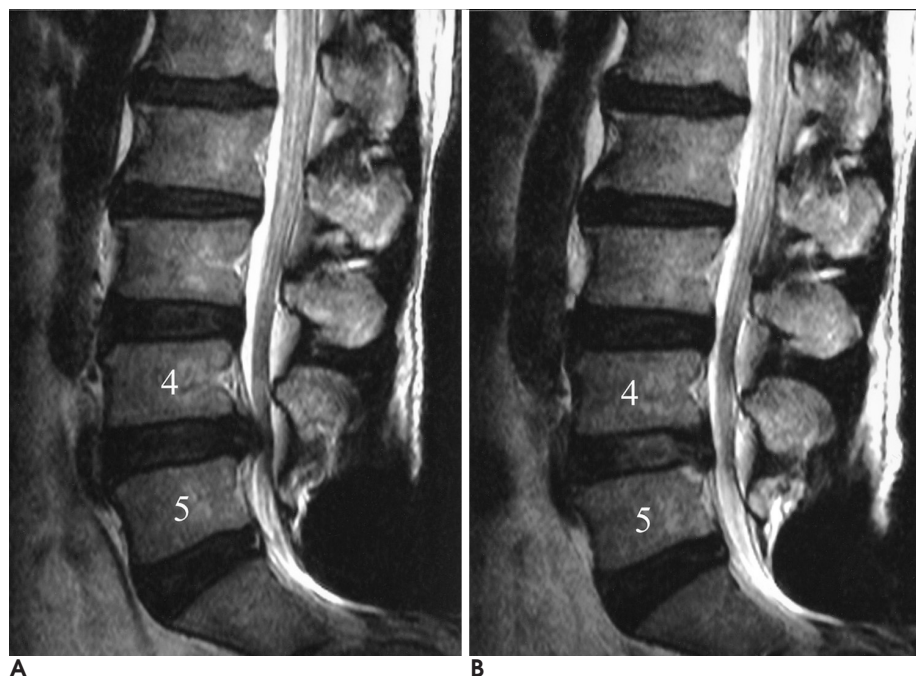


Fig. 3. A 57-year-old male patient who underwent PELD with a left central disc extrusion at the L4-5 disc level. A, the mid-sagittal T2-weighted (3600/132) MR images obtained before surgery. B, the mid-sagittal T2-weighted (3600/132) MR images obtained at the final follow-up. The 38 month-postoperative MRI demonstrates hyperintensity (grade II) at the L4-5 disc level, whereas hypointensity (grade III) was observed at this level before surgery.

Clinical outcomes

According to the modified MacNab criteria, 24 cases (75.0%) had excellent results, 5 cases (15.6%) had good results, 2 cases (6.3%) had fair results, and 1 case (3.1%) had a poor result. The success rate (an excellent or good result) was 90.6%. The mean operation time and postoperative hospital stay were 40.5 min (range: 20 - 75 min) and 14.7 hours (range: 1 - 49.3 hours), respectively.

Discussion

PELD is now being performed with increasing frequency in the advanced countries, yet open microdiscectomy is still the preferred surgical technique for treating a herniated lumbar disc by the majority of surgeons. Several studies have demonstrated comparable clinical outcomes for this minimally invasive procedure to those of open microdiscectomy (18 - 20, 29).

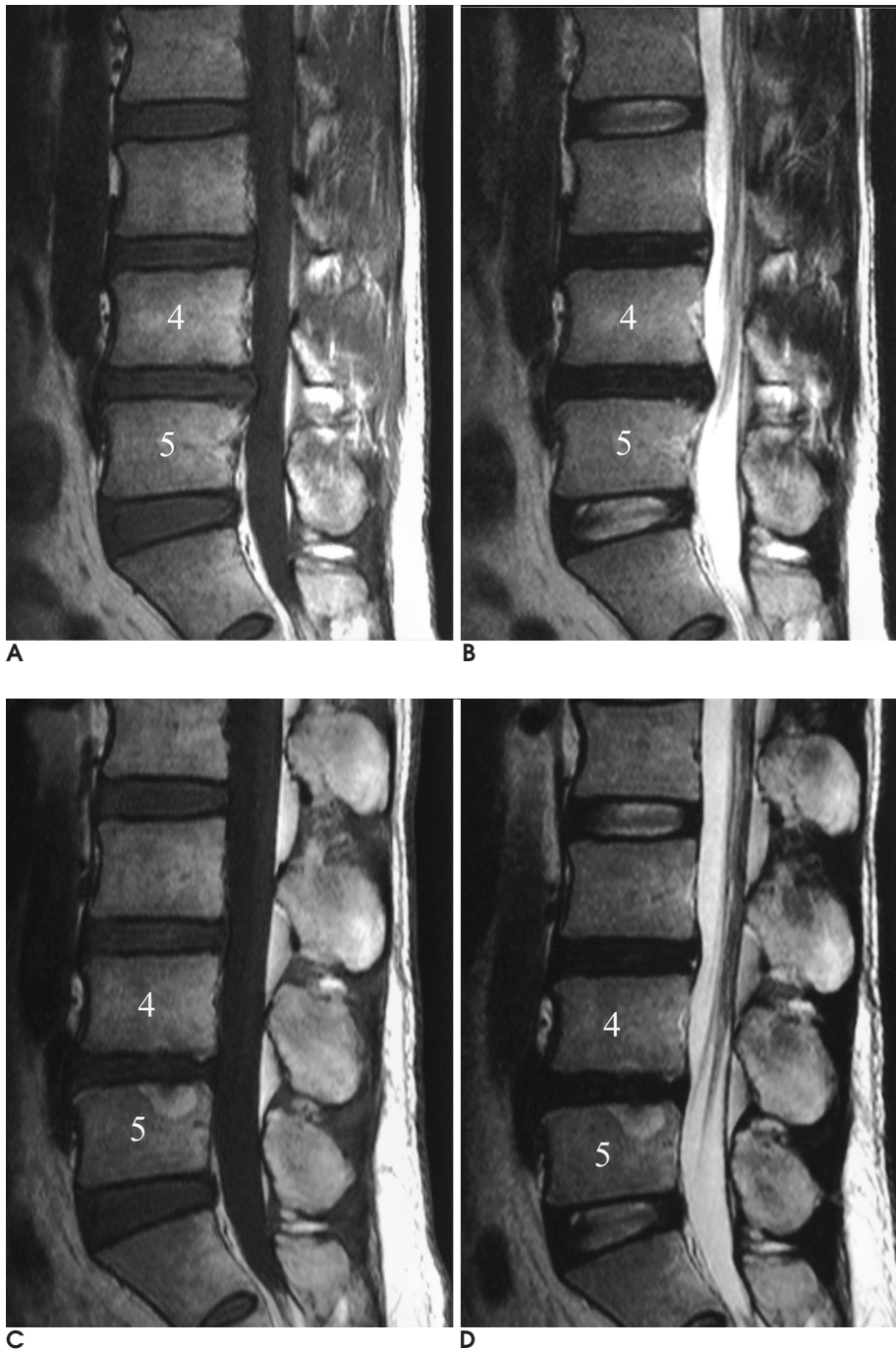


Fig. 4. A 36-year-old male patient who underwent a PELD with right central disc extrusion at the L4-5 disc level.

A, B. The preoperative mid-sagittal T1-weighted (587/12) image and the T2-weighted (3700/132) MR images show normal subchondral marrow of the L5 vertebral body.

C, D. The post operative mid-sagittal T1-weighted (717/12) and T2-weighted (4304/132) MR images taken at 40 months reveal the increased signal intensity of the subchondral marrow change, Modic type II, involving the L5 vertebral body.

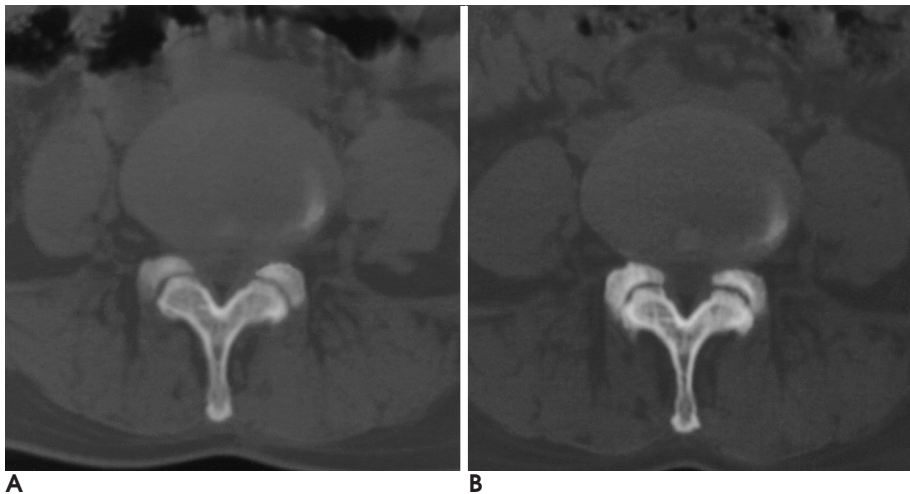


Fig. 5. A 38-year-old female patient with right central disc protrusion at the L4-5 disc level, and this patient underwent PELD two months after the initial surgery. A, axial CT scan images of the facet joint obtained before surgery. The CT scan taken 38 months postoperatively shows the facet joint has changed from grade II (A) to III (B).

However, the range of indications for performing PELD is not as wide as that for conventional open microdiscectomy. Casey et al have reported that performing imaging studies after arthroscopic microdiscectomy could document achieving effective fragmentectomy for a central or paramedical subligamentous disc herniation (21). However, that study was not designed to correlate the clinical outcome with the postoperative imaging changes. Hence, there haven't been any previous reports on the correlation between the radiological changes after PELD and the postoperative clinical outcomes. For these reasons, any objective evaluation of PELD has not previously been done and therefore, there is still much controversy about this procedure.

In this study, the authors investigated the postoperative radiological images that were taken after PELD and the related clinical outcome. Overall, the average disc height ratio in our study was 86.9% at a minimum of three years follow-up. Before conducting this study, the authors expected that the overall disc height change after PELD would be only minimal, yet the results showed that the disc height change after the procedure was relatively higher than we expected. There were close correlations between the total amount of removed disc material and the change in disc height, and so our results could be explained by the substantial amount of disc removed under PELD. In 2001, Yorimitsu et al reported a 78.8% change of the average disc height ratio at a minimum 10-year follow-up with performing standard discectomy (9). The disc height ratio noted in our study was a little higher than that of Yorimitsu's study.

There were 11 cases (34.4%) that showed decreased signal intensity. The findings of accelerated disc degeneration after a discectomy can be explained as over

time, the intradiscal tissue damage and volume loss can stimulate a degenerative process. However, the cause of the increased disc signal after laser discectomy was uncertain in seven cases (21.9%). Turgut et al. have reported on the postoperative disc signal changes after laser discectomy in their experimental studies. In their study, the intradiscal tissue was vaporized during the early period, but this tissue was replaced by cartilaginous cells and fibrous tissue at 60 days after laser irradiation. The MR imaging index histogram moved to the left in the early period, but it moved back to the right 60 days after laser irradiation (30, 31). This process was probably related to the regeneration process in the form of fibrous tissue proliferation on the intervertebral disc. Despite the small size of the study group in our study, we can postulate that the postoperative increase in the disc signal could have been caused by thermal modulation or reorganization after laser discectomy; however, these changes had no clinical affect.

In our study, six patients (18.8%) showed subchondral marrow signal change, but this feature was unrelated to the clinical outcome. It is known that the increased axial loading to the end plate after disc degeneration and after injury of the end plate due to the heat energy of the laser or because the photoacoustic mechanism for bone damage after laser surgery would cause subchondral marrow changes. Cvitanic et al. have reported subchondral marrow abnormalities in 41 cases (37.6%) of 109 laser discectomies, but these changes probably did not affect the surgical outcomes (32). They also reported that eleven patients with subchondral marrow abnormalities returned to a normal signal intensity 5 - 7 years after the laser discectomy, with eight of these patients showing improvements in their lower back pain. The Modic

changes reported in the literature after a partial discectomy have varied from 6% to 31%, and these changes had no relation to the clinical outcome (33 - 35).

Yorimitsu, et al. reviewed 131 patients who had been observed for a minimum of 10 years after undergoing a standard discectomy. They reported that three patients developed postoperative disc instability at the level of the discectomy. However, the unstable discs in five patients spontaneously stabilized after surgery due to progression of the degeneration (9). In our study, there was no postoperative segmental instability or spontaneous fusion, and the change in the overall ROM was minimal (13.23 °to 13.14 °). This result indicated that PELD was able to preserve the segmental spinal stability relatively well.

Three cases showed facet joint change. Osteoarthritic changes of the bilateral facet joints were always observed and this was regardless of the side of the operation. The authors assumed the cause of this facet joints osteoarthritis was not due to direct injury to the facet joint, but rather, it was due to secondary narrowing of the postoperative disc height. Unlike what has been observed with performing open discectomy, there was no direct damage to the facet joint from performing PELD.

Although the indications for the clinical application of PELD remain limited, our success rate was favorable (90.6%) according to MacNab's criteria (23). There were two cases with fair outcomes; one could be interpreted as resulting from the herniated nucleus not being completely removed at the L4-5 level, as well as that a new disc herniation was observed at the L5-S1 level. In the other case, however, the herniated disc was completely removed, but the cause of the less-than-successful outcome was not established from the radiological examination. The one patient with a poor result subsequently underwent open microdiscectomy because only incomplete decompression was achieved with PELD.

There have been a few radiological studies conducted after open discectomies that have been reported in the literature (6, 9). To the best of our knowledge, there have not been any previous studies on the correlation between the radiological changes after PELD and the postoperative clinical outcomes. According to our results, the clinical outcome of PELD was satisfactory, despite that there were some radiological changes. However, this study's weakness was the small size of the study group, and no comparison was done with the postoperative changes after the open discectomy. Thus, further studies will be needed to compare the radiologi-

cal changes after PELD with that of open discectomy.

In conclusion, the authors compared the preoperative and postoperative radiologic findings of the patients who underwent PELD. According to the radiologic features, there was definite disc height narrowing and some subchondral marrow changes were also observed. However, there were only small changes of the facet joints and no postoperative lumbar instability was observed. Therefore, the authors suggest that PELD is a useful and less invasive procedure than is open microdiscectomy for the selected patients suffering with lumbar disc herniation.

References

1. Davis RA. A long-term outcome analysis of 984 surgically treated herniated lumbar discs. *J Neurosurg* 1994;80:415-421
2. Dvorak J, Gauchat M-H, Valach L. The outcome of surgery for lumbar disc herniation. A 4-17 years' follow-up with emphasis on somatic aspects. *Spine* 1988;13:1418-1422
3. Mannismaki P, Vanharanta H, Puranen J. Disability 20-30 years after disc surgery: a follow-up of 162 patients. *Presented at the annual meeting of the International Society for the Study of the lumbar Spine* Marseilles, France, 1993, June 15-19
4. Smyth H, Gallagher J, McManus F. Surgery in lumbar disc protrusion: a long-term follow up. *Ir Med J* 1983;76:25-26
5. Weber H. Lumbar disc herniation. A controlled, prospective study with ten years of observation. *Spine* 1983;8:131-140
6. Kambin P, Cohen LF, Brooks M, Schaffer JL. Development of degenerative spondylosis of the lumbar spine after partial discectomy: comparison of laminotomy, discectomy and posterolateral discectomy. *Spine* 1995;20:599-607
7. Dunlop RB, Adams MA, Hutton WC. Disc space narrowing and the lumbar facet joints. *J Bone Joint Surg Br* 1984;66:706-710
8. Hanley EN Jr, Shapiro DE. The development of low-back pain after excision of a lumbar disc. *J Bone Joint Surg Am* 1989;71:719-721
9. Yorimitsu E, Chiba K, Toyama Y, Hirabayashi K. Long-term outcomes of standard discectomy for lumbar disc herniation: a follow-up study of more than 10 years. *Spine* 2001;26:652-657
10. Yang KH, King AI. Mechanism of facet load transmission as a hypothesis for low back pain. *Spine* 1984;9:557-565
11. Maroon JC. Current concepts in minimally invasive discectomy. *Neurosurgery* 2002;51:S137-145
12. Mayer HM. Spine update. Percutaneous lumbar disc surgery. *Spine* 1994;19:2719-2723
13. Thongtrangan I, Le H, Park J, Kim DH. Minimally invasive spinal surgery: a historical perspective. *Neurosurg Focus* 2004;16:E13
14. Hijikata S. Percutaneous nucleotomy. A new concept technique and 12 years' experience. *Clin Orthop Relat Res* 1989;238:9-23
15. Hoppenfeld S. Percutaneous removal of herniated lumbar discs. 50 cases with ten-year follow up periods. *Clin Orthop Relat Res* 1989;238:92-97
16. Kambin P, Schaffer JL. Percutaneous lumbar discectomy. Review of 100 patients and current practice. *Clin Orthop Relat Res* 1989;238:24-34
17. Shepperd JA, James SE, Leach AB. Percutaneous disc surgery. *Clin Orthop Relat Res* 1989;238:43-49
18. Schaffer JL, Kambin P. Percutaneous posterolateral lumbar discec-

- tomy and decompression with a 6.9-millimeter cannula. Analysis of operative failures and complications. *J Bone Joint Surg Am* 1991;73:822-831
19. Mayer HM, Brock M. Percutaneous endoscopic discectomy: surgical technique and preliminary results compared to microsurgical discectomy. *J Neurosurg* 1993;78:216-225
 20. Hermantin FU, Peters T, Quartararo L, Kambin P. A prospective, randomized study comparing the results of open discectomy with those of video-assisted arthroscopic microdiscectomy. *J Bone Joint Surg Am* 1999;81:958-965
 21. Casey KF, Chang MK, O'Brien ED, Yuan HA, McCullen GM, Schaffer J, et al. Arthroscopic microdiscectomy: comparison of preoperative and postoperative imaging studies. *Arthroscopy* 1997;13: 438-445
 22. MacNab I, McCulloch JA. *Disc ruptures*. In: Grayson TH. *Backache*. 2nd ed. Baltimore: Williams & Wilkins, 1990, pp130-134
 23. MacNab I. Negative disc exploration. An analysis of the causes of nerve-root involvement in sixty-eight patients. *J Bone and Joint Surg Am* 1971;53:891-903
 24. Mochida J, Nishimura K, Nomura T. Appropriate procedures of posterior hemiotomy and percutaneous nucleotomy in lumbar disc herniation. *Rinsho Seikei Geka* 1994;29:423-430
 25. White AA III, Panjabi MM. *Clinical Biomechanics of the Spine*, 2nd ed. Philadelphia: Lippincott, 1990:278-378
 26. Pearce RH, Thompson JP, Bebault GM, Flak B. Magnetic resonance imaging reflects the chemical changes of aging degeneration in human intervertebral disk. *J Rheumatol Suppl* 1991;27:42-43
 27. Modic MT, Steinberg PM, Ross JS, Masaryk TJ, Carter JR. Degenerative disk disease: assessment of changes in vertebral body marrow with MR imaging. *Radiology* 1988;166:193-199
 28. Fujiwara A, Tamai K, Yamato M, An HS, Yoshida H, Saotome K, et al. The relationship between facet joint osteoarthritis and disc degeneration of the lumbar spine: an MRI study. *Eur Spine J* 1999;8:396-401
 29. Yeung AT, Tsou PM. Posterolateral endoscopic excision for lumbar disc herniation: Surgical technique, outcome, and complications in 307 consecutive cases. *Spine* 2002;27:722-731
 30. Turgut M, Ozcan OE, Sungur A, Sargin H. Effect of Nd: YAG Laser on experimental disc degeneration Part II. Histological and MR imaging findings. *Acta Neurochir* 1996;138:1355-1361
 31. Turgut M, Acikgoz B, Kilinc K, Ozcan OE, Erbengi A. Effect of Nd: YAG laser on experimental disc degeneration Part I. Biochemical and radiographical analysis. *Acta Neurochir* 1996;138:1348-1354
 32. Cvitanic OA, Schimandle J, Casper GD, Tirman PF. Subchondral marrow changes after laser discectomy in the lumbar spine: MR imaging findings and clinical correlation. *AJR Am J Roentgenol* 2000;174:1363-1369
 33. Boden SD, Davis DO, Dina TS, Sunner JL, Wiesel SW. Postoperative diskitis: distinguishing early MR imaging findings from normal postoperative disk space changes. *Radiology* 1992;184:765-771
 34. Grand CM, Bank WO, Baleriaux D, Matos C, Levivier M, Brotchi J. Gadolinium enhancement of vertebral endplate following lumbar disk surgery. *Neuroradiology* 1993;35:503-505
 35. Fraser RD, Sandhu A, Gogan WJ. Magnetic resonance imaging findings 10 years after treatment for lumbar disc herniation. *Spine* 1995;20:710-714

2006;54:425 - 433

		3	1
	1	2	
	3		
	2	3	2
		2	
:			3
:	3	가	,
	30 (32)	.	,
MacNab's criteria	4		
:	1.363 g	,	
	- 0.97 mm	,	18 (56.3%)
,	6 (18.8%)	,	3 (9.4%)
90.6%			
:			
	가	,	