

Nail - Patella

: 1

2

Nail - patella syndrome (NPS)
(nail dysplasia),
(iliac horn),
(patellar aplasia or hypoplasia),
(dysplasia or dislocation of the elbow)

NPS

NPS

(nail dysplasia),
(patellar aplasia or hypoplasia),
(iliac horn),
(dysplasia or dislocation of the elbow)
(1 - 4). NPS

NPS, hereditary osteo - onychodysplasia
(HOOD), elbow - patella syndrome hereditary
arthrodysplasia (1, 4).

23

가

(patellar aplasia or
hypoplasia), (iliac horn)
(dysplasia or dislocation of the elbow) (1 - 4).
(patellar aplasia or hypoplasia) NPS (3).

(Fig. 1).

가

(1, 4).

90%

(Fig. 2).

가

(Fig. 3).

70%

가

(4).

CT scan

가 (Fig. 4).

NPS

30 - 60%

(2, 4 - 6).

가 (1, 4).

(1, 3).

(4, 7),

(6),

(4).

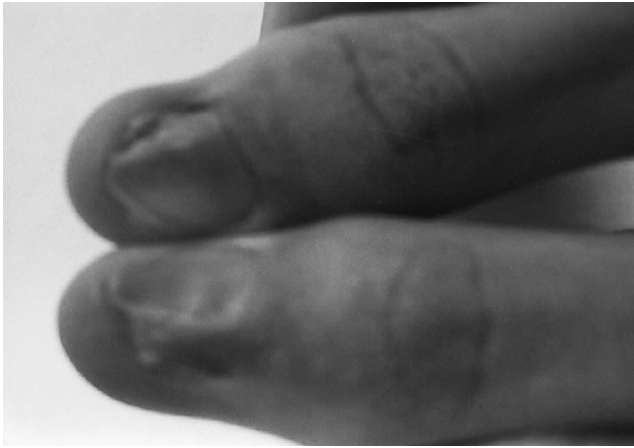


Fig. 1. Photograph demonstrates hemianonychia of both thumbs.

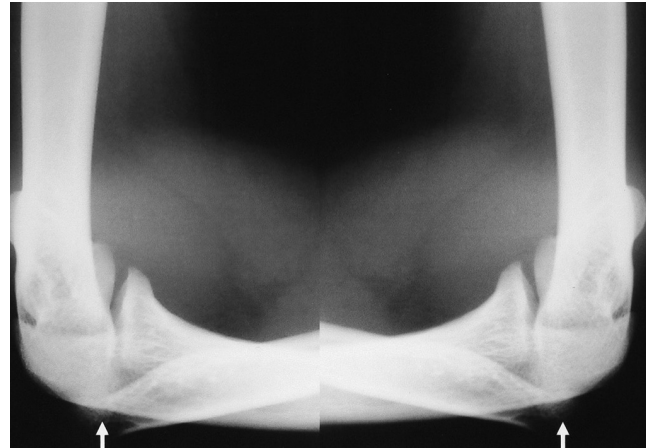


Fig. 3. Simple radiography of both elbows show dysplasia and dislocation of radial heads (arrows).

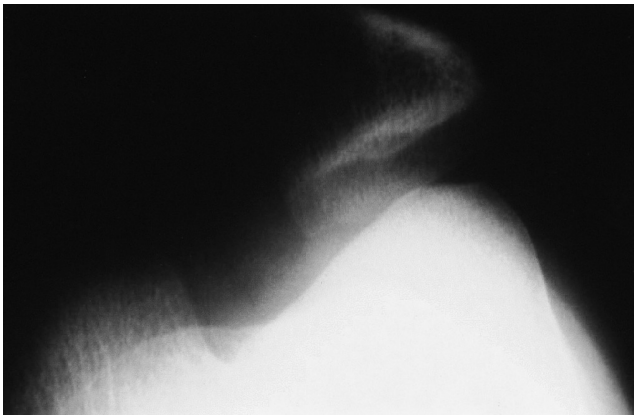


Fig. 2. Simple radiography of right knee shows patellar hypoplasia.

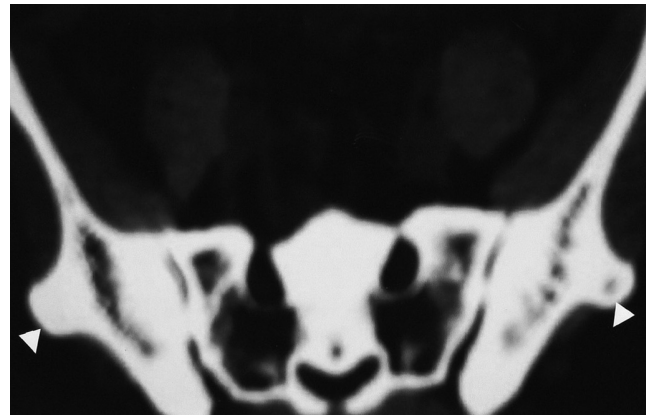


Fig. 4. Pelvis CT scan shows the bilateral iliac horns (arrow heads), bony projection posterolaterally.

(4, 7, 8).

Ishio - pubic - patella hypoplasia
(bone dysplasia)
(8).
NPS

1. Garces MA, Muraskas JK, Muraskas EK, Abdel-Hameed MF. Hereditary onchy-osteo-dysplasia (HOOD syndrome): report of two cases. *Skeletal Radiol* 1982;8:55-58

2. Karabulut N, Ariyurek M, Erol C, Tacal T, Balkanci F. Imaging of "iliac horns" in nail-patella syndrome. *J Comput Assist Tomogr* 1996;20:530-531
3. Bongers EM, Gubler MC, Knoers NV. Nail-patella syndrome. Overview in clinical and molecular findings. *Pediatr Nephrol* 2002; 17:703-712
4. Beguiristain JL, de Rada PD, Barriga A. Nail-patella syndrome: long term evolution. *J Pediatr Orthop B* 2003;12:13-16
5. Reed D, Nichols DM. Computed tomography of "iliac horns" in hereditary osteo-onychodysplasia (nail-patella syndrome). *Pediatr Radiol* 1987;17:168-169
6. Yarali HN, Erden GA, Karaarslan F, Bilgic SC, Cumhuri T. Clavicular horn: another bony projection in nail-patella syndrome. *Pediatr Radiol* 1995;25:549-550
7. Guidera KJ, Satterwhite Y, Ogdenb JA, Pugh L, Ganey T. Nail-patella syndrome: a review of 44 orthopedic patients. *J Pediatr Orthop* 1999;11:737-742
8. Habboub HK, Thneibat WA. Ischio-pubic-patellar hypoplasia: is it a new syndrome? *Pediatr Radiol* 1997;27:430-431

Radiologic Findings of Nail-Patella Syndrome: Case Report¹

Sung Bin Park, M.D., Jeong Su Yoo, M.D.²

¹*Department of Physical Examination for Conscription, Seoul Regional Military Manpower Office*

²*Central Physical Center, Military Manpower Administration*

Nail - patella syndrome is a rare autosomal dominant pleiotropic disorder characterized by dysplasia of the nails, patellar aplasia or hypoplasia, iliac horns, and dysplasia or dislocation of the elbow.

We experienced a case of nail - patella syndrome. NPS is a relatively uncommon disease; however, an understanding of the typical radiologic findings is useful in establishing the diagnosis and guiding the treatment.

Index words : Bones, abnormalities

Bones, dysplasia

Patella

Address reprint requests to : Sung Bin Park, M.D., Department of Physical Examination for Conscription,
Seoul Regional Military Manpower Office, 159-1 Singil-dong, Yeongdeungpo-gu, Seoul 150-057, Korea.
Tel. 82-2-820-4552 Fax. 82-2-820-4548 E-mail: sbpark@ulsan.md