

## Parachordoma of the Chest Wall: Case Report<sup>1</sup>

Seung Hyun Cho, M.D., Nak Kwan Sung, M.D., Kyung-Jae Jung, M.D.,  
Young Hwan Lee, M.D., Young Chan Park, M.D., Ho Kyun Kim, M.D.,  
So yoon Park, M.D.<sup>2</sup>, Ki Sung Park, M.D.<sup>3</sup>, Sung Min Ko, M.D.<sup>4</sup>

We report radiologic findings in a case of chest wall parachordoma in a 32-year-old male with right upper back pain. The plain radiograph and CT scan of the chest revealed a soft tissue mass in the right lateral chest wall with rib erosion. En-bloc surgical resection with chest wall reconstruction was performed.

**Index words :** Soft tissue, neoplasms  
Neoplasms, CT  
Parachordoma

Parachordoma is an extremely rare soft tissue tumor with unique immuno-histochemical features, and it can arise from the arm, thigh, leg, chest wall, and buttock (1 - 6). The histogenesis of parachordoma is still controversial. These tumors display a slow growing nature, but they also show locally destructive growth. After surgery, local recurrence has been reported in some cases (1, 2).

We report the imaging features of histologically confirmed parachordoma arising from the chest wall.

### Case Report

A 32-year-old man visited our hospital and presented with right upper back pain, but he was without any respiratory symptoms. The physical examination showed neither a palpable mass nor skin changes. Chest plain

radiograph revealed a smooth margined, pleural-based mass of the right hemithorax (Fig. 1A), and a CT scan was performed for further evaluation of the mass. About a 5 cm-sized, pleural-based, non-calcified soft tissue mass was noted in the right lateral chest wall. The mass was smoothly margined and it had caused erosion of the adjacent 5th and 6th ribs with focal destruction and hypertrophy (Fig. 1B). Contrast-enhanced CT scan revealed a homogeneous non-enhancing soft tissue mass of the right lateral chest wall. A small portion of the mass had penetrated chest wall (Fig. 1C). There was no significant lymph node enlargement noted. Technetium-99 m methyl di-phosphonate (Tc-99m MDP) whole body bone scan showed an area of faint increased radioactivity at the right 6th rib region. After considering all imaging features, we thought there was the possibility of a malignant peripheral nerve sheath tumor or parosteal malignant bone tumor such as osteosarcoma or metastasis.

Percutaneous core biopsy was performed with 19.5-gauge coaxial biopsy needle (AUTOVAC, Bard-Angiomed, Karlsruhe, Germany) under fluoroscopic guidance. The pathological analysis showed tiny clusters of cells with vacuolated cytoplasm in the background of chondroid matrix; there was positive staining for keratin, vimentin, and S-100 protein, which is suggestive of parachordoma (Fig 1D, 1E). En-bloc resection

<sup>1</sup>Department of Diagnostic Radiology, School of Medicine, Catholic University of Daegu

<sup>2</sup>Department of Diagnostic Pathology, School of Medicine, Catholic University of Daegu

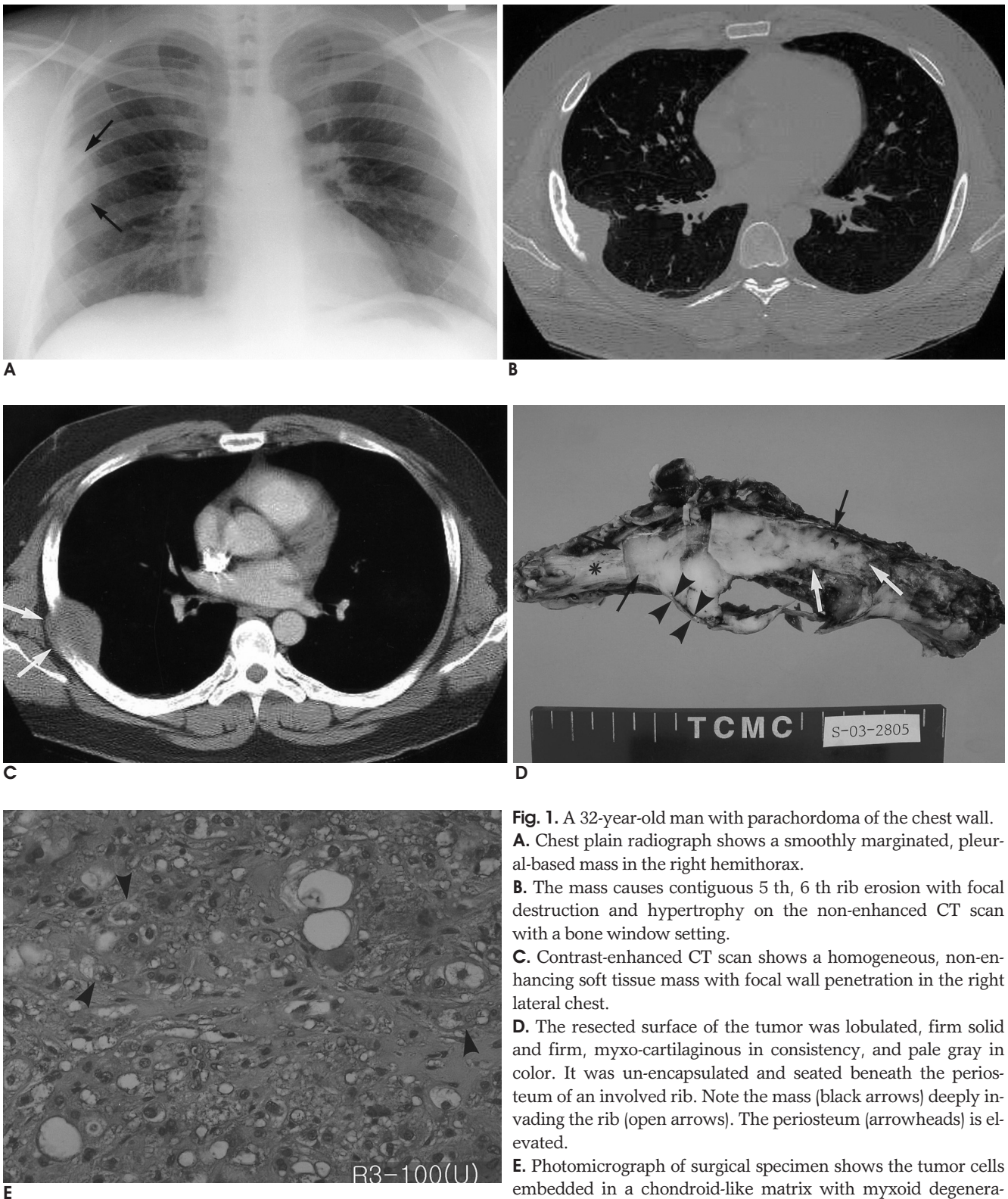
<sup>3</sup>Department of Thoracic Surgery, School of Medicine, Catholic University of Daegu

<sup>4</sup>Department of Diagnostic Radiology, School of Medicine, Keimyung University

Received April 12, 2004; Accepted August 4, 2004

Address reprint requests to : Kyung-Jae Jung, M.D., Department of Diagnostic Radiology, School of Medicine, Catholic University of Daegu, 3056-6, Daemyung 4-Dong, Nam-gu, Daegu 705-718, Korea.

Tel. 82-53-650-4329 Fax. 82-53-650-4339 E-mail: kjjung@cu.ac.kr



**Fig. 1.** A 32-year-old man with parachordoma of the chest wall.  
**A.** Chest plain radiograph shows a smoothly margined, pleural-based mass in the right hemithorax.  
**B.** The mass causes contiguous 5 th, 6 th rib erosion with focal destruction and hypertrophy on the non-enhanced CT scan with a bone window setting.  
**C.** Contrast-enhanced CT scan shows a homogeneous, non-enhancing soft tissue mass with focal wall penetration in the right lateral chest.  
**D.** The resected surface of the tumor was lobulated, firm solid and firm, myxo-cartilaginous in consistency, and pale gray in color. It was un-encapsulated and seated beneath the periosteum of an involved rib. Note the mass (black arrows) deeply invading the rib (open arrows). The periosteum (arrowheads) is elevated.  
**E.** Photomicrograph of surgical specimen shows the tumor cells embedded in a chondroid-like matrix with myxoid degeneration. Most of the tumors are made up of cords and small indistinct lobules of polygonal eosinophilic cells with clean, vacuolated cytoplasm (H & E,  $\times 100$ ).

with chest wall reconstruction was successfully performed. The mass was originating from the rib, and the periosteum of the rib was elevated by the mass. The pathologic review of the resected right chest wall mass confirmed the previous histologic diagnosis.

### Discussion

Parachordoma was first reported as 'chordoma periphericum' by Laskowski in 1955 (8) and it was re-described as 'parachordoma' by Dabska in 1977 (1). To our knowledge, it has been fewer than 40 reported cases since the first description. Parachordoma grows very slowly, but it has a tendency of local destruction. After surgery, local tumor recurrence has been reported in some cases (1, 2).

The origin of these tumors is still uncertain; the origin has been suggested as ectopic nests of notochord (3), schwann or other neuron-related cells (4), specialized synovial cells (1), and totipotential mesenchymal cells (5). Parachordoma and chordoma have some similar characters of local aggressiveness and the light microscopic features. Chordoma generally involves the axial skeleton, from the spheno-occipital area to the sacrococcygeal area, and this tumor is thought to originate from notochordal remnants. However, parachordoma can be located at any site.

On gross pathologic examination, the tumor showed as a lobulated, un-encapsulated, grayish-white solid mass with focal fibrous bands and a smooth glistening appearance (7). On light microscopic examination, parachordoma is similar to chordoma and extra-skeletal myxoid chondrosarcoma. Immuno-histochemical studies are thought to be helpful for the differential diagnosis. Parachordoma and chordoma are positive for cytokeratin, and this is unlike the extraskeletal myxoid chondrosarcoma. However, parachordoma is especially negative for cytokeratin 1/10, unlike the chordoma (6, 9).

The simple radiographic findings of most parachordomas are well-demarcated soft tissue tumors with or without contiguous bone erosion. Our case also showed a smoothly marginated, pleural-based mass with focally adjacent rib erosion. The CT findings of chest wall parachordoma have been reported as a homogeneous soft tissue density tumor without signs of rib erosion or pulmonary connection by Gimferrer et al (10). Contrast-enhanced CT scan of our case also revealed a homogeneous non-enhancing soft tissue mass of the right lateral chest wall, but the CT scan also showed adjacent rib

erosion. The contrast-enhanced CT scans of most parachordomas arising from sites other than chest wall reveal non-enhancing, homogeneous soft tissue density (2, 7). In our opinion, the light microscopic findings of abundant myxoid, chondroid and hyaline background probably explains the lack of enhancement of parachordoma. Because of local aggressiveness, this soft tissue tumor can involve the adjacent bone. The Technetium-99 m methyl di-phosphonate (Tc-99 m MDP) whole body bone scan showed a faint, increased radioactivity at the right 6th rib area that was the site of bone involvement in our case. Small areas of calcification in the tumor were reported by Karabela-Bouropoulou et al (7). Neither internal hemorrhage nor necrosis has been reported in these tumors. MRI series have been performed for imaging characterization in two cases by Koh et al (5) and Ishida et al (2); the scans revealed soft tissue masses showing low signal intensity on the T1-weighted images, high signal intensity on the T2-weighted images, and heterogeneous contrast enhancement.

The differential diagnosis of a soft tissue mass in the chest wall includes lymphoma, neurogenic tumor, plasmacytoma, primary bone tumor, soft tissue sarcoma, hemangioma, hemangiopericytoma, desmoid tumor, metastasis, and etc. All these tumors including parachordoma have similar imaging features. In our opinion, parachordoma displays nonspecific imaging findings. In our case, the imaging features of parachordoma, in brief, were good demarcation, little enhancement, no calcification, local aggressiveness, and homogeneous soft tissue density without any necrosis or hemorrhage.

In summary, we report here on a case of parachordoma of the chest wall, and this is an exceedingly rare soft tissue tumor. In most cases, differentiation between parachordoma and other chest wall tumors is very difficult. Parachordoma has nonspecific imaging features and it must be included in the differential diagnosis of chest wall tumors.

### References

1. Dabska M. Parachordoma: a new clinicopathologic entity. *Cancer* 1977;40:1586-1592
2. Ishida T, Oda H, Oka T, Imamura T, Machinami R. Parachordoma: an ultrastructural and immunohistochemical study. *Virchows Arch A Pathol Anat Histopathol* 1993;422:239-245
3. Shin H, Mackay B, Ichinose H, Ayala AG, Romsdahl MM. Parachordoma. *Ultrastruct Pathol* 1994;18:249-256
4. Hirokawa M, Manabe T, Sugihara K. Parachordoma of the buttock: an immunohistochemical case study and review. *Jpn J Clin Oncol* 1994;24:336-339

5. Koh JS, Chung JH, Lee SY, Cho KJ. Parachordoma of the tibia: report of a rare case. *Pathol Res Pract* 2000;196:269-273

6. Flope AL, Agoff SN, Willis J, Weiss SW. Parachordoma is immunohistochemically and cytogenetically distinct from axial chordoma and extraskeletal myxoid chondrosarcoma. *Am J Surg Pathol* 1999;23: 1059-1067

7. Karabela-Bouropoulou V, Skourtas C, Liapi-Avgeri G, Mahaira H. Parachordoma: a case report of a vary rare soft tissue tumor. *Pathol Res Pract* 1996;192:972-978

8. Laskowski J, Zarys O. *Pathology of tumors*. In Kolodziejska H. Warsaw, Poland: PZWL, 1955:91-99

9. Fisher C. Parachordoma exists-but what is it?. *Adv Anat Pathol* 2000;7:141-148

10. Gimferrer JM, Baldo X, Montero CA, Ramirez J. Chest wall parachordoma. *Eur J Cardiothorac Surg* 1999;16:573-575

2004;51:295 - 298

