

Aneurysm Formation of Cervical Aortic Arch Combined with Subaortic Left Innominate Vein: Case Report¹

Young-Min Han, M.D.^{1,4}, Ja-Hong Gu, M.D.², Gong-Yong Jin, M.D.,
Hyo-Sung Kwak, M.D., Gyung-Ho Chung, M.D., Myoung-Ja Chung, M.D.³

An asymptomatic 26-year-old man was initially admitted with a suspicious mediastinal mass. On the basis of the contrast-enhanced chest CT findings, aneurysm formation involving the left cervical aortic arch associated with subaortic left innominate vein was diagnosed. The aneurysm was confirmed by MR angiography and DSA. The arch aneurysm was surgically removed. We describe this case, and review the literature.

Index words : Anomalies, congenital

Aorta, aneurysm

CT, MRI, angiography

Cervical aortic arch

A cervical aortic arch is a rare aortic arch anomaly assumed to result from persistence of the third aortic arch and regression of the normal fourth arch (1). Most patients with this anomaly are asymptomatic, but symptoms of dysphagia and respiratory distress due to compression by the vascular ring have been reported (1 - 7). Aneurysm formation involving the cervical aortic arch is very rare (2 - 14). Subaortic left innominate vein have usually been associated with heart anomaly (15 - 17). We report a case in which aneurysm formation involved the cervical aortic arch associated with the subaortic left innominate vein.

Case Report

A 26-year-old man who had been healthy and symptomatic was admitted to our institution, where plain chest radiography initially indicated a mediastinal mass. Blood pressure in the right and left arm was 180/100 mmHg and 134/93 mmHg, respectively, without medication. A chest radiograph depicted a superior mediastinal mass in the left side (Fig. 1), and the aortic knob appeared to be small. CT demonstrated that the mass was a left-sided cervical aortic arch (Fig. 2) that compressed the left upper lobe at lung window setting. Linear calcification denoted a fusiform dilated aneurysmal wall (Fig. 3), but none was present in the ascending, thoracic, or abdominal aorta. The size of the ascending aorta was normal (30 mm), but the descending aorta was narrower than usual, only 15 mm. The left innominate vein drained into the superior vena cava behind the aorta, which was in the anomalous subaortic position of the brachiocephalic vein (Fig. 2).

Routine laboratory data were normal. MR angiography depicted a left-side aortic arch with normal branching of the innominate and left common carotid arteries,

¹Department of Radiology, Chonbuk National University Medical School

²Department of Thoracic Surgery, Chonbuk National University Medical School

³Department of Pathology, Chonbuk National University Medical School

⁴Institute of Cardiovascular Research, Chonbuk National University Medical School

Received June 27, 2003 ; Accepted October 20, 2003

Address reprint requests to : Young-Min Han, M.D., Department of Radiology, Institute of Cardiovascular Research, Chonbuk National University Hospital, 634-18 Keumam-dong, Chonju 560-182, Korea.

Tel. 82-63-250-1176 Fax. 82-63-272-0481

E-mail: ymhan@chonbuk.ac.kr

hypertrophy of the right vertebral artery and obliteration of the left vertebral artery (Fig. 4). Thoracic aortography using a right axillary approach demonstrated a left-side aortic arch with normal branching of the innominate and left common carotid arteries (Fig. 5). The

configuration of the ascending aorta was normal, but the diameter of the descending thoracic aorta was less than usual. The aortic arch was elongated and tortuous between the origin of the left common carotid and the left subclavian arteries, and inferior to the arch, a fusiform

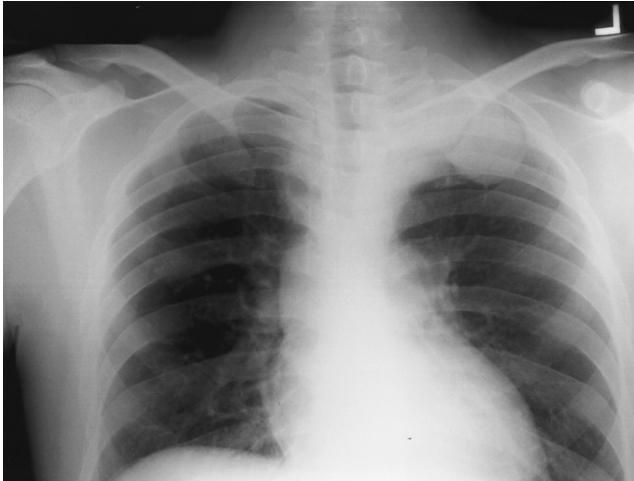


Fig. 1. A chest radiograph shows a superior mediastinal mass.

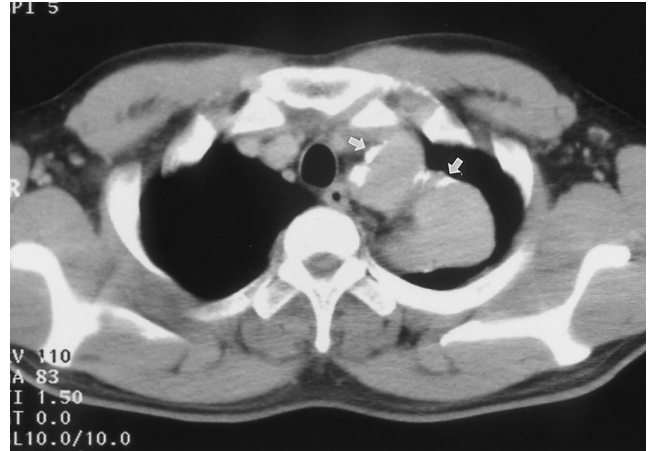

Fig. 3. Non-contrast CT shows linear calcifications (arrows) along the dilated aneurysmal wall.

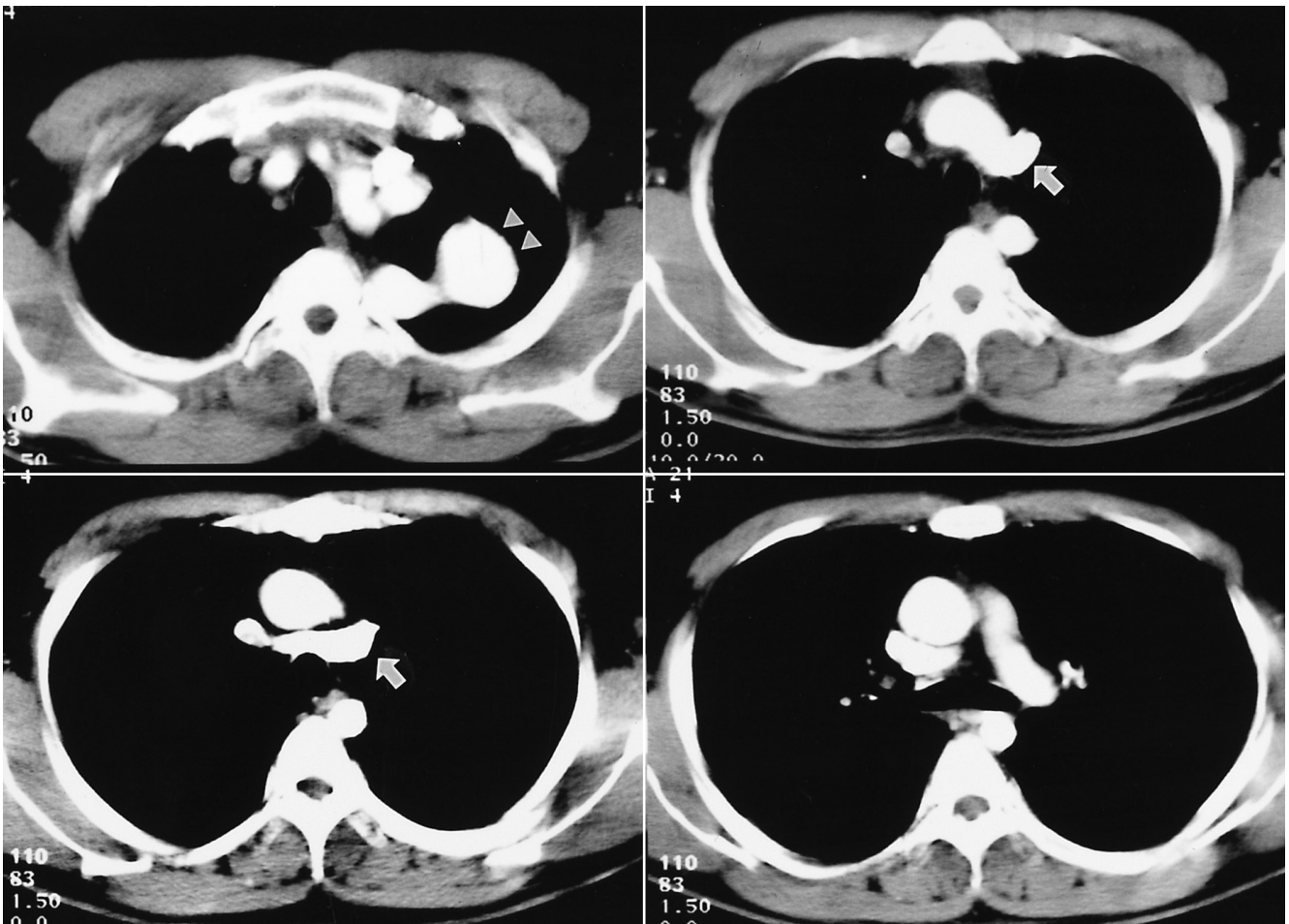


Fig. 2. Contrast-enhanced CT shows a tortuous fusiform dilated transverse arch aneurysm (arrowheads). The subaortic left innominate vein (arrows) is noted.

aneurysm had formed (Fig. 5). The left vertebral artery was not identified, and the descending thoracic aorta was left-sided.

At surgery, an aneurysm was found at the site at which the truncus arteriosus is usually present. The aneurysm was resected, and a Gore-Tex bypass graft used to replace the tortuous aortic arch between the origin of the left common carotid artery and the descending thoracic aorta. The left subclavian artery was sutured to the bypass graft. Histologic examination revealed a true aneurysm, which had atherosclerosis of the thick intima and media of the aortic wall, with dystrophic calcification, and a layer of adventitia (Fig. 6).

Discussion

The mechanism of development of an aortic arch anomaly is explained by the hypothetical double aortic arch system (1). Between the fifth and seventh embryonic weeks, the persistence of the left fourth branchial arch and regression of the right fourth branchial arch produce a normal left aortic arch. Cervical aortic arch anomaly arises from the abnormal persistence of the

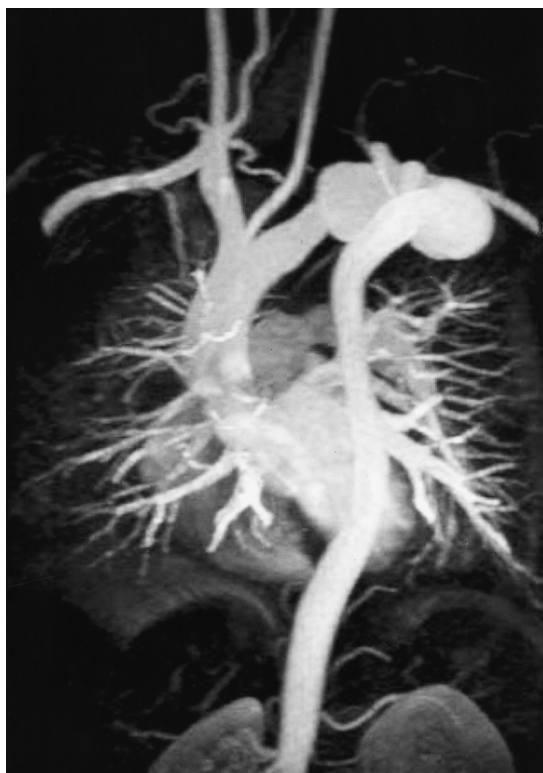


Fig. 4. MR angiography shows a tortuous dilated transverse aortic arch aneurysm. The ascending aorta reveals a normal configuration, and the size of the descending aorta revealed a small diameter.

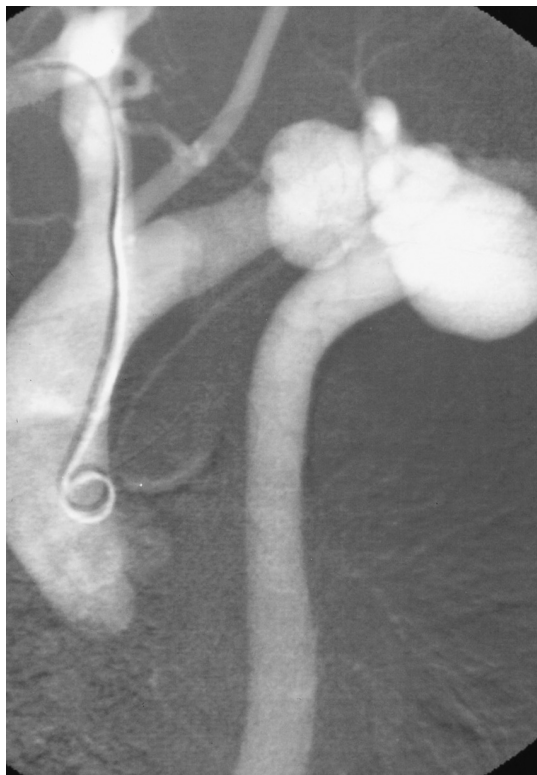


Fig. 5. Thoracic aortography shows a tortuous dilated transverse aortic arch aneurysmal formation in the left anterior oblique view. The brachiocephalic and left common carotid arteries show normal branching, and the ascending aorta is not tortuous. The left vertebral artery is not identified.

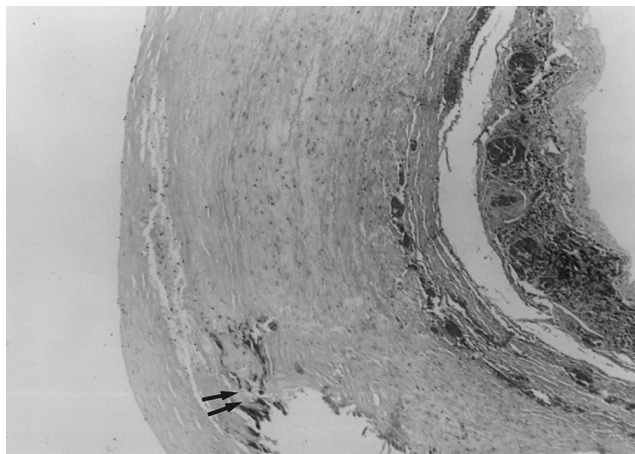


Fig. 6. The microscopic findings show thickening of aortic wall, accumulation of foamy histiocytes and dystrophic calcification (arrows) in the media of the aneurysmal wall.

thoracic aorta is left sided in the type-D cervical aortic arch of the original classification, though Akduman *et al.* (8) and Hirao *et al* (13) showed that a right-sided descending thoracic aorta can also be classified as type D. In our case, the elongated tortuous transverse arch is thought to have originated from a persistent left third branchial arch.

The left brachiocephalic vein extends from the junction of the left internal jugular and left subclavian vein to the junction of the right brachiocephalic and right superior caval vein. The normal course is obliquely downwards and to the right, passing in front of the left subclavian, left common carotid, and brachiocephalic arteries, beneath the aortic arch. Very rarely, this vein follows an anomalous course, passing from left to right below the arch of the aorta, to enter the superior caval vein below the orifice of the azygos vein (15 - 17).

To our knowledge, this is the first documented case of aneurysm formation involving the cervical aortic arch associated with subaortic left innominate vein to appear in the literature in English (Table 1). In reported cases in which an aneurysm involved the cervical aortic arch, patient age was 6 - 59 (mean, 30) years, but among the 14 patients (M:F = 4:10), only two were children. Type D in the Haughton classification is the most frequently occurring type of cervical aortic arch associated with aortic aneurysm (10/14 cases: 71%). A ventricular septal defect occurred in two patients, and in ten, involved a cervical aortic arch, with characteristic symptoms which in three cases included pain around the neck,

shoulder, chest or back. An ischemic cerebrovascular attack occurred in two patients, including one child; dysphagia in two, and dyspnea in three. The aneurysm ruptured in one patient (10), and another developed aortic dissection (4). In one other, aortic coarctation and aneurysm involved the left cervical aorta (14). In contrast, adult patients with no cervical aortic arch aneurysm were usually asymptomatic or experienced dysphagia (1, 7).

Aortic aneurysms were located in the aortic arch in 11 patients, the descending thoracic aorta in two and both the arch and descending thoracic aorta in one. Nine of ten Haughton type-D aortic arch aneurysms occurred between the left common carotid and the subclavian artery, the location in which they are least common (6, 10).

In congenital heart disease detected at echocardiography, the brachiocephalic vein has been reported to occupy an anomalous position in 0.98% of cases (24/2457) (15). Gerlis *et al.* (16) reviewed the literature, finding that in 25 cases, the brachiocephalic vein occupied an anomalous subaortic position. Sixteen cases were confirmed at necropsy; in ten, associated cardiovascular disease and anomaly were present, but in six there was no such association. Nine cases were confirmed by echocardiography and angiography, and in eight, cardiovascular disease was also present (16). Mill *et al.* (17) reported seven cases in which the course of the left brachiocephalic vein was found during surgery to be anomalous; six of these involved the tetralogy of Fallot, and in

Table 1. Cervical Aortic arch Associated with Aneurysm

Case No.	Author/Age/ Sex	Haughton Classification	Location of aneurysm	Position of DA	Symptoms	Stenosis of aorta of major vessels	Other anomaly	Pathology of aneurysm
1.	Cooley, 39/F	Unclassified	DA	L	None (Mass)	None	VSD	(-)
2.	Morris, 35/F	D	DA	L	Dyaphagia, dyspnea	(+)	None	(-)
3.	Cao, 21/F	D	TA	L	Severe neck pain*	(+)	None	Cystic Medial Necrosis
4.	van Nooten, 17/F	D	TA	L	None	(+)	None	Cystic Medial Necrosis
5.	Kumar, 37/F	D	TA	L	Cough, mass	None	None	(-)
6.	Holland, 42/F	E	Arch	L	Retrosternal pain	None	None	(-)
7.	Akduman, 41/F	C	Arch, DA	R	Dyspnea	(+)	None	(-)
8.	Kumar, 19/M	B	Arch	L	None (Mass)	None	VSD	(-)
9.	Pearson, 6/F	D	TA	L	Paresthesia	None	None	(-)
10.	Pearson, 11/F	D	TA	L	Dyspnea**	(+)	None	(-)
11.	Farsak, 24/F	D	TA	Not described	Mass, dysphagia	None	None	Cystic Medial Necrosis (basophilic degeneration)
12.	Hirao, 59/M	D	TA	R	Previous TIA	(+)	None	Atherosclerosis
13.	Imai, 48/M	D	TA	L	H/T, murmur***	None	None	Atherosclerosis
14.	Present case, 26/M	D	TA	L	None (Mass)	(+)	V. A****	Atherosclerosis

DA: Descending Aorta, L: Left, VSD: Ventricular Septal Defect, (-): Not obtained, TA: Transverse Arch, located between left common carotid and subclavian arteries, *: Aortic Dissection, R: Right, **: Aneurysm Rupture, TIA: Transient Ischemic Attack, H/T: Hypertension, ***: Aortic Coarctation, V.A****: Anomalous subaortic position of innominate vein

one, the aortic arch was interrupted. Kim et al. (18) reported 14 cases of subarotic left innominate vein. In our case, spiral chest CT showed good delineation of the anomalous subaortic position of the brachiocephalic vein.

Pathologically, medial cystic necrosis of the wall of the aortic aneurysm was observed in three younger patients age 17 - 24 (mean, 21) years, and atherosclerosis in three older patients age 26 - 59 (mean, 44) years. Pearson et al. (10) stated that the aortic aneurysms develop in the cervical aortic arch for reasons which include abnormal embryologic development, abnormal connective tissue, altered hemodynamics and aortic wall stress, and trauma. In our case, heavy calcification was observed only in the walls of the tortuous transverse arch and arch aneurysm, not in those of other regions of the aorta. Akduman et al. (8) and Hirao et al. (13) also reported the same findings, which suggest that abnormal histology of the walls of the cervical aortic arch, arch aneurysm, and the upper descending aorta, as well as the tortuosity of the transverse arch, caused hemodynamic disturbance and produced a large aneurysm (3). Taneja et al. (19) reported pseudocoarctation of the aorta, but in our case, the pathologic findings demonstrated the presence of a true aneurysm, which was differentiated from pseudocoarctation. The diameter of the ascending aorta was normal, but that of the descending aorta was smaller than usual. After surgery, our patient suffered hypertension, which may have been caused by a discrepancy between the sizes of the ascending and descending thoracic aorta. In our case, the abnormal course of the left innominate vein behind the aorta was visible at chest CT. The presence of an aneurysm involving the cervical aortic arch associated with the subaortic left innominate vein has not previously been reported in the literature.

In conclusion, aneurysm formation involving the left cervical aortic arch, visible at plain radiography, as a left superior mediastinal mass, is very rare. Contrast enhanced CT, MR angiography and DSA very easily differentiated between the aneurysm formation associated with subaortic left innominate vein and other masses.

Acknowledgements

We thank Bonnie Hami, M.A., at the Department of Radiology, University Hospitals of Cleveland, for her

editorial assistance in the preparation of this manuscript.

References

1. Acikel U, Ugurlu B, Hazan E, Salman E. Cervical aortic arch. A case report. *Angiology* 1997;48:659-662
2. Cooley DA, Mullins CE, Gooch JB. Aneurysm of right-sided cervical aortic arch: surgical removal and graft replacement. *J Thorac Cardiovasc Surg* 1976;72:106-108
3. Morris T, Ruttley M. Left cervical aortic arch associated with aortic aneurysm. *Br Heart J* 1978;40:87-90
4. Cao P, Angelini P, Colonna L, Cristallo E, Cooley DA. Cervical aortic arch with medial cystic necrosis. *Bull Texas Heart Inst* 1980;7:188-193
5. Van Nooten G, Deuvaert F, De Paepe J, Primo G. Left-sided cervical aortic arch. *Acta Chir Belg* 1986;86:248-250
6. Kumar S, Mandalam KR, Unni M, Roy S, Gupta AK, Rao VR. Left cervical arch and associated abnormalities. *Cardiovasc Intervent Radiol* 1989;12:88-91
7. Holland P, Fitzpatrick JD. Case report: magnetic resonance imaging of a right-sided cervical aortic arch with a congenital aneurysm. *Clin Radiol* 1991;43:352-355
8. Akduman EI, Balkanci F, Ariyurek OM. Rare anomaly of the aortic arch complex with extreme degenerative changes. A case report. *Angiology* 1994;45:249-252
9. Kumar S, Bajaj R, Gujral R. Case report: MR angiography of cervical aortic arch. *Clin Radiol* 1997;52:717-719
10. Pearson GD, Kan JS, Neill CA, Midgley FM, Gardner TJ, Hougren TJ. Cervical aortic arch with aneurysm formation. *Am J Cardiol* 1997;79:112-114
11. Farsak B, Yilmaz M, Kaplan D, Boke E. Cervical aortic arch with aneurysm formation. *Eur J Cardiothorac Surg* 1998;14: 437-439
12. Houghton VM, Fellows KE, Rosenbaum AE. The cervical aortic arches. *Radiology* 1975;114:675-681
13. Hirao K, Miyazaki A, Noguchi M, Shibata R, Hayashi K. The cervical aortic arch with aneurysm formation. *J Comput Assist Tomogr* 1999;23:959-962
14. Imai Y, Harada T, Yamada H, et al. Left cervical aortic arch with aortic coarctation and saccular aneurysm. *Jpn Circ J* 2000;64:544-546
15. Choi JY, Jung MJ, Kim YH, Noh CI, Yun YS. Anomalous subaortic position of the brachiocephalic vein (innominate vein): an echocardiographic study. *Br Heart J* 1990;64:385-387
16. Gerlis LM, Ho SY. Anomalous subaortic position of the brachiocephalic (innominate) vein: a review of published reports and report of three new cases. *Br Heart J* 1989;61:540-545
17. Mill MR, Wilcox BR, Detterbeck FC, Anderson RH. Anomalous course of the left brachiocephalic vein. *Ann Thorac Surg* 1993;55: 600-602
18. Kim SH, Chung JO, Im JG, Choi YW, Choe YH, Han MC. Subarotic left innominate vein: radiologic findings and consideration of embryogenesis. *J Thorac Imaging* 1999;14:142-146
19. Taneja K, Kawlra S, Sharma S, Rajani M. Pseudocoarctation of the aorta: complementary findings on plain film radiography, CT, DSA, and MRA. *Cardiovasc Intervent Radiol* 1998;21:439-441

