

Breast Gigantism Induced by D-Penicillamine: Case Report¹

Ji Hyeon Cha, M.D., Hak Hee Kim, M.D., Sun Mi Kim, M.D.,
Myung Hee Seo, M.D., Hoi Soo Yoon, M.D.

D-penicillamine, a chelating agent of copper, is the drug of choice for the treatment of Wilson's disease. Breast enlargement is a rare complication arising from its use, and we report a case of breast gigantism which developed after it had been used for ten months to treat this condition. Mammography demonstrated bilaterally enlarged dense breasts; ultrasonography, similarly, demonstrated enlargement, revealing the presence of a mass, shown at biopsy to be benign, in the left one.

Index words : Breast gigantism

D-penicillamine, breast enlargement

Breast

D-penicillamine, a metal antagonist, has been widely used in the treatment of rheumatoid arthritis, Wilson's disease, systemic sclerosis, and biliary cirrhosis (1). Possible complications of penicillamine therapy, however, are macromastia and gynecomastia, and several cases have been reported (1 - 7). We describe a case involving a 22-year-old woman who underwent ten months of D-penicillamine therapy for Wilson's disease and noticed gradual enlargement of both breasts.

Case Report

During a two-month period, a 22-year-old woman noticed gradual enlargement of both breasts. After Wilson's disease was diagnosed in 1992, D-penicillamine treatment was initiated, but after seven years the medication was withdrawn due to hirsutism. Due to dysarthria and gait disturbance, D-penicillamine treat-

ment (750 mg per day) was restarted, but 10 months later, both breasts had become significantly larger, without mass. Physical examination showed that the breasts were tense, hard, and lumpy (Fig. 1A), and laboratory tests indicated that prolactin levels had risen to 37.9 ng/ml. Levels of both luteinizing and follicle-stimulating hormone were within the normal range, however. Mammography demonstrated bilaterally enlarged dense breasts (Fig. 1B, C); ultrasonography also demonstrated breast enlargement, together with a benign mass in the left one. Ultrasonography-guided core needle biopsy was performed (Fig. 1D), revealing mild hyperplasia of the myxoid stroma. Three months after discontinuing D-penicillamine, the breasts had reverted to their normal size.

Discussion

Wilson's disease is a congenital disorder of metal metabolism, arising due to a lack of ceruloplasmin. D-penicillamine, as a chelating agent of copper, is the drug of choice for the treatment of the condition (2), and is also an effective treatment for rheumatoid arthritis and systemic sclerosis. D-penicillamine has numerous adverse effects on bone marrow suppression, obliterating bron-

¹Department of Radiology, Asan Medial Center, University of Ulsan College of Medicine

Received August 6, 2003 ; Accepted December 19, 2003

Address reprint requests to : Hak Hee Kim, M.D., Department of Radiology, Asan Medial Center, University of Ulsan College of Medicine, 388-1 Pungnap-dong, Songpa-gu, Seoul 138-736, Korea.

Tel. 82-2-3010-4400 Fax. 82-2-476-0090 E-mail: hkhkim@amc.seoul.kr

chioritis, nephritic syndrome, thyroiditis, and polyneuropathy of both the mouth and skin (3, 4). Breast enlargement is an unusual complication, encountered in both pre- and postmenopausal patients with normal or increased prolactin levels (1). The nature of the relationship between D-penicillamine, serum prolactin levels, and breast enlargement has not yet been clearly explained, through a report has indicated that D-penicillamine may alter the circulating prolactin level or the response of the mammary glands to prolactin (5). Only two cases of Breast enlargement and hyperprolactinemia after treatment with D-penicillamine have been reported (6).

Breast tissues are of two major histologic types: parenchymal tissue, which is dependent upon estrogen and progesterone for growth and development, and stromal or connective tissue which, in contrast, is regulated by the pituitary gonadotrophins, prolactin, and growth hormone. Histologic examinations has thus mainly revealed rich connective tissues and no changes in glandular tissues (5, 7), while radiography has demonstrated the presence of large nodules with or without distorted internal architecture and external contours (7).

The interval between the start of treatment and the onset of mammary enlargement has ranged from 12 weeks to 18 months (8). In our case, the enlargement of

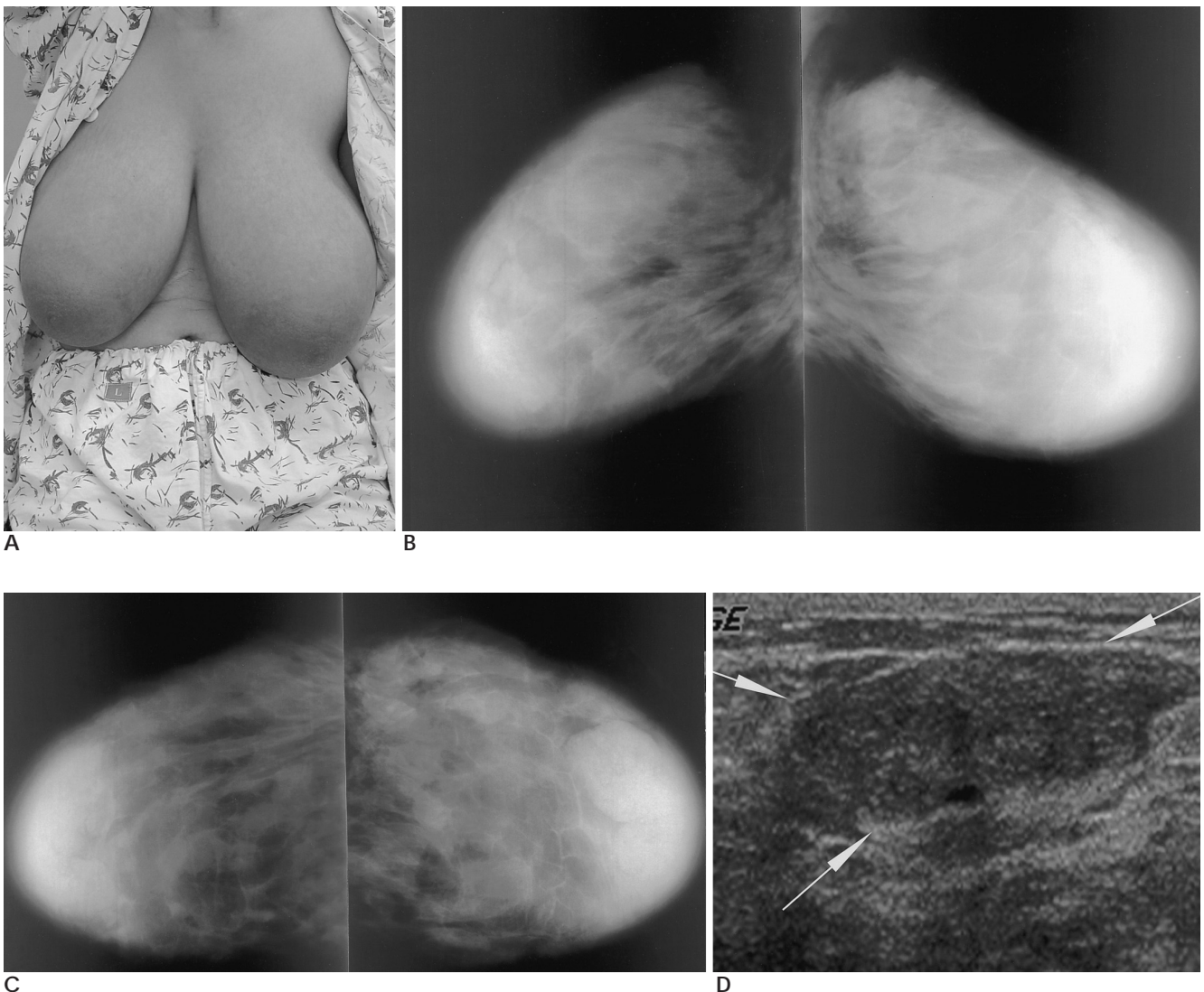


Fig. 1. A 22-year-old woman with Wilson's disease.

A. Both breasts are enlarged on physical examination.

B, C. On mediolateral oblique view (**B**) and craniocaudal view (**C**) shows large and dense breasts.

D. On ultrasonography shows a benign-looking nodule in the left breast (arrows) and ultrasonography-guided core biopsy reduced mild hyperplasia of myxoid stroma.

both breasts was apparent after ten months. Reports have stated that when D-penicillamine was replaced by danazole, the symptoms subsided, through surgery was sometimes necessary (1, 7).

Breast gigantism is a rare complication of D-penicillamine therapy, and we have described a case in which the condition arose after the drug was used to treat Wilson`s disease. The radiologic findings were bilaterally enlarged breasts with extremely dense fibro-glandular tissue at mammography, and a benign mass at ultrasonography.

References

1. Joseph ZT. Breast enlargement induced by D-penicillamine. *Ann*

Pharmacol 2002;36:444-445
2. Rose BI, LeMaire WJ, Jeffers LJ. Macromastia in a woman treated with penicillamine and oral contraceptives. *J Reprod Med* 1990;35:43-45
3. Passas C, Weinstein A. Breast gigantism with penicillamine therapy. *Arthritis Rheum* 1978;21:167-168
4. Desai SN. Sudden gigantism of breasts: drug induced?. *Br J Plast Surg* 1973;26:371-372
5. Finer N, Emery P, Hicks BH. Mammary gigantism and D-penicillamine. *Clin Endocrinol* 1984;21:219-222
6. Kahl LE, Medsger TH, Klein I. Massive breast enlargement in a patient receiving D-penicillamine for systemic sclerosis. *J Rheumatol* 1985;12:990-991
7. Desautels JE. Breast gigantism due to D-penicillamine. *Can Assoc Radiol J* 1994;45:143-144
8. Sakai Y, Wakamatsu S, Ono K, Kumagai N. Gigantomastia induced by bucillamine. *Ann Plast Surg* 2002;49:193-195

