

가 .

26 Soave

20 cc

Swenson , modified Duhamel , Soave (1).

(frozen section)

(2 - 6).

MR

1

CT

CT

가

(Fig. 1C).

Miles

(Fig. 1D).

27 가 1

1

, S

3 cm

가

(myenteric plexus)

(submucosal plexus)

(ganglion

cell)가

가

(internal anal sphincter)

가

MR

T1

, T2

가

(anorectal line)

, 80%

S

10%

(splenic flexure)

, 10%

(1).

3 × 4 cm, 3 × 2 cm

(suprlevator space)

(colostomy)

6

1

, Soave, modified Duhamel, Swenson

- S

(1).

Soave

(aganglionic)

가

(perineal approach)

(seromuscular tunnel)

1

2001

2003 9 3

2003 10 30

90%

가

(2-6).

가
, 26 Soave

가 (7).
(eccentric/polypoid)

CT

가

(8). MRI
T2

(9). CT

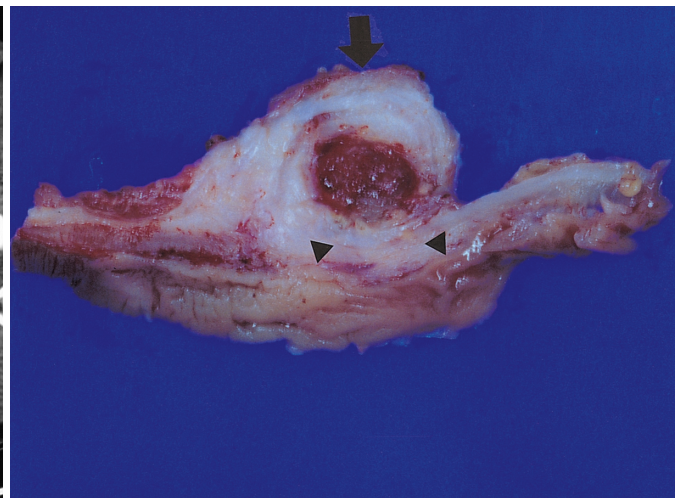
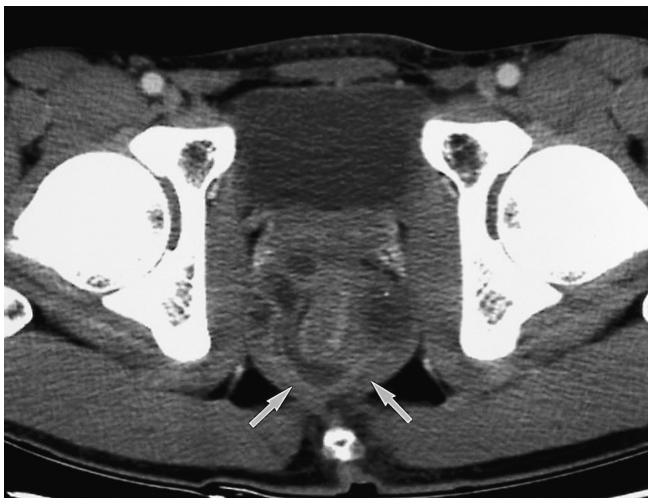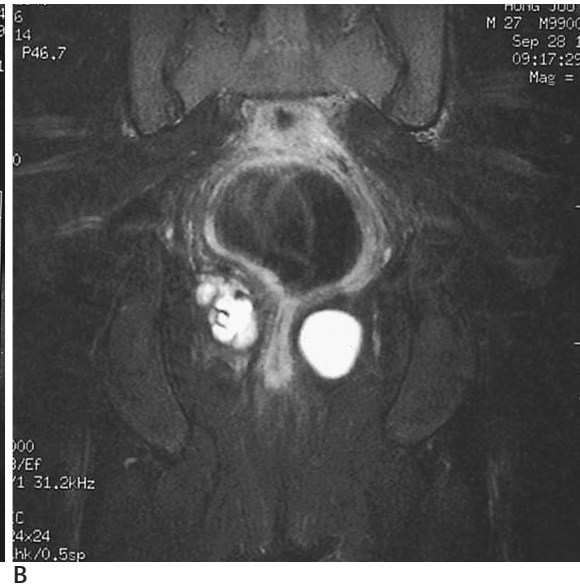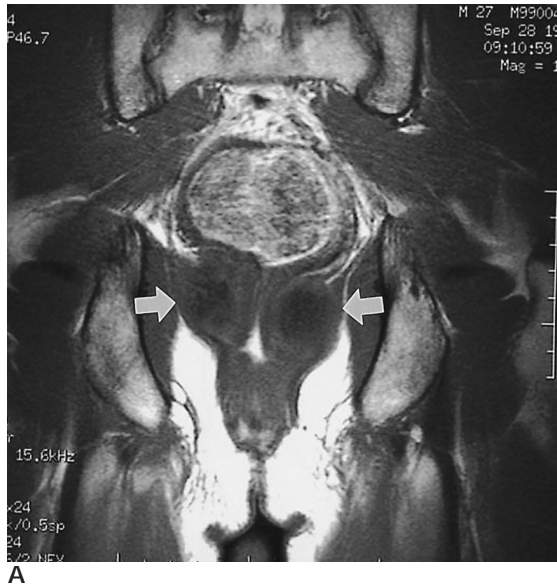


Fig. 1. A 27-year-old man with a mucinous adenocarcinoma arising at the anastomotic site after surgery for Hirschsprung's disease.

A. T1-weighted coronal MR image shows bilateral perirectal mass (arrows).

B. T2-weighted coronal MR image shows bilateral perirectal mass with bright signal portion. Note internal septum in right portion of mass.

C. Contrast-enhanced pelvis CT shows low attenuation mass lesion around the rectum. Multiple internal septations are seen. A faint dot like calcification is also noted in left-sided lesion. Note posterior portion of mass (arrows) between right and left perirectal mass.

D. Gross surgical specimen shows smooth-surfaced mass (arrow) ventral to normal rectal mucosa (arrow heads).

MRI T2
가
가
가
(signet ring cell) 가
가 (7),

ease: a 20-year experience. *J Pediatr Surg* 1997;32:1221-1225

1. Townsend CM, Beauchamp RD, Evers BM. Sabiston Textbook of Surgery. Philadelphia; Saunders, 2001;1473-1475
2. Reding R, de Ville de Goyet J, Gosseye S, et al. Hirschsprung's dis-

3. Bai Y, Chen H, Hao J, Huang Y, Wang W. Long-term outcome and quality of life after the Swenson procedure for Hirschsprung's disease. *J Pediatr Surg* 2002;37:639-642
4. Teitelbaum DH, Cilley RE, Sherman NJ, et al. A decade of experience with the primary pull-through for Hirschsprung's disease in the newborn period: a multicenter analysis of outcomes. *Ann Surg* 2000;232:372-380
5. Rescorla FJ, Morrison AM, Engles D, West KW, Grosfeld JL. Hirschsprung's disease. Evaluation of mortality and long-term function in 260 cases. *Arch Surg* 1992;127:934-938
6. Yanchar NL, Soucy P. Long-term outcome after Hirschsprung's disease: patients' perspectives. *J Pediatr Surg* 1999;34:1152-1160
7. Buetow PC, Buck JL, Carr NJ, Pantongrag-Brown L. From the archives of the AFIP. Colorectal adenocarcinoma: radiologic pathologic correlation. *RadioGraphics* 1995;15:127-146
8. Wilson RE, Donohue JH. Neoplasia of the colorectum. In: Phillips SF, Pemberton JH, Short RG, eds. The large intestine: physiology, pathophysiology, and disease. New York, NY: Raven press, 1991; 521-547
9. Hussain SM, Outwater EK, Siegelman ES. Mucinous versus non-mucinous rectal carcinomas: differentiation with MR imaging. *Radiology* 1999;213:79-85

J Korean Radiol Soc 2004;50:55 - 57

Mucinous Adenocarcinoma Arising at the Anastomotic Site after Operation for Hirschsprung's Disease: Case Report¹

Hyung Soo Kim, M.D., Kwon Ha Yoon, M.D.

¹Department of Radiology, Wonkwang University College of Medicine

To our knowledge, rectal cancer arising at the anastomotic site after surgery for Hirschsprung's disease has not been reported. We report a case of mucinous adenocarcinoma arising at the anastomotic site after Soave operation 26 years ago.

Index words : Colon, aganglionosis
Colon, neoplasms

Address reprint requests to : Hyung Soo Kim, M.D., Department of Radiology, Wonkwang University, Kunpo Hospital, 1126-1 Sanbon-dong, Gunpo-si, Gyeonggi-do 435-040, Korea.
Tel. 82-31-390-2598 Fax. 82-31-390-2584 E-mail:khtvic@yahoo.co.kr