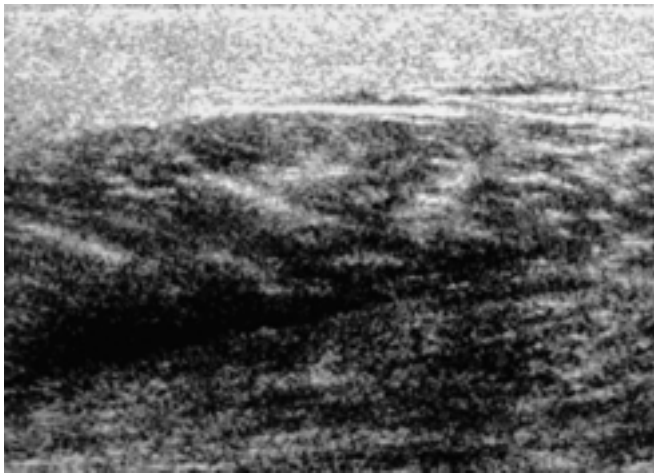


:
 : 6 11
 . 8 , 3
 5 2 , , ,
 , 4
 : 가 6 3 (50%), 2 - 7 cm
 가 4 (37%), 3 (28%), 2 (18%) , (9%)
 (9%) . 5 11 8 (73%)
 가 . 5 - 10
 8 6 (75%)
 (75%). 2 5 (20%)
 , 4 (80%)
 4
 :
 5 - 14

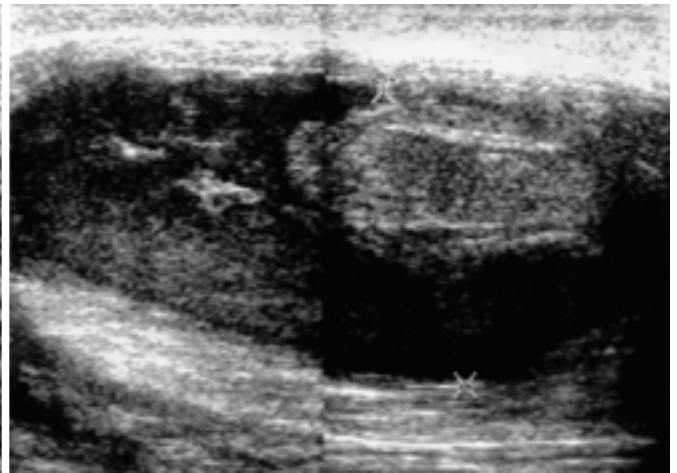
가
 , ,
 ,
 가
 1993 12 2001 12
 6 11
 ,
 3 , 가 3 . 6 4
 , , 4 12 8 .
 11 4 , 4
 ,
 3
 가 ,
 5 10 ,

Sequia 512 (Acuson, Sunnyvale, CA.,
 U.S.A.) HDI 3000 5000 (Advanced Technology
 Laboratories, Bothel, WA., U.S.A.) , 7 - 12 MHz

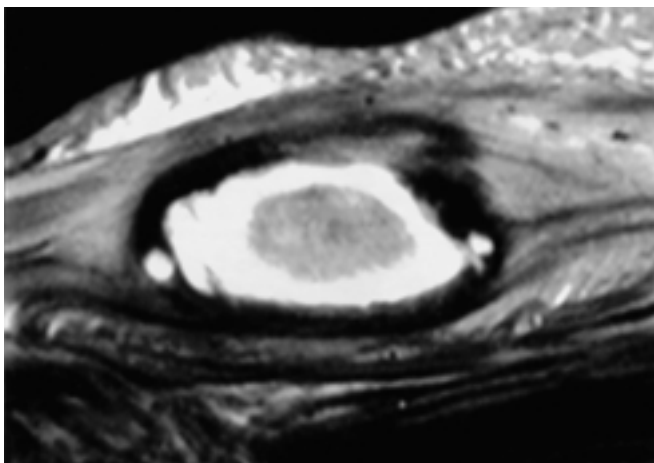
가 7 (64%)가
4 (36%)
2-7 cm
5 11 8 (73%)가
(Fig. 2A),
(Fig. 1A),
2 (18%)
(9%)
가
5-10 8 6 (75%)
(Fig. 1B). 2 (25%)
가 2 6
. 1-2 가 가 5
(28%), 2 (18%), 1 (9%)



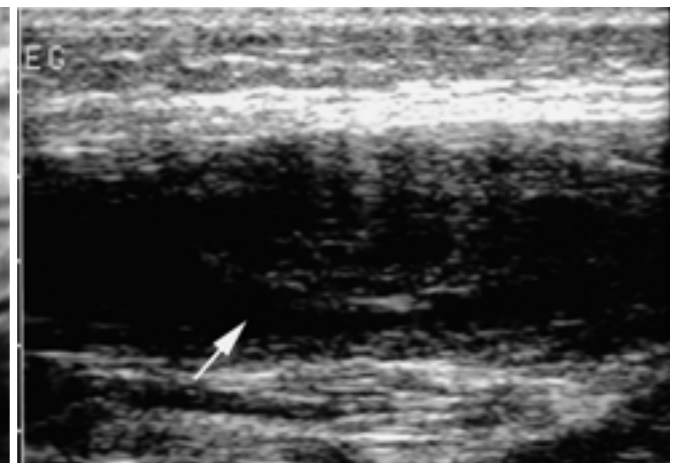
A



B



C



D

Fig. 1. A 7-year-old boy with acute myeloid leukemia.

A. Initial ultrasonography reveals diffuse swelling of left gastrocnemius muscle with illdefined hypoechoic lesions in muscle layer of left thigh with associating hyperechogenecity in subcutaneous fat layer.

B. Follow-up ultrasonography after 2 weeks shows a round central echogenic lesion surrounded by low echogenic lesion.

C. T2-weighted MR image shows a central, iso-signal intensity mass in cystic cavity representing hematoma.

D. Follow-up ultrasonography after 6 weeks reveals a remnant echogenic nodule (arrow) in previous cavitory lesion.

4
(Fig. 1D).

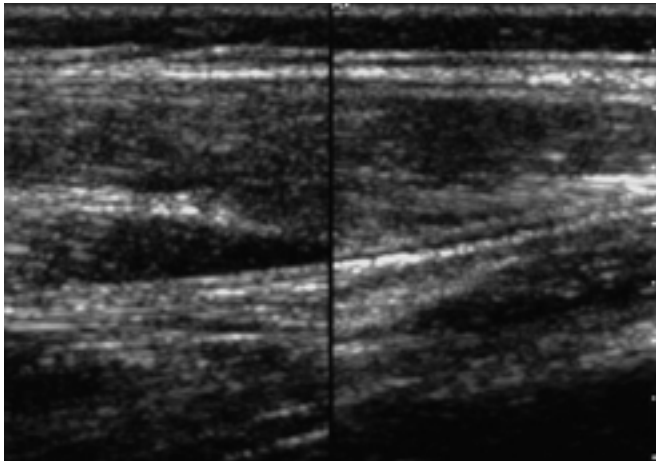
가 가 4
(Fig. 2C, D).

가 (2, 3).

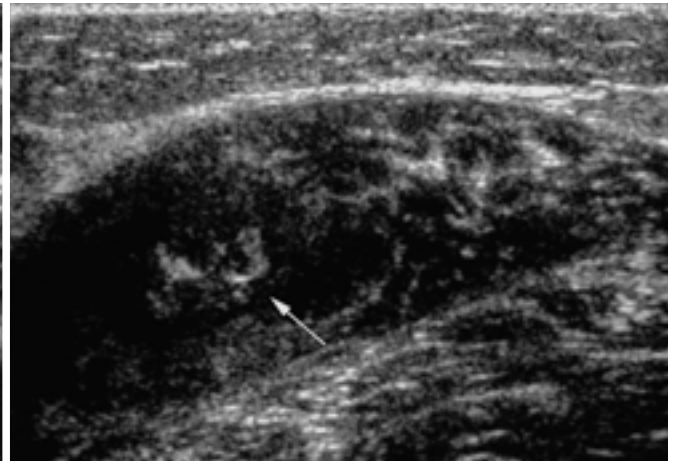
(4). 가

가 가 (1).

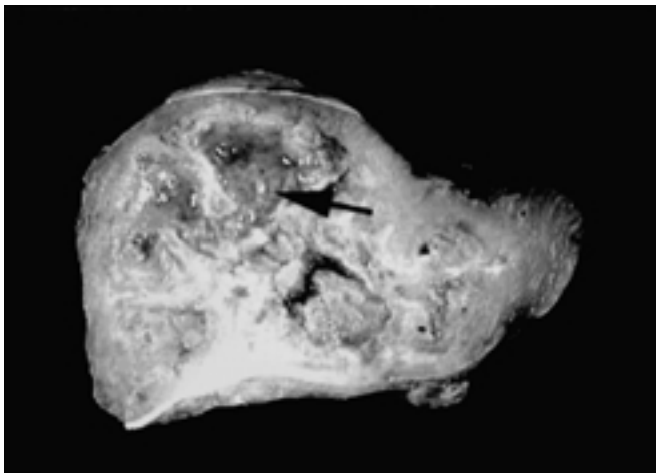
가 (5).



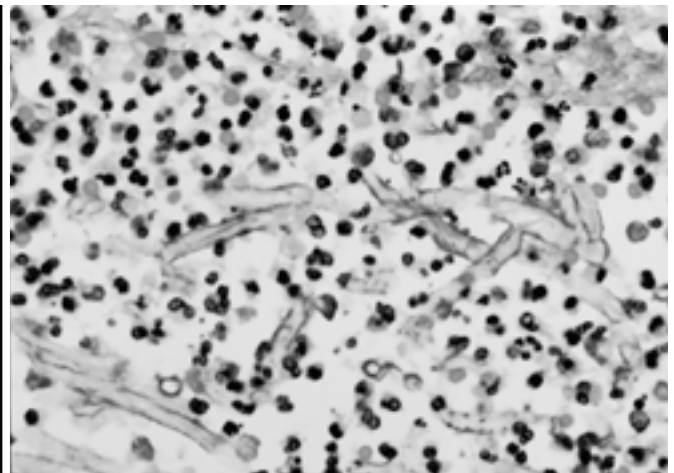
A



B



C



D

Fig. 2. A 12-year-old boy with acute myeloid leukemia.

A. Initial ultrasonography reveals diffuse swelling with low echogenicity of right gastrocnemius muscle.

B. Follow up ultrasonography after 2 weeks shows a central echogenic nodule (arrow) with surrounding hypoechoic muscle measuring about 2 × 1.5 cm.

C. A cross sectional image of excised specimen. The central hyperechoic lesion correlates with fungus ball (arrow) and surrounding hypoechoic lesions are muscle inflammation and necrosis.

D. Microscopic finding reveals necrotizing granulomatous inflammation with central fungal hyphae. The fungi consist acute branching hyphae with septation, which are morphologically consistent with of *aspergillus fumigatus*.

가 (3, 5, 8, 9). (10). (6). (10). CT MR (3). 가 (3). 3 . 5 가 , 5 - 14 1

1. Garcia J. MRI in inflammatory myopathies. *Skeletal Radiol* 2000;29:425-438
2. Beltran J. MR imaging of soft-tissue infection. *Magn Reson Imaging Clin N Am* 1995;3:743-751
3. Beauchamp NJ Jr, Scott WW, Gottlieb LM, Fishman EK. CT evaluation of soft tissue and muscle infection and inflammation: a systemic compartmental approach. *Skeletal Radiol* 1995;24:317-324
4. Johnston DL, Waldhausen JH, Park JR. Deep soft tissue infection in the neutropenic pediatric oncology patient. *J Pediatr Hematol Oncol* 2001;23:443-447
5. Loyer EM, DuBrow RA, David CL, Coan JD, Eftekhari F. Imaging of superficial soft-tissue infections: Sonographic findings in cases of cellulites and abscess. *AJR Am J Reontgenol* 1996;166:149-152
6. Cardinal E, Bureau NJ, Aubin B, Chhem RK. Role of ultrasound in musculoskeletal infections. *Radiol Clin North Am* 2001;39:191-201
7. Kang CM, Kim HS, Song KS, Lee HJ, Kwon KY. Localized muscular mucomycosis in a child with acute leukemia. *Jpn Clin Oncol* 1997;27:357-360
8. Chhem RK, Wang S, Jaovisidha S, et al. Imaging of fungal, viral and parasitic musculoskeletal and spinal disease. *Radiol Clin North Am* 2001;39:357-378
9. Kothari NA, Pelchovitz DJ, Meyer JS. Imaging of musculoskeletal infection. *Radiol Clin North Am* 2001;39:653-671
10. Swischuk LE. *Imaging of the Newborn, Infant and Young Child*. Williams & Willkins. 1997:873-875

Fungal Myositis in Children: Serial Ultrasonographic Findings¹

Jung Hwa Kwon, M.D., Hee Jung Lee, M.D., Jin Soo Choi, M.D.

¹Department of Radiology, Dongsan Medical Center, Keimyung University School of Medicine

Purpose: To evaluate serial ultrasonographic findings of fungal myositis in children.

Materials and Methods: Eleven lesions caused by fungal myositis and occurring in six children were included in this study. Eight lesions in five children were histopathologically proven and the other three were clinically diagnosed. Serial ultrasonographic findings were retrospectively evaluated in terms of size, location, margin, internal echotexture and adjacent cortical change occurring during the follow-up period ranging from five days to two months.

Results: Three patients (50%) had multiple lesions. The sites of involvement were the thigh ($n=4$), calf ($n=3$), chest wall ($n=2$), abdominal wall ($n=1$) and forearm ($n=1$). Initially, diffuse muscular swelling was revealed, with ill-defined hypoechoic lesions confined to the muscle layer ($n=8$). Follow-up examination of eight lesions over a period of 5 - 10 days showed that round central echogenic lesions were surrounded by previous slightly echogenic lesions ($n=6$, 75%). Long-term follow-up of five lesions over a two-month period revealed periosteal thickening in one case (20%), and the persistence of echogenic solid nodules in four (80%). Pathologic examination showed that the central lesions correlated with a fungus ball and the peripheral slightly echogenic lesions corresponded to hematoma and necrosis.

Conclusion: Serial ultrasonographic findings of fungal myositis in children revealed relatively constant features in each case. In particular, the findings of muscular necrosis and a fungus ball over a period of 5 - 14 days were thought to be characteristic.

Index words : Children, infections
Muscles, fungi
Ultrasound (US)

Address reprint requests to : Jung Hwa Kwon, M.D., Department of Radiology, Dongsan Medical Center,
194, Dongsan-dong, Joong-gu, Daegu 700-821, Korea.
Tel. 82-53-250-7767 Fax. 82-53-250-7766