

가 : 1

2

가

47

CT

가

가

가

가 (1).

6×5×3.7 cm

(2),

(1, 3).

(Fig. 3).

가

1

47

가 15

가

(Fig.

1)

CT

CT

4 - 5 cm

가

(Fig. 2A).

CT

10

(Fig.

2B).

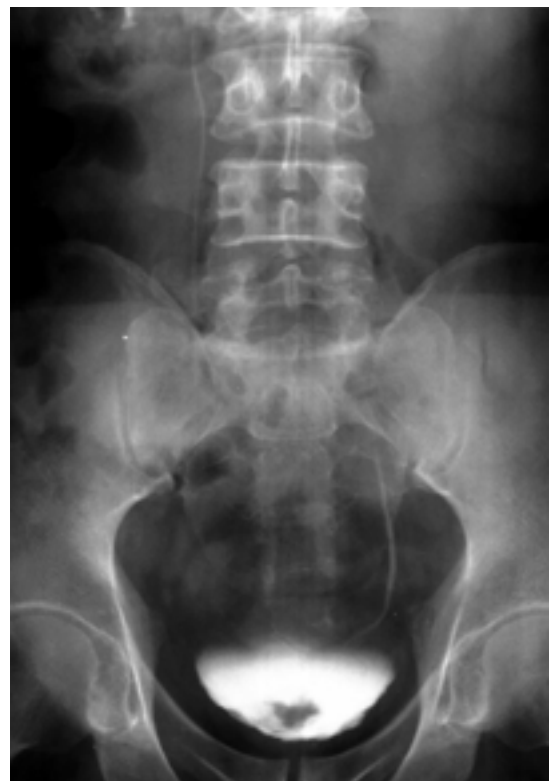

Fig. 1. IVP shows an intravesical triangular-filling defect.

(Fig. 4).

가 (pseudosarcoma), 가 (pseudosarcomatous fibromyxomatous tumor), (postoperative spindle cell nodule) (4).

가 (1).

, 가

가

Roth (5)

2

1

1980

가

2 - 73

(3).

가 가

(3).

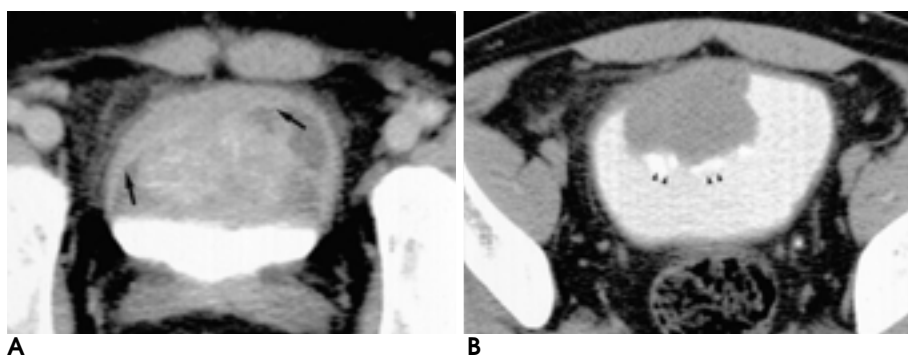
(6),

CT

가

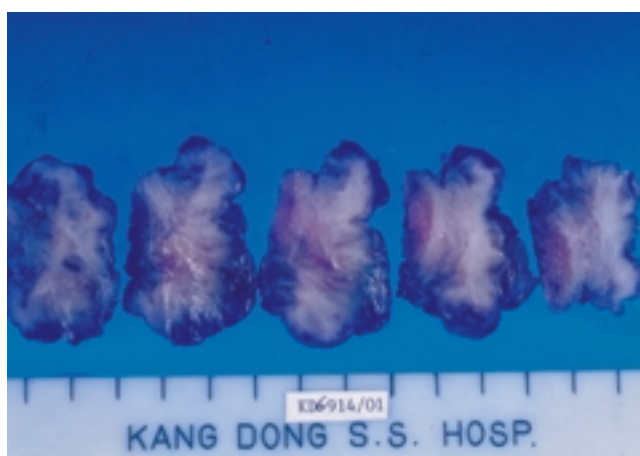
(6).

CT

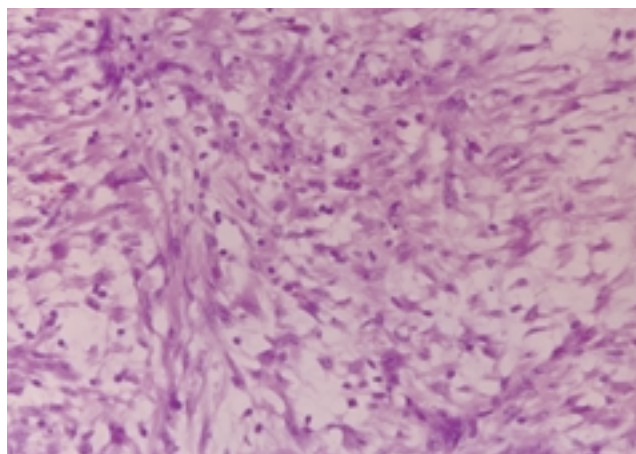


**Fig. 2. A.** Contrast-enhanced CT scan shows a polypoid intraluminal mass with marked enhancement arising from superior and anterior aspect of the bladder.

Note anterior wall thickening (arrows). **B.** Delayed-phase CT scan shows a lobulated mass with washout of contrast media. Dense nodules (arrowheads) are attached at the surface of the mass.



**Fig. 3.** An ulcerative polypoid tumor with fibrotic cut surface invades the muscle layer of the urinary bladder.



**Fig. 4.** The tumor is composed of haphazard arrangement of spindle cells and inflammatory cells are scattered in myxoid stroma (H & E stain, ×200).

가  
Toshitaka (1)  
T1 -  
가 T1 -  
가

- pseudotumor of the bladder: MR findings. *J Comput Assist Tomogr* 1999;23:558-561
2. Chen M, Lipson SA, Hricak H. MR imaging evaluation of benign mesenchymal tumors of the urinary bladder. *AJR Am J Roentgenol* 1997;168:399-403
3. Gugliada K, Nardi PM, Borenstein MS, Torno RB. Inflammatory pseudosarcoma (pseudotumor) of the bladder. *Radiology* 1991;179:66-68
4. Horn LC, Reuter S, Biesold M. Inflammatory pseudotumor of the ureter and the urinary bladder. *Pathol Res Pract* 1997;193:607-612
5. Roth JA. Reactive pseudosarcomatous response in urinary bladder. *Urology* 1980;16:635-637
6. Miki SC, Kwatra A, Kawashima A, Milam JD, Goldman SM, Sandler CM. Pseudosarcomatous fibromyxoid tumor of the bladder: biphasic contrast-enhanced helical CT findings. *J Comput Assist Tomogr* 1997;21:271-273

1. Fujiwara T, Sugimura K, Imaoka I, Igawa M. Inflammatory

J Korean Radiol Soc 2003;48:275 - 277

## Inflammatory Pseudotumor of the Bladder: Case Report<sup>1</sup>

Jeung Hee Moon, M.D., Eun Sook Nam, M.D.<sup>2</sup>

<sup>1</sup>Department of Radiology, Hallym University College of Medicine, Kangdong Sacred Heart Hospital

<sup>2</sup>Department of Pathology, Hallym University College of Medicine, Kangdong Sacred Heart Hospital

Inflammatory pseudotumor of the urinary bladder is a rare benign lesion. Because it is difficult to differentiate from other tumors clinically and pathologically, histopathologic confirmation is needed, and to avoid unnecessary cystectomy, it should be included in the differential diagnosis. A 47-year-old male presented with hematuria and voiding difficulty. IVP revealed a triangular filling defect in the urinary bladder, and CT demonstrated the presence there of a strongly enhancing mass. We describe this case, in which inflammatory pseudotumor was diagnosed, and review the literature.

**Index words :** Bladder

Inflammatory pseudotumor

Address reprint requests to : Jeung Hee Moon, M.D., Department of Radiology, Hallym University College of Medicine, Kangdong Sacred Heart Hospital, 445 Gil-dong, Gangdong-gu, Seoul 134-701, Korea.  
Tel. 82-2-2224-2312 Fax. 82-2-488-7370 E-mail: mjh3401@hanmail.net