

## Abdominal Aortic Pseudoaneurysm Caused by Lumbar Discectomy: Case Report<sup>1</sup>

Dong Hun Kim, M.D., Sang Won Yoon, M.D.<sup>2</sup>, Kyung Seuk Kim, M.D.<sup>3</sup>, Woo Hyuk Kim, M.D.<sup>3</sup>

Vascular injuries which occur during lumbar disk surgery, although rare, can give rise to potentially fatal complications which may be overlooked due to a broad range of clinical manifestations, and which surgeons and radiologists should be aware of. We report a recently encountered case of pseudoaneurysm of the abdominal aorta after lumbar disc surgery, and review the associated literature.

**Index words :** Lumbar, disc  
Vascular complication  
Aorta, pseudoaneurysm

Iatrogenic vascular injuries are unusual complications of lumbar disc surgery. Their incidence is very low but because clinical manifestations may be extremely variable depending on the extension of trauma, is probably underestimated (1 - 4). Vascular injury is suspected when early signs of retroperitoneal hemorrhage appear, but may often be delayed for weeks or years due to the formation of a pseudoaneurysm or arteriovenous fistula, which may be of gradual onset and give rise to few initial symptoms. Prompt diagnosis and aggressive treatment can improve the current mortality rate of more than 50% (1 - 3). We describe one case of acute hemorrhage and aortic pseudoaneurysm caused by lumbar disc surgery in a young man.

### Case Report

A 22-year-old man presented with back pain and progressive sensory disturbance, as well as right lower-ex-

tremity motor weakness. Plain radiography revealed no definite bony abnormality but magnetic resonance imaging (MRI) demonstrated herniation of the nucleus pulposus through an annular defect at the L3-4 and L5-S1 levels. Lumbar myelography indicated the presence of an extradural defect and edematous change in the right L4 nerve root, the sleeve of which was amputated by a herniated disc at the L5-S1 level. A decompressive procedure in which focal discectomy was performed via a right-sided posterior lumbar approach was undertaken, and after surgery the patient complained of diffuse abdominal pain. Although plain radiographs of the abdomen depicted no ileus, bilateral psoas lines were obliterated (Fig. 1A, B). Laboratory tests showed that hemoglobin concentration and the hematocrit level had fallen to 5.3 mmol/L and 0.25, respectively, and contrast-enhanced computed tomography (CT) of the abdomen and pelvis, performed because vascular injury was suspected, revealed that a pseudoaneurysm abutted the infrarenal abdominal aorta and that retroperitoneal hemorrhage had occurred (Fig. 1C). Angiography of the abdominal aorta demonstrated a 3 × 7 cm-sized aneurysmal sac to the right of the infrarenal abdominal aorta (Fig. 1D). The patient underwent emergency surgery during which a 3 × 7 cm-sized pseudoaneurysm was successfully resected by means of a prosthetic aortic

<sup>1</sup>Department of Radiology, Armed Forces Kwang Ju Hospital

<sup>2</sup>Department of Neurologic Surgery, Armed Forces Kwang Ju Hospital

<sup>3</sup>Department of General Surgery, Armed Forces Kwang Ju Hospital

Received May 8, 2002 ; Accepted August 21, 2002

Address reprint requests to : Dong Hun Kim, M.D., Department of Radiology, Armed Forces Kwang Ju Hospital, 66 Hwajeong-dong, Seo-gu, Kwangju 502-240, Korea.

Tel. 82-62-390-5129 Fax. 82-62-381-3946

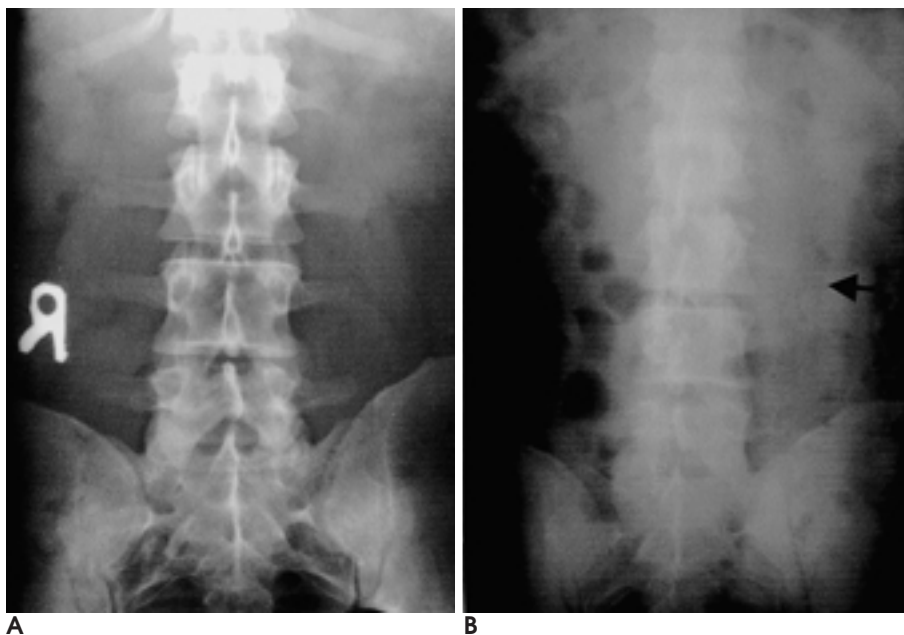
graft. After the procedure, the abdominal pain disappeared.

### Discussion

Vascular injuries are associated with vessel mobilization and retraction or laceration during spinal surgery which necessitates direct repair (1 - 2). The anatomical location at which spinal procedures are performed may also relate to the type of vascular injury involved. The most common of these is tearing of the left common iliac artery, which lies immediately anterior to the fourth lumbar intervertebral disc and is thus particularly vulnerable. Although the actual incidences of arteriovenous fistula, pseudoaneurysm and hemorrhage have not been published, a few isolated case reports have appeared (3 - 4).

Pseudoaneurysm is the least common sequela of vascular injury. Aortic pseudoaneurysm can manifest within the first few days or weeks of surgery, but may also remain clinically obscure for years. Occasionally, abdominal examination reveals a pulsating mass (1). The detailed cause of this is not clear, but a possible mechanism is that the outer layer of the aorta is injured prior to herniation of the aortic intima.

Predisposing factors which increase the risk of vascular injury include degeneration or a defect of the fibrous annulus or anterior longitudinal ligament, persistent adhesion of the prevertebral structures to the anterior longitudinal ligament, and difficult operative conditions such as reoperations, aggressive exploration, and complex patient positioning (5). Vascular tortuosity of the aorta and iliac arteries can increase significantly with



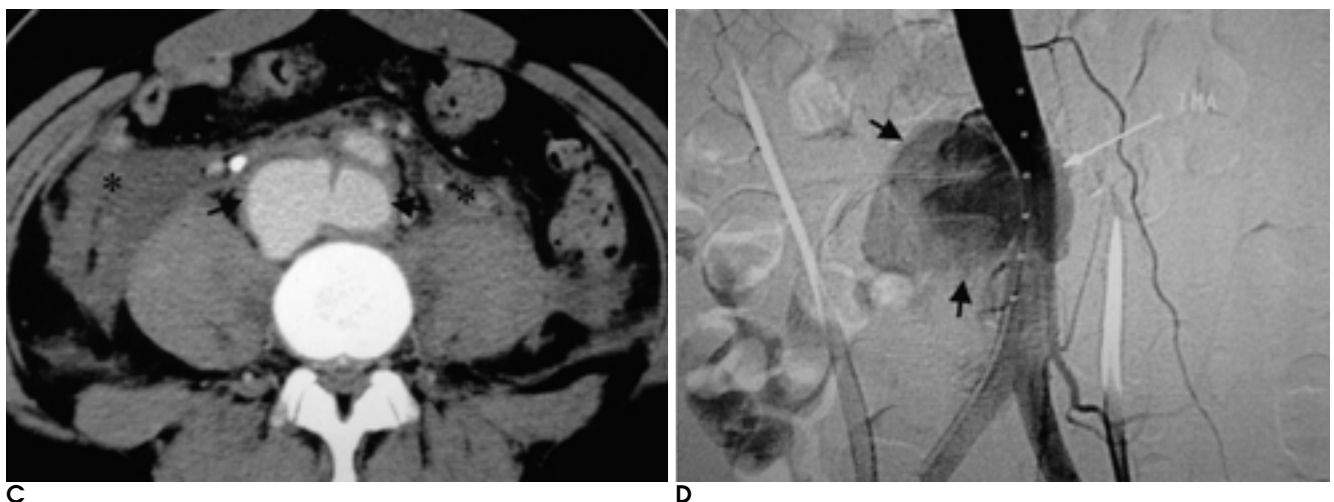
**Fig. 1.** A 22-year-old man with abdominal aortic pseudoaneurysm.

**A.** Preoperative plain radiograph represents no abnormality.

**B.** Postoperative plain radiograph shows definite obliteration of bilateral psoas lines (arrows).

**C.** Abdominal CT scan with contrast enhancement demonstrates saccular pseudoaneurysm (arrows) and retroperitoneal hemorrhage (asterisks).

**D.** Aortogram shows typical saccular aneurysm (arrows) in the right lateral wall of infrarenal abdominal aorta. There is inferior mesenteric artery (IMA) adjacent to aneurysm but IMA is intact.



age, and may affect the degree of retraction needed to expose the spinal column.

Arterial complications are more likely to cause hemodynamic instability, which is evidenced initially by tachycardia and subsequently by hypotension. The clinical course may vary and can be divided into acute and chronic stages (2, 6 - 7). Acute symptoms or signs result from excessive blood loss secondary to intra-abdominal or retroperitoneal bleeding, with or without shock. Sudden onset, such as that occurring in our case, is most often attributed to isolated laceration of a great artery, which carries a mortality rate as high as 80% (8).

The sudden onset of pain or hemodynamic instability should prompt evaluation, which should include the assessment of vital signs and hematocrit levels, electrocardiography, and CT scanning of the surgically treated region. The most immediate life-threatening cause or causes can thus be determined. In acute cases, angiography is required, as it is specific and precise and defines vascular topography and location and the size of the lesion prior to preoperative appraisal. As it provides more detailed information about the relationship of injured vessels to surrounding hematoma, critical organs, and bones, CT is the preferred method for investigating complications in patients in whom the onset of symptoms is subacute or chronic (9). In our case, we overlooked the obliteration of bilateral psoas lines, which might have been an important indicator of a retroperitoneal or intraperitoneal lesion. However, a CT image obtained after the injection of contrast medium had the

exact appearance of an aortic pseudoaneurysm.

In conclusion, although vascular complications of spinal surgery are uncommon, the potential risk must be borne in mind, and meticulous care taken to avoid them. The radiologist should help the surgeon to rapidly and correctly establish the diagnosis and the surgical intervention required.

## References

1. Fruhwirth J, Koch G, Amann W, Hauser H, Flaschka G. Vascular complications of lumbar disc surgery. *Acta Neurochir* 1996;138(8):912-916
2. Szolar DH, Preidler KW, Steiner H, et al. Vascular complications in lumbar disk surgery: report of four cases. *Neuroradiology* 1996;38(6):521-525
3. Tanaka M, Nakahara S, Tanizaki M. Aortic pseudoaneurysm in the L3-L4 disc space after lumbar disc surgery. A case report. *J Bone Joint Surg Br* 1998;80(3):448-451
4. Franzini M, Altana P, Annessi V, Lodini V. Iatrogenic vascular injuries following lumbar disc surgery. Case report and review of the literature. *J Cardiovasc Surg* 1987;28:727-730
5. Oskouian RJ Jr, Johnson JP. Vascular complications in anterior thoracolumbar spinal reconstruction. *J Neurosurg* 2002;96(1):1-5
6. Ohnishi T, Neo M, Matsushita M, Komeda M, Koyama T, Nakamura T. Delayed aortic rupture caused by an implanted anterior spinal device. Case report. *J Neurosurg* 2001;95(2Suppl):253-256
7. Jenis LG, Leclair WJ. Late vascular complication with anterior cervical discectomy and fusion. *Spine* 1994;19(11):1291-1293
8. Smith DW, Lawrence BD. Vascular complications of lumbar decompression, laminectomy and foraminotomy. A unique case and review of the literature. *Spine* 1991;16:387-390
9. Novelline RA, Rhea JT, Rao PM, Stuk JL. Helical CT in emergency radiology. *Radiology* 1999;213(2):321-339

2003;48:91 - 93

가 : 1

1

2

3

· 2 · 3 · 3

가