

Unilateral Hyperlucency of the Lung: A Systematic Approach to Accurate Radiographic Interpretation¹

Hyung-Jun Noh, M.D., Yu-Whan Oh, M.D., Eun-Jeong Choi, M.D., Bo-Kyung Seo, M.D.,
Kyu-Ran Cho, M.D., Eun-Young Kang, M.D., Jung Hyuk Kim, M.D.

The radiographic appearance of a unilateral hyperlucent lung is related to various conditions, the accurate radiographic interpretation of which requires a structured approach as well as an awareness of the spectrum of these entities. Firstly, it is important to determine whether a hyperlucent hemithorax is associated with artifacts resulting from rotation of the patient, grid cutoff, or the heel effect. The second step is to determine whether or not a hyperlucent lung is abnormal. Lung that is in fact normal may appear hyperlucent because of diffusely increased opacity of the opposite hemithorax. Thirdly, thoracic wall and soft tissue abnormalities such as mastectomy or Poland syndrome may cause hyperlucency. Lastly, abnormalities of lung parenchyma may result in hyperlucency. Lung abnormalities can be divided into two groups: a) obstructive or compensatory hyperinflation; and b) reduced vascular perfusion of the lung due to congenital or acquired vascular abnormalities. In this article, we describe and illustrate the imaging spectrum of these causes and outline a structured approach to accurate radiographic interpretation.

Index words : Lung, abnormalities

Lung, density

Lung, diseases

Lung, radiography

Thorax, radiography

In daily practice, cases in which a unilateral hyperlucent hemithorax is seen at frontal chest radiography are often encountered. Because such an abnormality is related to various conditions, including radiographic artifacts, chest wall abnormalities, pulmonary vascular disorders with reduced perfusion, and lung parenchymal abnormalities with air trapping or compensatory over-

expansion, a radiographic finding of increased radiolucency involving one hemithorax may give rise to difficulties in differential diagnosis. The accurate radiographic interpretation of unilateral hyperlucency therefore requires an awareness of the spectrum of these causes. The various conditions can be grouped on the basis of their underlying mechanisms and radiographic features, and according to our experience, an approach that reflects this is useful for their evaluation and differentiation.

In this pictorial essay, we present the imaging spectrum of the conditions causing unilateral hyperlucent hemithorax, emphasizing the importance of a systematic approach to the radiographic interpretation of the re-

¹Department of Diagnostic Radiology, College of Medicine and Medical Science Research Center, Korea University
Supported by grant 1999-309 from the Korea University Medical Science Research Center

Received November 22, 2002 ; Accepted December 4, 2002

Address reprint requests to : Yu-Whan Oh, M.D., Department of Diagnostic Radiology, Korea University Anam Hospital, 126-1, 5-Ka, Anam-dong, Sungbuk-gu, Seoul 136-705, South Korea.

Tel. 82-2-920-5657 Fax. 82-2-929-3796 E-mail: yuwhan@kumc.or.kr

lated findings.

Radiographic Artifacts

The first step in the evaluation of unilateral hyperlucency of the lung is to check for the presence of a radiographic artifact. Those that simulate unilateral hyperlucency include rotation of the patient, grid cutoff, and the heel effect. The radiologic technique employed may result in differential blackening of the two hemithoraces when a patient is rotated (1). The side to which the patient is rotated is more radiolucent because soft tissues project over one side of the chest while being rotated off the opposite side (Figs. 1, 2). The artifact secondary to rotation is independent of the projection, which may be a posteroanterior or anteroposterior. This situation is particularly apparent in women with large breasts that are projected over the lower hemithorax as additional radiopacity.

The radiographic grid used for removing scatter radiation may cause uneven attenuation of primary radiation as a result of the mismatched geometry between the primary beam and the lead strips of the grid. Among four situations producing grid cutoff, combined cutoff due to lateral and focus-grid distance decentering causes unequal exposure, resulting in a film that

is light on one side and dark on the other (Figs. 3, 4) (2).

The intensity of film exposure on the anode side of the x-ray tube is significantly less than that on the cathode side: the angled anode target itself absorbs some of the x-ray photons emitted almost parallel to the surface of the angled target (Fig. 5) (3). This variation is known as the heel effect, normally used to obtain balanced densities in radiographs of the chest with vertically different thicknesses. If two electrodes (anode and cathode) of the

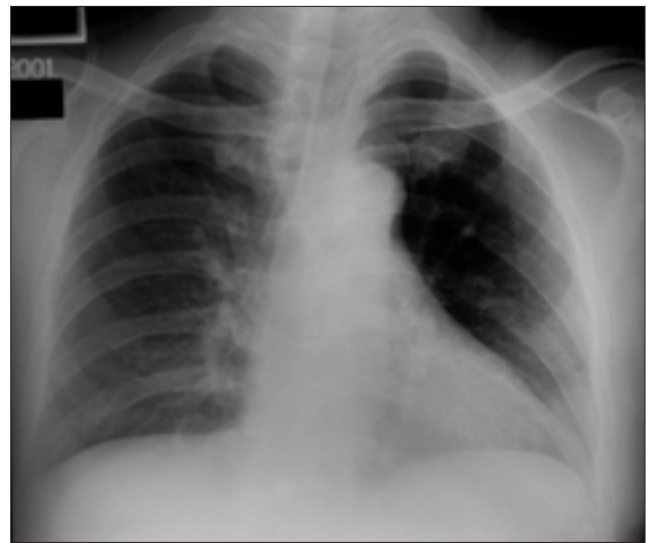


Fig. 2. Radiographic artifact resulting from the rotation of a patient. Chest radiograph taken with a patient who is slightly rotated to the left shows a hyperlucent left lung.

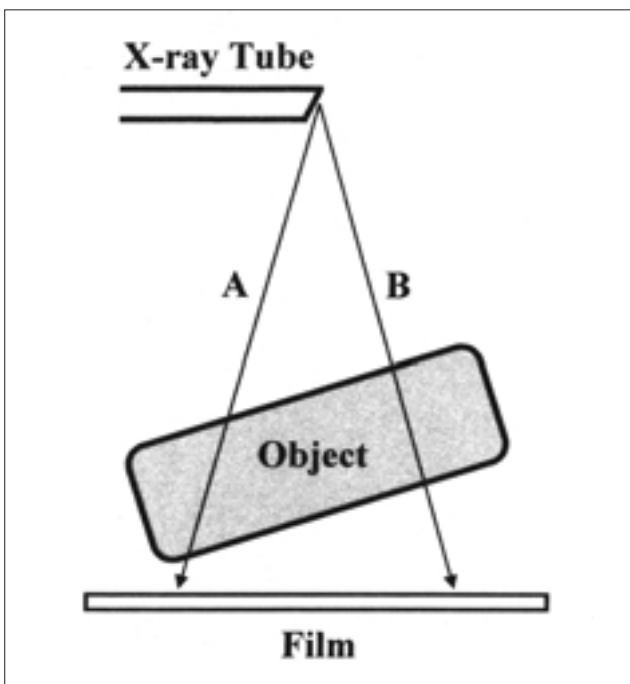


Fig. 1. Changes in radiographic transmission with rotation. X-ray beam in A direction traverses a longer path through the object, and thus is more attenuated than that in B direction.

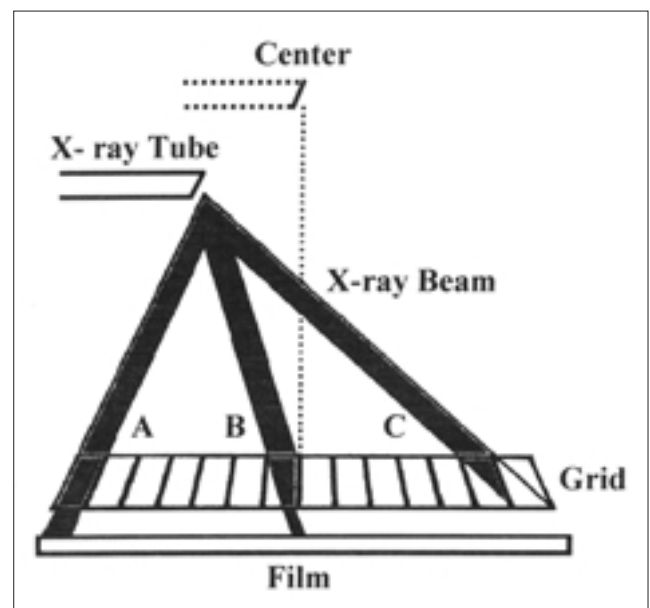


Fig. 3. Grid cutoff resulting from combined lateral and focus-grid distance decentering. There is a large loss of primary radiation on one side of film (C) in comparison with the other side (A).

x-ray tube are horizontally oriented across the thorax, the heel effect may cause one hemithorax to appear more lucent than the other.

In cases involving these radiographic artifacts, there is

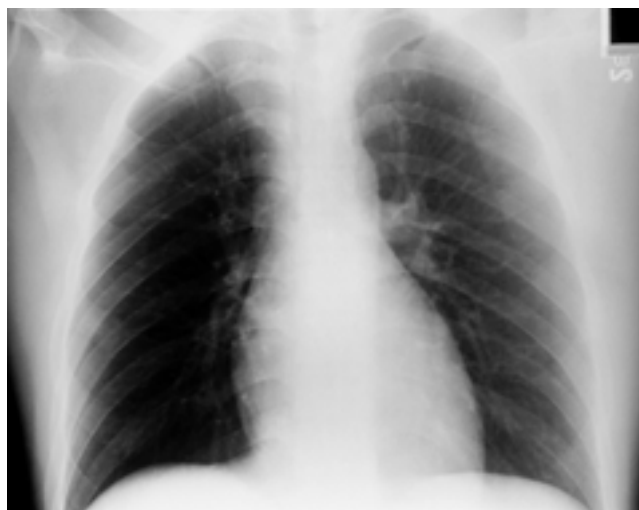

Fig. 4. A 22-year-old man with acute lymphoblastic lymphoma. Portable chest radiograph shows different radiographic densities between two sides of entire film. All of the scapula, ribs, soft tissue, and lung on the right side are more radiolucent as compared to those on the left.

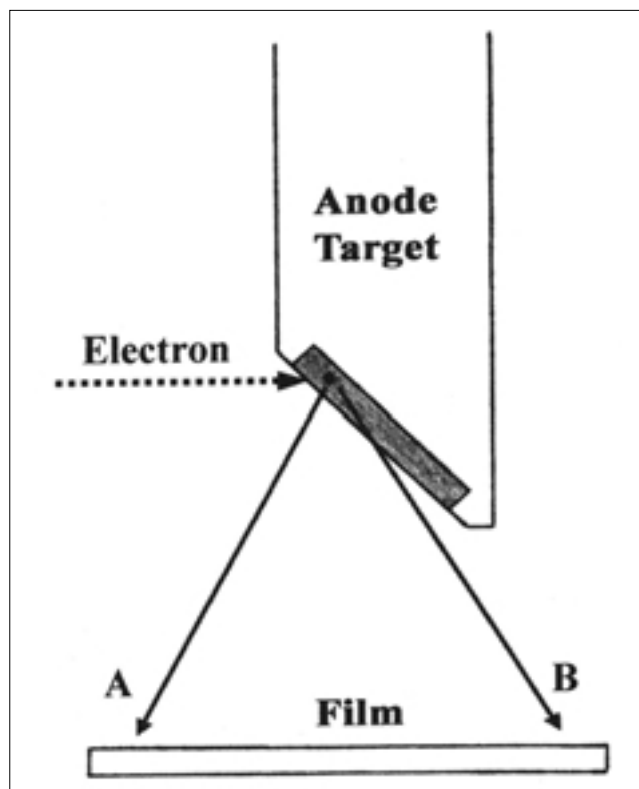


Fig. 5. Heel effect. Intensity of x-ray photons emerging in B direction is more attenuated due to absorption of some photons by anode target itself than that in A direction.

a difference in radiographic density between the two sides of the entire film, not just between the two lungs. The reason for unilateral hyperlucency is, then, technical rather than pathologic, and in order to recognize this, the relative exposure of soft tissues, especially around the shoulder girdles, should be compared.

Whether Hyperlucent or Radiodense Lung Is Abnormal

After excluding radiographic artifacts, the diagnostic approach to a unilateral hyperlucent lung requires the determination of whether the hyperlucency or radiodensity observed is, in fact, abnormal. Mild diffuse increased opacity of one hemithorax may falsely suggest that the opposite normal lung is pathologically hyperlucent (Fig. 6). The best-known example is a patient in the supine position in whom a large pleural effusion extends posteriorly in layers. In such cases, other radiographic signs of pleural effusion are helpful in deciding that the relatively radiodense hemithorax is abnormal: capping of the lung apex, blunting of the costophrenic angle, loss of the sharp silhouette of the ipsilateral hemidiaphragm, a bandlike opacity separating the lateral lung margin from the chest wall, and thickening of the minor fissure (4). Occasionally, a similar situation may result from the diffuse swelling of unilateral chest wall or slight volume loss in an entire lung or lobe due to sputum plugs (Fig. 7). The latter can be observed particularly in postopera-

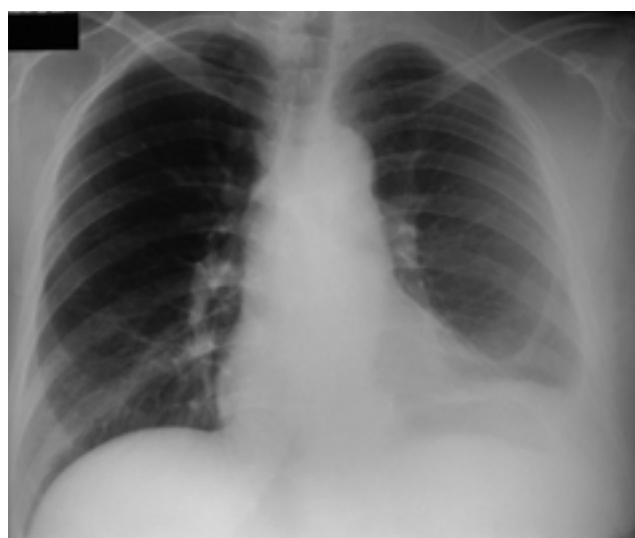

Fig. 6. A 49-year-old woman with left pleural effusion secondary to tuberculous pleurisy. Chest radiograph shows hazy opacification of left hemithorax with preserved vascular markings. Note apical capping, blunting of costophrenic angle, loss of hemidiaphragmatic silhouette in left hemithorax.

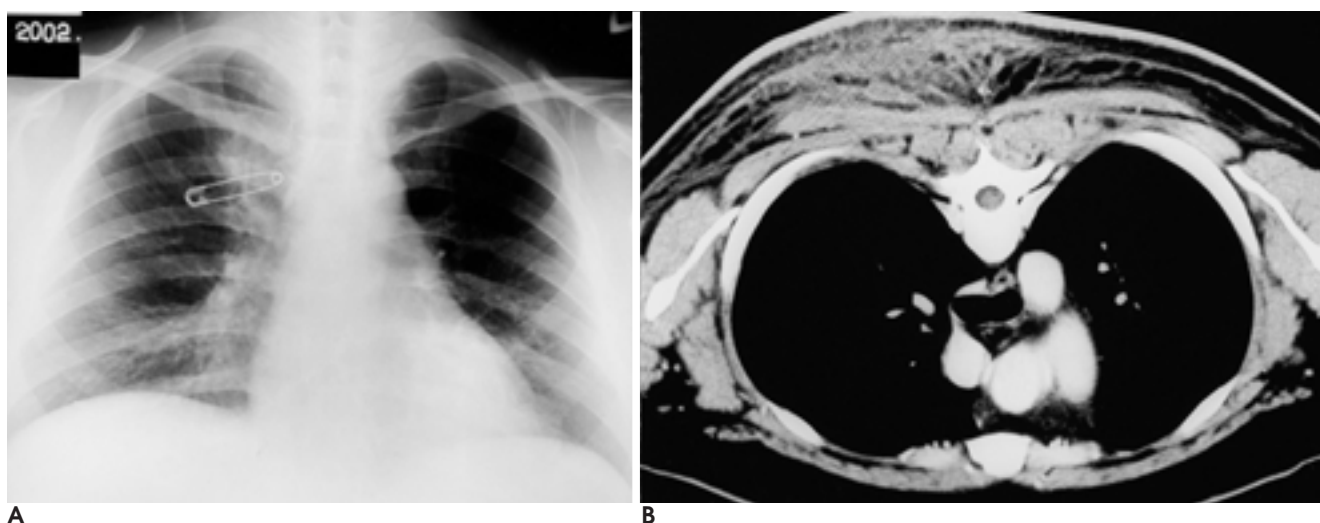


Fig. 7. A 25-year-old man with cellulitis in posterior chest wall.

A. Chest radiograph shows a diffusely increased radiopacity in right hemithorax. The left hemithorax appears relatively radiolucent. A safety pin is seen over right hemithorax.

B. Chest CT scan with the patient positioned prone shows a diffuse swelling in posterior chest wall, especially the right side. Ill-defined areas of increased attenuation are seen in thickened subcutaneous fat plane of posterior chest wall.

tive patients or in those in an intensive care unit.

Chest Wall Abnormalities

The third step in the assessment of unilateral hyperlucent lung is to determine whether or not the thoracic wall is abnormal. Asymmetric chest wall and soft tissue abnormalities, though very obvious to the clinician, may be overlooked by a radiologist who is unaware of them. The most common cause of such abnormalities is radical mastectomy, performed because of breast cancer (Fig. 8). Rarely, a congenital defect of the pectoral muscles (Poland syndrome) can likewise result in a unilateral hyperlucent lung (5). In addition, individuals involved in certain occupations, such as butchers and carpenters, may have asymmetric chest wall musculature that can lead to differences in radiographic density between the two hemithoraces. In these cases, the normal branching pulmonary vascularity of both lungs indicates that the explanation for a unilateral hyperlucent lung is asymmetry of soft tissues rather than true hyperlucency.

Abnormalities of Lung Parenchyma

When the various above-mentioned conditions are excluded, the remaining causes of unilateral lung hyperlucency are associated with abnormalities of lung parenchyma. The radiographic density of the lung is influenced by the complex interplay between air, blood,

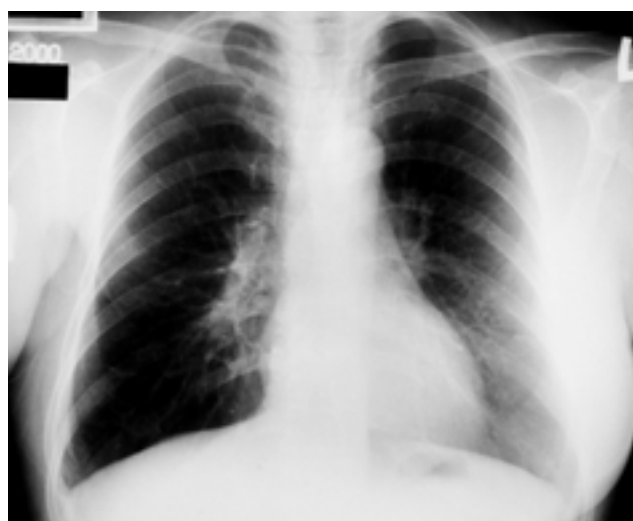

Fig. 8. A 56-year-old woman who underwent mastectomy for right breast cancer. Chest radiograph shows a hyperlucent right lung. Normal shadow of right breast is not present.

and interstitial tissue. Two of these elements—air and blood volume—are the most important parameters with regard to the hyperlucent lung; that is, hyperlucency usually results from an increase in the volume of air or decrease in the volume of blood in the lung, or a combination of both mechanisms (6).

Increase in the Volume of Pulmonary Air

The amount of air within lung parenchyma may increase as a result of either air trapping or compensatory hyperinflation of the lung. A unilateral hyperlucent lung

occurring in association with air trapping (obstructive hyperinflation) is present in various conditions: foreign body aspiration, inflammatory bronchial strictures, endobronchial tumors, congenital lobar emphysema, bronchial atresia, Swyer-James syndrome, unilateral bullous emphysema or cystic lung diseases, and extrinsic bronchial compression due to mediastinal lesions (7 - 13). The common radiographic finding of these conditions is a hyperlucent lung, with spreading and narrowing of the pulmonary vessels (Fig. 9). The volume of the affected lung varies, and may be the equivalent of a lung which is small, of normal size, or enlarged. Where lung volume is large, as in cases of congenital lobar emphysema, bronchial atresia, and bullous emphysema, for example, the mediastinum shifts toward the con-

tralateral side (Fig. 10). The characteristic radiologic feature of obstructive hyperinflation is the presence of air trapping during expiration: chest radiography reveals no appreciable change in the volume of the affected lung at full expiration, whereas the contralateral normal lung decreases in volume (Fig. 9). This radiographic finding is very valuable in distinguishing these disorders from other conditions resulting in a unilateral hyperlucent lung.

When a lobe becomes atelectatic or is resected, the remaining lobe hyperexpands by way of compensation, and at chest radiography this is marked by the presence of a small or normal-sized hyperlucent lung, spreading of the vascular markings, and displacement of the ipsilateral hilum (Fig. 11). If lobar atelectasis, notably of the left lower lobe, is chronic and extreme, the atelectatic

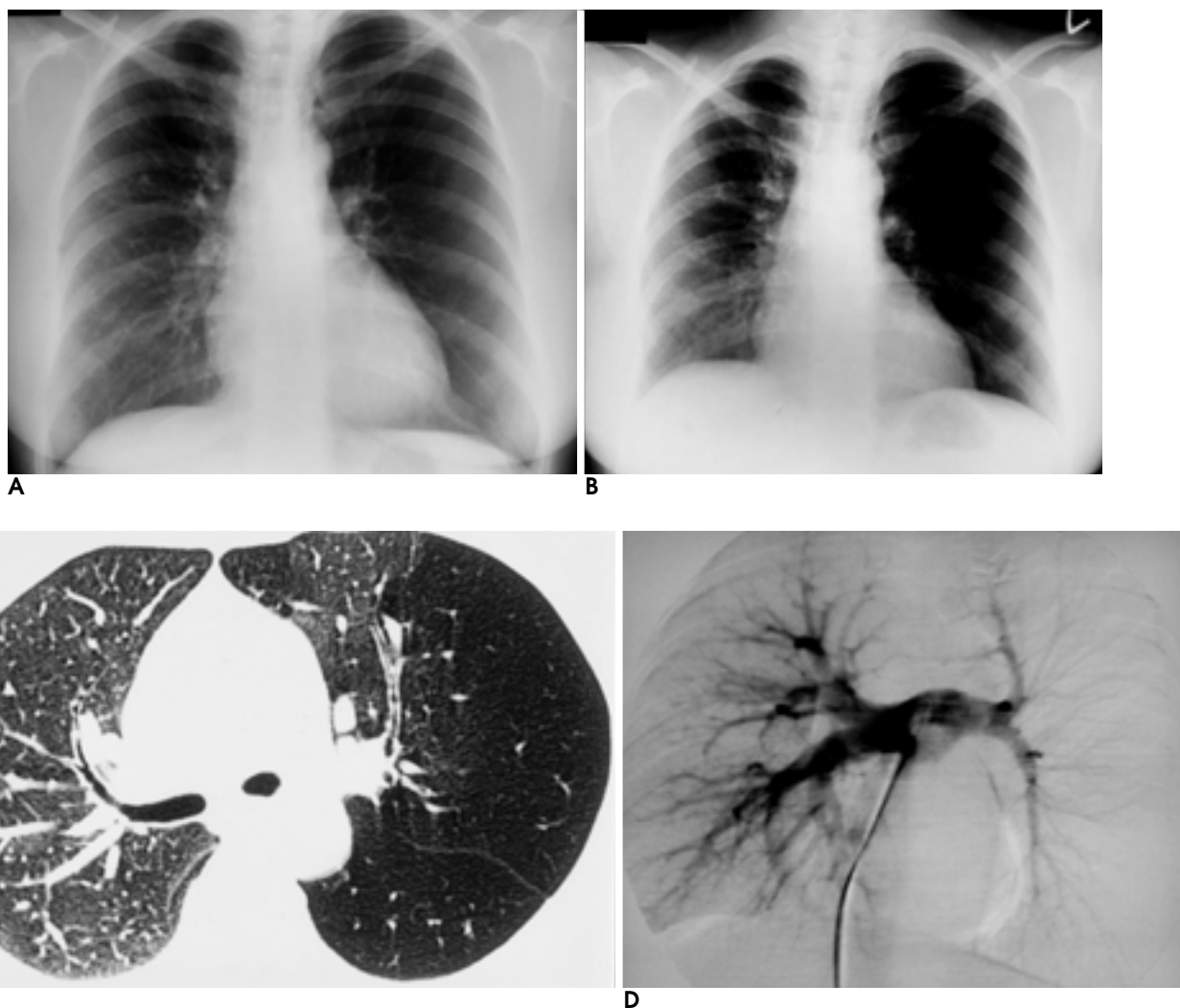


Fig. 9. A 44-year-old woman with Swyer-James syndrome.

A. Chest radiograph in full inspiration shows a hyperlucent left lung with markedly decreased vascular markings.

B. Expiratory radiograph shows no reduction of left lung volume in comparison with right lung.

C. Thin-section CT obtained at level of left main bronchus shows large area of low attenuation in left upper and lower lobes.

D. Pulmonary angiogram shows reduced size and number of pulmonary vessels to the left lung.

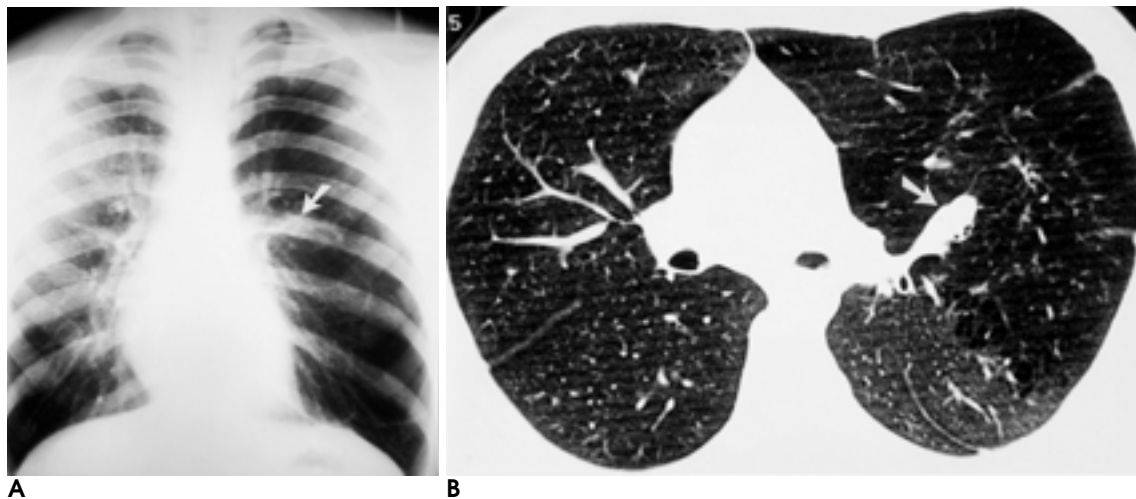


Fig. 10. A 21-year-old man with congenital bronchial atresia.

A. Chest radiograph shows a hyperlucent left lung with increased lung volume. Soft tissue opacity (arrow) is seen adjacent to the left hilum. The mediastinum is shifted to the right side.

B. Thin-section CT shows mucoid impaction (arrow) in anterior segmental bronchus of left upper lobe that is seen as soft tissue opacity on plain radiograph. Large areas of left upper lobe are overinflated and hypovascular.

lobe may be inconspicuous because it is wedged against the mediastinum and is often hidden by the heart (14). In contrast to obstructive hyperinflation, an expiratory radiograph depicts a normal decrease in the volume of the hyperinflated lung.

Decreased Pulmonary Blood Volume

Considerable reduced vascular perfusion in one lung may give rise to hyperlucency of that lung at chest radiography. The disorders involved are either congenital or acquired; the former, which cause diminished vascular perfusion in one lung, are rare and include aplasia of a pulmonary artery (its proximal interruption) and pulmonary hypoplasia (15,16). These two conditions are radiographically characterized by a reduction in the volume of the hyperlucent lung, a small hilum, poor vascularization, and ipsilateral shift of the mediastinum (Fig. 12). The pulmonary vascularity of the affected lung is markedly reduced and atypical because blood supply to all or part of the lung is provided by systemic collateral vessels arising from the aorta. In addition, an anomalous pulmonary vein draining into the inferior vena cava may be seen in cases of hypoplasia of the right lung the scimitar sign in hypogenetic lung syndrome. The radiologic findings of proximal pulmonary artery interruption may mimic those of Swyer-James syndrome. However, a chest radiograph obtained at full expiration usually serves to differentiate between the two disorders. In contrast to Swyer-James syndrome, air trapping is absent where the proximal pulmonary artery is inter-

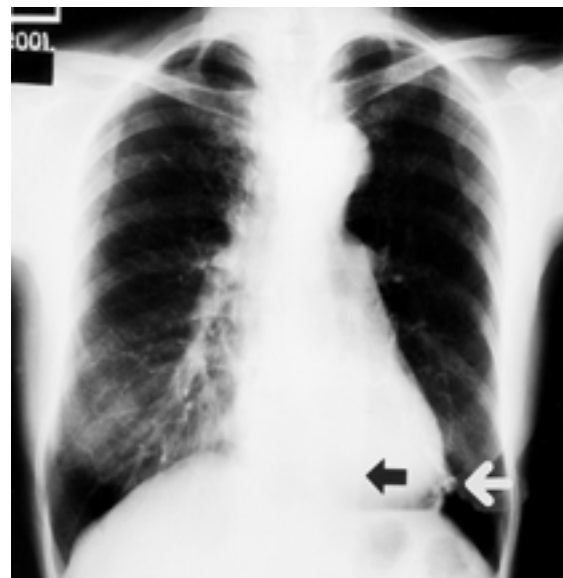


Fig. 11. A 60-year-old woman who has endobronchial tuberculosis causing left lower lobe atelectasis. Chest radiograph shows collapsed left lower lobe (black arrow) behind the heart and downward displacement of left hilum. The hyperlucency of left lung is caused by compensatory expansion of left upper lobe that results in spreading of the pulmonary vessels so that there are fewer vessels per unit volume. Calcified small granulomas (white arrow) are noted in left lower lung zone.

rupted.

Acquired disorders include pulmonary thromboembolism, fibrosing mediastinitis, sequelae of mediastinal irradiation, and mediastinal or hilar tumors (17 - 19). In these cases, either intrinsic or extrinsic pulmonary arterial obstruction may result in marked diminution of arte-

rial blood perfusion. The affected lung is manifested by a radiographically abnormal unilateral hyperlucent lung, with no evidence of air trapping on both inspiratory and expiratory radiographs. In contrast to congenital disorders, the affected lung in acquired vascular disorders is of normal size and the ipsilateral hilum is either of normal size or enlarged (Fig. 13).

chest wall abnormalities, and pulmonary vascular and parenchymal disorders are associated with the radiographic appearance of a unilateral hyperlucent lung. In patients in whom this is observed, accurate radiographic interpretation requires both a structured approach and awareness of the radiographic spectrum of these conditions (Fig. 14).

Summary

Various conditions including radiographic artifacts,

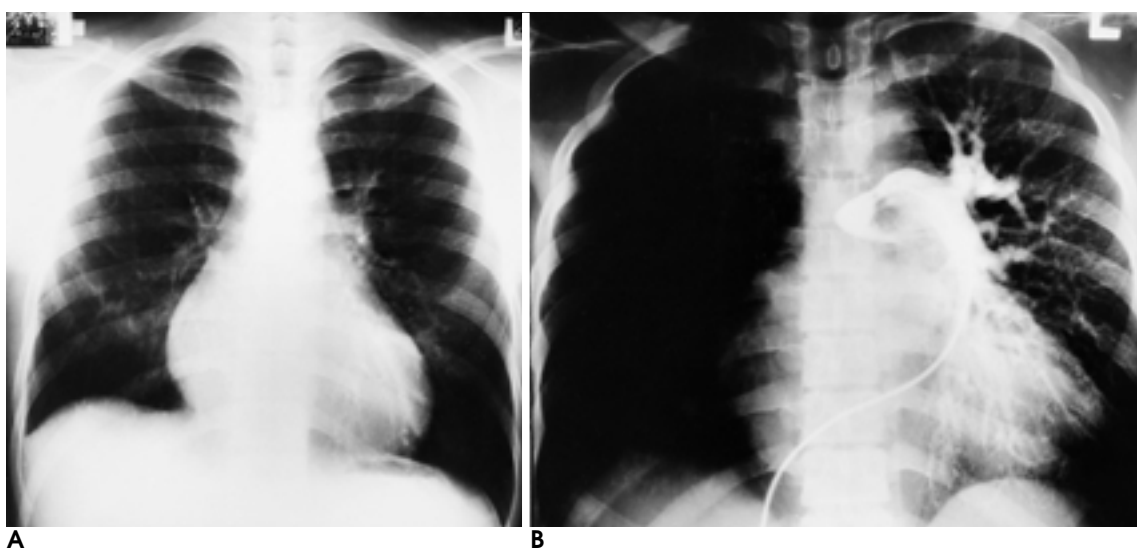


Fig. 12. A 20-year-old man with aplasia of right pulmonary artery.

- A.** Chest radiograph shows reduced volume of right lung with a small hilum. Note decreased and atypical pulmonary vascularity of right lung.
- B.** Pulmonary angiogram shows complete absence of right pulmonary artery.

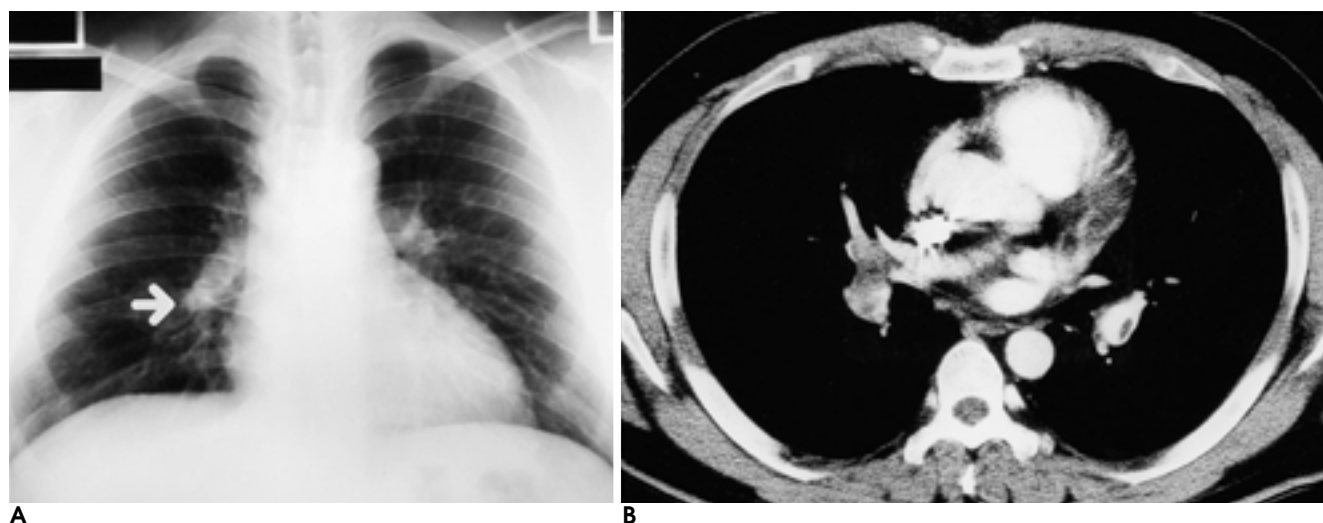


Fig. 13. A 35-year-old man with pulmonary thromboembolism.

- A.** Chest radiograph shows a hyperlucent right lung and abrupt tapering of right lower lobar pulmonary artery (arrow).
- B.** Contrast-enhanced CT scan shows thromboembolism in bilateral pulmonary arteries with right one involved more severely.

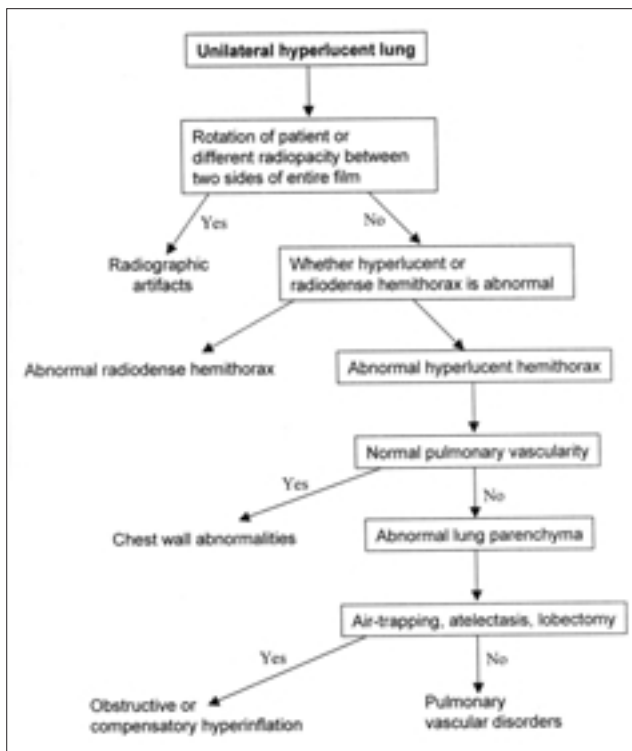


Fig. 14. Algorithm depicting radiologic approach to unilateral hyperlucent lung.

References

1. Joseph AE, de Lacey GJ, Bryant TH, Stoker DJ, Ayr G. The hypertransradiant hemithorax: the importance of lateral decentering, and the explanation for its appearance due to rotation. *Clin Radiol* 1978;29:125-131
2. Curry TS, Dowdey JS, Murry RC. *Christensen's physics of diagnostic radiology*, 4th ed. Malvern: Lea & Febiger, 1990:99-117
3. Wolbarst AB. *Physics of radiology*. Norwalk: Appleton & Lange, 1993: 94-102
4. Wilson AG. Pleura and pleural disorders. In: Armstrong P, Wilson AG, Dee P, Hansell DM, eds. *Imaging of diseases of the chest*. 2nd ed. St. Louis: Mosby, 1995: 641-716
5. Pearl M, Chow TF, Friedman E. Poland's syndrome. *Radiology* 1971; 101: 619-623
6. Remy-Jardin M, Remy J, Giraud F, Watinne L, Gosselin B. Computed tomography assessment of ground-glass opacity: semiology and significance. *J Thorac Imaging* 1993; 8: 249-64
7. Blazer S, Naveh Y, Friedman A. Foreign body in the airway. A review of 200 cases. *Am J Dis Child* 1980;134:68-71
8. Spitzer SA, Segal I, Lubin E, Nili M, Levy M. Unilateral increased transradiancy of the lung caused by bronchial carcinoid tumour. *Thorax* 1980;35:739-744
9. Wegener WA, Velchik MG. Ventilation-perfusion scintigraphy in an adult with congenital unilateral hyperlucent lung. *Clin Nucl Med* 1990;15:683-7
10. Genereux GP. Bronchial atresia: a rare cause of unilateral lung hypertranslucency. *J Can Assoc Radiol* 1971 Mar;22:71-82
11. Swyer PR, James GCW. A case of unilateral pulmonary emphysema. *Thorax* 1953; 8: 133-136
12. Angstadt JD, Cohn HE, Steiner RM. Unilateral hyperlucent lung due to bullous disease. *Chest* 1986;90:437-8
13. Fukumoto T, Uyama T, Sakiyama S, Kondo K, Monden Y. Mediastinal esophageal cyst causing unilateral hyperlucent lung. *Jpn J Thorac Cardiovasc Surg* 1999;47:141-3
14. Felson B. *Chest roentgenology*. Philadelphia: WB Saunders, 1973: 92-133
15. Grum CM, Yarnal JR, Cook SA, Cordasco EM, Tomashefski JF. Unilateral hyperlucent lung. Non-invasive diagnosis of pulmonary artery agenesis. *Angiology* 1981;32:194-207
16. Schawohl P, Hennig K, Thomas E. Bronchologic aspects of unilateral hypertransparency of the lung caused by hypoplasia of the pulmonary artery. *Bronches* 1970 Nov-Dec;20(6):404-15
17. Schlozman DL, Kerby GR, Ruth WE. Chronic pulmonary artery thrombosis with features of unilateral hyperlucent lung syndrome. *Am J Med* 1971;50:547-51
18. Wieder S, White TJ 3rd, Salazar J, Gold RE, Moinuddin M, Tonkin I. Pulmonary artery occlusion due to histoplasmosis. *AJR Am J Roentgenol* 1982 Feb;138(2):243-251
19. Wencil ML, Sitrin RG. Unilateral lung hyperlucency after mediastinal irradiation. *Am Rev Respir Dis* 1988;137:955-7

