

Pachydermoperiostosis (Primary Hypertrophic Osteoarthropathy): Case Report¹

Moon Hee Paik, M.D., Bae Young Lee, M.D., Kang Hoon Lee, M.D.,
Kyung Sup Song, M.D., Jin Wou Kim, M.D.², Ki Ouk Min, M.D.³

We report a case involving a young male with the complete form of primary hypertrophic osteoarthropathy. He presented with the typical features of the condition: thickening and furrowing of the skin of the forehead and scalp, and digital clubbing of the hands and feet. Plain radiographs of the long bones of the extremities depicted bilateral irregular, shaggy, cortical diaphyseal thickening. T1- and T2-weighted magnetic resonance imaging (MRI) of the femur demonstrated low-signal-intensity cortical thickening. Bone scintigraphy revealed no photon uptake in the long bones.

Index words : Primary hypertrophic osteoarthropathy, MR
Primary hypertrophic osteoarthropathy, bone scan

Hypertrophic osteoarthropathy represents a clinical syndrome consisting of clubbing of the digits of the hands and feet, enlargement of the extremities secondary to periarticular and osseous proliferation, and painful and swollen joints. The condition has been divided into two categories, primary hypertrophic osteoarthropathy, also known as "pachydermoperiostosis", and secondary hypertrophic osteoarthropathy, frequently referred to as "hypertrophic pulmonary osteoarthropathy" due to its association with a variety of pulmonary causes. Recent reports have described the findings of magnetic resonance imaging and bone scintigraphy (1 - 4). We report a case of pachydermoperiostosis, describing the imaging features apparent at plain radiography, bone scintigraphy, and magnetic res-

onance imaging.

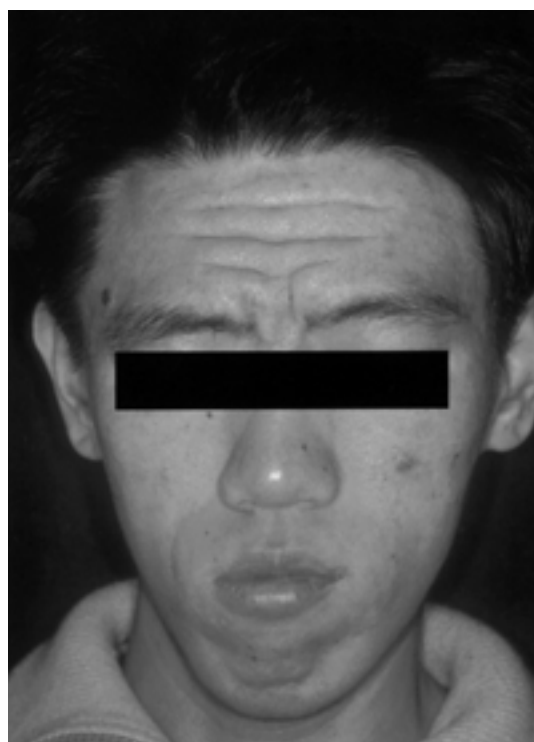


Fig. 1. Photograph of the patient's face shows furrowing and thickening of the skin of the forehead.

¹Department of Diagnostic Radiology, St. Paul's Hospital, The Catholic University of Korea

²Department of Dermatology, St. Paul's Hospital, The Catholic University of Korea

³Department of Clinical Pathology, St. Paul's Hospital, The Catholic University of Korea

Received July 23, 2002; Accepted September 18, 2002

Address reprint requests to : Bae Young Lee, M.D., Department of Diagnostic Radiology, The Catholic University of Korea, St. Paul's Hospital, 620-56 Jeonnong-dong, Dongdaemun-gu, Seoul 130-709, Korea.

Tel. 82-2-958-2084 Fax. 82-2-957-2810

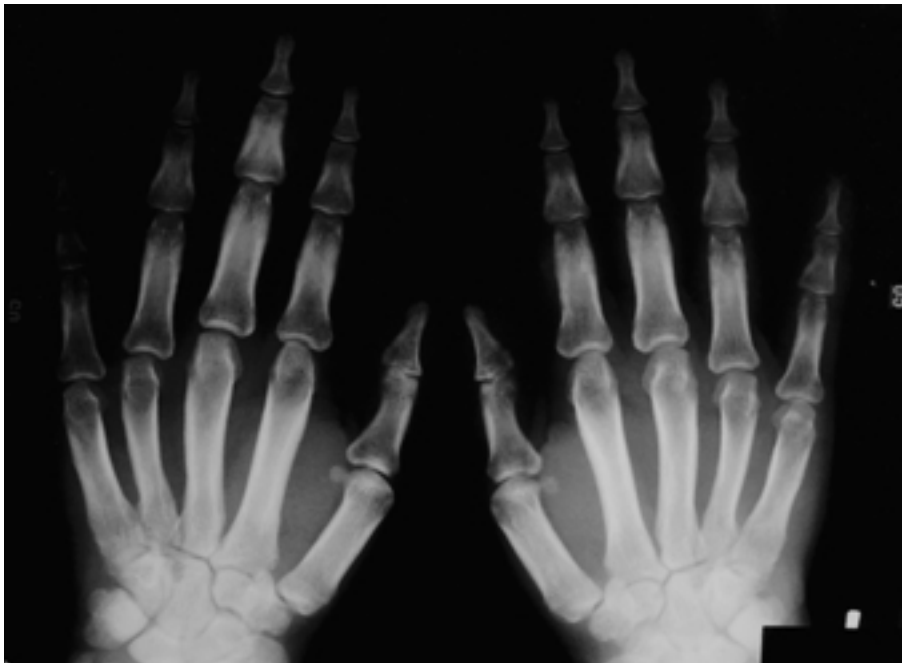
E-mail: goodlby@chollian.net

Case Report

A 28-year-old man presented with a ten year history of pain in both knees, not known to have occurred in other family members. During previous admission for the treatment of a duodenal ulcer, his morphologic features of thickening and furrowing of the skin of the forehead and scalp, and digital clubbing of hands and feet, which were specific features of primary hypertrophic osteoarthropathy, were detected by a dermatologist.

At physical examination, the furrowing and thickening of the skin of the forehead and scalp, and digital clubbing of the fingers, were confirmed (Fig. 1). The patient's height and weight were within normal limits, and endocrinological evaluation failed to establish any abnormality, including thyroid acropathy. Laboratory tests, however, revealed that he was anemic (hemoglobin, 7.2 mg/dL).

Radiographs of the patient's skull depicted a normal sella and mandibular angle, and the findings of plain chest radiography were also normal. Plain radiographs

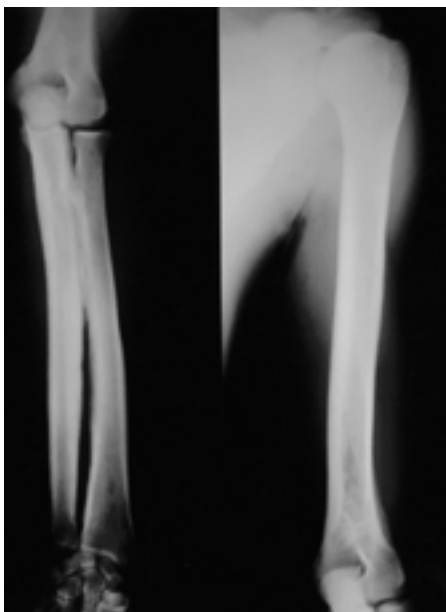


A

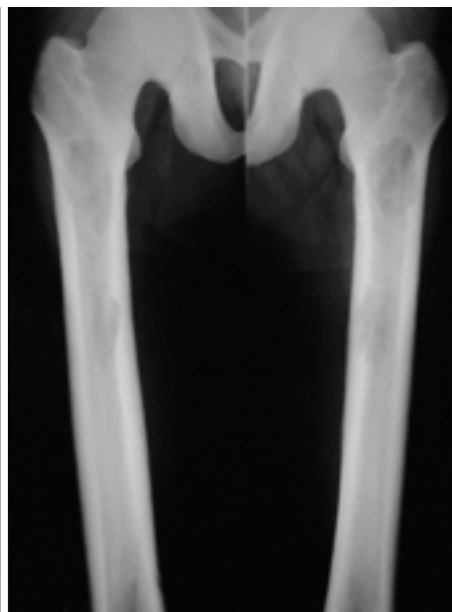Fig. 2. A. Plain radiograph of hands shows soft tissue swelling of the fingers (digital clubbing).

B. Plain radiograph of upper extremity shows irregular shaggy diaphyseal cortical thickening.

C. Plain radiograph of femurs shows bilateral irregular, shaggy diaphyseal cortical thickening. Bilateral symmetrical, well defined, scalloped intramedullary radiolucency is also seen in the diaphysis.



B



C

of the hands showed soft tissue thickening of the fingers without bony abnormality (Fig. 2A), but those of the extremities revealed bilateral irregular shaggy diaphyseal cortical thickening of the tibias, fibulas, femurs, radii, ulnas, and humeri. In addition, the diaphysis of both femurs showed symmetrically well-defined, scalloped intramedullary radiolucency (Figs. 2B, C). At T1- and T2-weighted MRI, low-signal-intensity periosteal thickening was seen in the diaphysis of the femur, and at T1-weighted and T2 spectral pre-saturation inversion recovery (SPIR) imaging, the intramedullary cavity of the diaphysis of the femur demonstrated higher signal intensity than the femoral head and neck. After the administration of gadolinium, both femurs showed homogeneous diffuse enhancement, with the intramedullary cavity showing greater enhancement than the femoral head and neck (Figs. 3A, B, C). Bone scanning demonstrated showed no photon uptake in long bones (Fig. 4).

Biopsy of the skin of the forehead revealed the presence of hyperkeratosis, acanthosis of the epidermis and hyperplastic sebaceous glands, and perivascular chronic

inflammatory cell infiltration and edematous change in the dermis (Fig. 5).

The patient was treated with nonsteroidal anti-inflammatory drugs, resulting in symptomatic relief of arthralgia.

Discussion

Early descriptions of the clinical entity known as hypertrophic osteoarthropathy are credited to Friedrich (1868) and Marie (1890). On the basis of the underlying etiology, the condition has been divided into two categories, primary (hereditary or idiopathic) and secondary hypertrophic osteoarthropathy. The former, also known as "pachydermoperiostosis", is inherited in an autosomal dominant pattern, with variable expressivity. Secondary hypertrophic osteoarthropathy is frequently referred to as "hypertrophic pulmonary osteoarthropathy" due to its association with a variety of pulmonary causes such as bronchogenic carcinoma, mesothelioma, bronchiectasis, and pulmonary abscess (5).

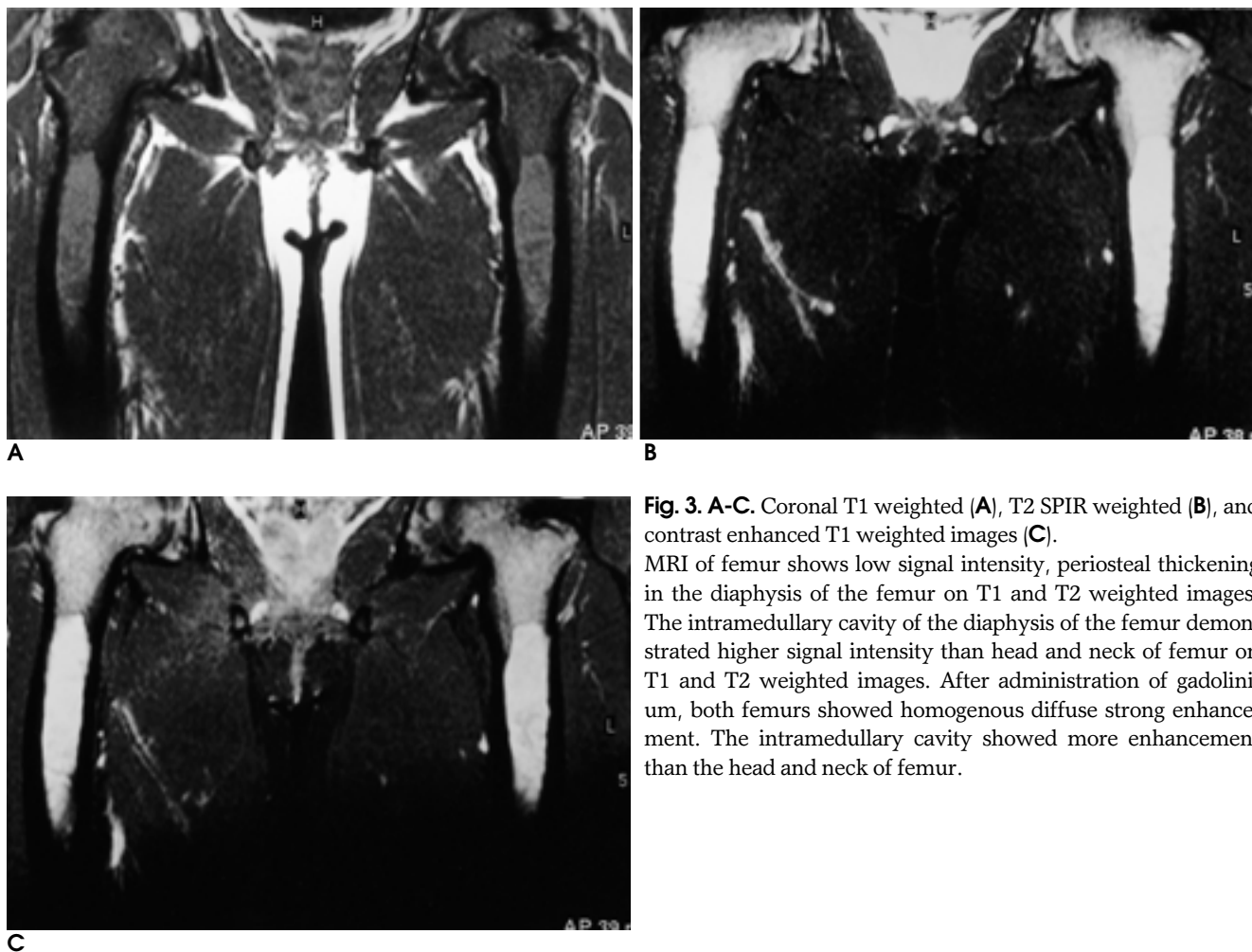


Fig. 3. A-C. Coronal T1 weighted (A), T2 SPIR weighted (B), and contrast enhanced T1 weighted images (C).

MRI of femur shows low signal intensity, periosteal thickening in the diaphysis of the femur on T1 and T2 weighted images. The intramedullary cavity of the diaphysis of the femur demonstrated higher signal intensity than head and neck of femur on T1 and T2 weighted images. After administration of gadolinium, both femurs showed homogenous diffuse strong enhancement. The intramedullary cavity showed more enhancement than the head and neck of femur.

Primary hypertrophic osteoarthropathy is far less common than the secondary form. In this disorder, vague bone and joint pains are reported in conjunction with progressive enlargement of the extremities, and

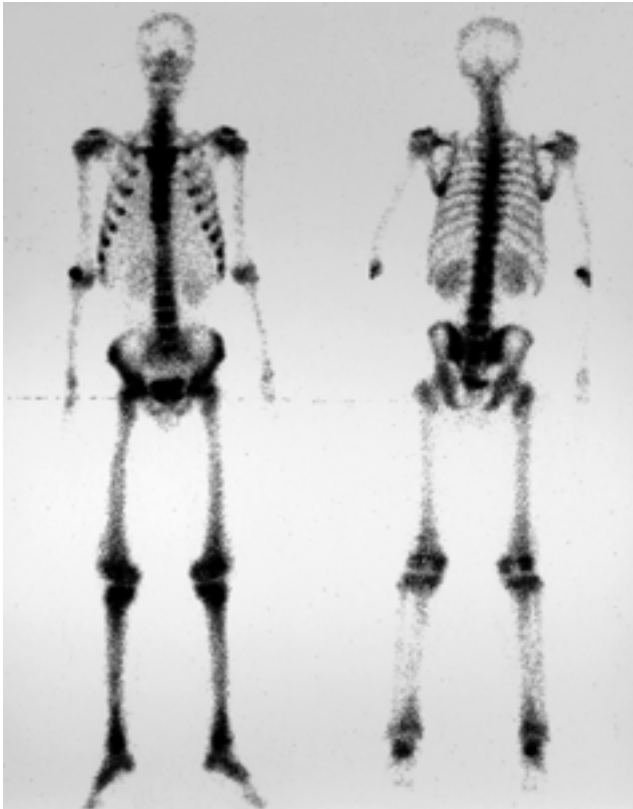


Fig. 4. Bone scintigraphy shows no photon uptake in bones.

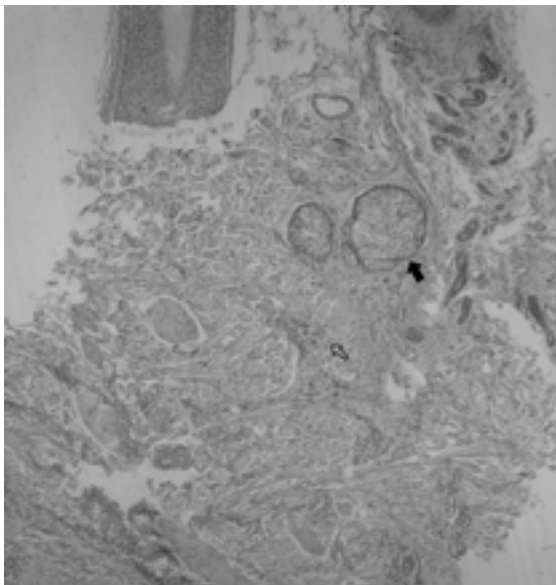


Fig. 5. Photomicrograph of forehead skin shows hyperplastic sebaceous glands (arrow), perivascular chronic inflammatory cell infiltration (open arrow) and edematous change in the dermis (hematoxylin-eosin stain; original magnification, $\times 100$).

digital clubbing, coarsening of the skin (pachydermia) and excessive sweating (hyperhidrosis) may occur. In the extreme form of pachydermia, cutis verticis gyrata develops, characterized by massive thickening and furrowing of the skin of the forehead and scalp, which resembles the gyral pattern of the brain. The clinical manifestations are somewhat variable, with affected patients demonstrating either the complete syndrome (pachydermia, periostosis, cutis verticis gyrata), the incomplete form (sparing the scalp), or the forme fruste (pachydermia with minimal or absent periostitis) (5).

The major pathologic finding in this disorder is periostitis involving the long tubular bones of the extremities. The initial phase of inflammatory periostitis is characterized by subperiosteal lymphocyte and plasma cell infiltration followed by subperiosteal new bone formation. With time, there is evolution of the periosteal configuration from an initial single layer to several layers and finally to an irregular wavy appearance (6). Eventually, a pseudocortex forms and ultimately fuses with the original cortex, resulting in increased shaft diameter (7). There is intermittent activity of the periosteal process, and correlation of radiologic patterns with duration of disease suggests that thicker, more extensive periosteal reaction is indicative of long-standing disease (6).

The radiologic findings typify the skeletal changes and type of periosteal reaction that develop in patients with long-standing disease, in which there is diaphyseal, metaphyseal, epiphyseal, and interosseous membrane involvement. The role of magnetic resonance imaging in the detection and characterization of periosteal new bone formation has recently been emphasized, and MR imaging can identify subradiographic cellular periosteal proliferation and allow assessment of the morphology and chronicity of periostitis (8). According to Moore (8), the MR appearance of periosteal reaction can be characterized according to the underlying histology. The initial phase of periostitis is termed "cellular" periosteal reaction and is characterized by thickening and differentiation of the periosteum into two histological layers. At T1-weighted MR imaging, a curvilinear layer of intermediate signal intensity superficial to cortical bone is observed, and at T2-weighted imaging, signal intensity increases. With maturation, single- or multiple-layer periosteal reaction is seen: one or more sheets of new woven bone thickened by surface apposition of lamellar bone arise. At both T1- and T2-weighted imaging, curvilinear, low-signal-intensity lamellar bone adjacent to but

not contiguous with the underlying cortical bone is seen (2). In our case, T1- and T2- weighted images were of low signal intensity, and periosteal reaction was observed. According to the explanation contained in the literature mentioned above, this appears to be the maturation, rather than the active phase.

In our case, an additional finding at plain radiography of femurs was symmetrical scalloped intramedullary radiolucency in the diaphysis. At T1- weighted and T2-SPIR MR imaging of the femur, the intramedullary cavity of its diaphysis demonstrated higher signal intensity than its head and neck of femur, but after the administration of gadolinium, both femurs showed homogenous diffuse enhancement and the intramedullary cavity showed more enhancement than the femoral head and neck. Unfortunately biopsy of the intramedullary cavity was not performed, so this bone lesion could not be proven histopathologically.

The reported bone scintigraphy findings of primary hypertrophic osteoarthropathy are of two types. Characterically, one is normal despite the presence of periosteal reaction at radiographic examination (9), and the other shows increased pericortical uptake. The features of pachydermoperiostosis include consistently symmetrical increased pericortical linear deposition of the tracer, especially along the distal ends of the tibia, fibula, ulna, and radius. In addition, increased transverse diameter of the long bones, especially at their distal ends is noted (4). One of the explanations given for this pericortical uptake is increased blood flow during the active stage of the disease and decreased flow during the quiescent stage (4). Jajic et al. stated that bone scintigraphy revealed increased pericortical uptake when the disease was active. During remission, the findings of scintigraphy were negative and not useful in the diagnosis of periostosis (3). In our case, bone scanning demonstrated no photon uptake in the long bones, despite the periosteal reaction observed at plain radiography. This suggests that bone scans were obtained during the remission stage of the disease.

The differential diagnosis includes osteomyelitis, thyroid acropathy, hypervitaminosis A, infantile cortical hyperostosis, fluorosis, and venous stasis. In differential diagnosis, the superficial nature, symmetry, and distal diaphyseal location of the periosteal reaction of hypertrophic osteoarthropathy are clearly distinguishable

from actual infection of the bone at those locations. The distribution of hypertrophic osteoarthropathy is quite different from that of thyroid acropathy, which predominantly affects metacarpals, metatarsals, and phalanges. The accentuated enthesial reaction of occurring in hypervitaminosis A, the predominantly mandibular, clavicular, scapular and costal involvement found in infantile cortical hyperostosis (Caffey's disease), and the enthesial calcification, trabecular distortion, and osteosclerosis occurring in fluorosis are also easily distinguished from the osseous lesions of hypertrophic osteoarthropathy. Periosteal reaction secondary to venous stasis occurs only in the lower extremity and is limited to the tibia and fibula (10).

In conclusion, when periosteal reaction in long bones, with specific clinical features of digital clubbing and pachydermia, is apparent, the possibility of pachydermoperiostosis should be considered. It is likely that both bone scintigraphy and MR reflect the stage of the disease and the chronicity of periostitis.

References

1. Dermirpolat G, Sener RN, Stun EE. MR imaging of pachydermoperiostosis. *J Neuroradiol* 1999;26:61-63
2. Lorendo R, Pathria MN, Salonen D, Resnick D. Magnetic resonance imaging in pachydermoperiostosis. *Clinical Imaging* 1996; 20:212-218
3. Jajic Z, Jajic I, Nemcic T. Primary hypertrophic osteoarthropathy: clinical, radiologic, and scintigraphic characteristics. *Arch Med Res* 2001;32:136-142
4. Bomannji J, Nagaraj N, Jewkes R, Fields M, Maini RN. Pachydermoperiostosis: Technetium-99m-methylene diphosphonate scintigraphic pattern. *J Nucl Med* 1991;32:1907-1909
5. Resnick D. *Diagnosis of bone and joint disorders*, 3rd ed. Philadelphia: WB Saunders, 1995:4421-4434
6. Pineda C, Martinez-Lavin M, Goobar J, Sartoris D, Clopton P, Resnick D. Periostitis in hypertrophic osteoarthropathy: relationship to disease duration. *AJR Am J Roentgenol* 1987;148:773-778
7. Gall E, Bennett GA, Bauer W. Generalized hypertrophic osteoarthropathy: a pathologic study of seven cases. *Am J Pathol* 1951;27:349-381
8. Moore SG. *Magnetic resonance imaging and computed tomography of cortical bone*. In Bloem JL, Sartoris DJ (eds): *MRI and CT of the Musculoskeletal system, A Text-Atlas*. Baltimore: Williams & Wilkins, 1992:139-152
9. Juhl JH, Crummy AB, Kuhlman JE. *Paul and Juhl's essentials of radiologic imaging*, 7th ed. Lippincott-Raven, 1998:122
10. Rothschild BM, Rothschild C. Recognition of hypertrophic osteoarthropathy in skeletal remains. *J Rheumatology* 1998;25:2221-2227

