

Unusual Renal Tuberculosis Manifested as an Isolated Renal Mass in an Immunocompromised Patient: A Case Report¹

Cheol Mok Hwang, M.D., Jeong Kon Kim, M.D., Kyoung-Sik Cho, M.D.

Renal tuberculosis commonly involves the urinary tract and results in multifocal fibrosis and stricture. Rarely, it presents as a renal mass with or without urinary tract abnormality. The radiologic features of this rare pseudotumor have not been sufficiently described in the previous literature, and we now report a case of tuberculosis presenting as an isolated renal mass and multiple hepatic nodules without evidence of associated urinary tract abnormality. The condition mimicked malignant neoplastic disease and occurred in a patient who had undergone chemotherapy for leukemia.

Index words : Kidney, US
Kidney, CT
Tuberculosis, genitourinary

Renal tuberculosis (TB) is still found in a substantial number of patients, and its significance in immunocompromised patients has recently been emphasized (1). The genitourinary system is one of the most common sites of extrapulmonary TB, and variable imaging features including progressive narrowing and dilatation of the urinary tract, cortical scarring and thinning, parenchymal calcification, and periureteral fibrosis have been reported (1 - 5). The pseudotumoral type, which presents as a mass without other urinary tract abnormality, is an extremely rare manifestation of renal TB, and the radiologic features of this type have not been sufficiently described in the previous literature. In this case report, we report the ultrasonographic and CT features of the pseudotumoral-type renal TB in a patient who had undergone chemotherapy for leukemia.

Case Report

A 43-year-old woman was transferred to our hospital for evaluation of a renal mass detected at a private clinic. Prior to admission she had undergone induction and consolidation chemotherapy for acute myeloblastic leukemia. Physical examination at admission revealed diffuse abdominal tenderness and pyrexia, though laboratory data showed that her blood cell count and urinalysis were within normal ranges. Chest radiography revealed nothing abnormal, but ultrasonography demonstrated the presence of a 2 cm-sized, well-defined, homogeneously hypoechoic mass which had grown beyond the outer margin of the upper pole of the left kidney (Fig. 1A). Neither color nor power Doppler ultrasonography revealed vascularity, contrast-enhanced CT scan showed that the lesion was generated from the renal cortex and was slightly enhanced, and that perinephric fat and the pelvocalyces were not invaded. In addition, CT scanning demonstrated multiple ill-defined, hypoattenuated liver nodules (Fig. 1B). Our initial diagnostic impression was malignant tumor involving the kidney and liver and probably related to leukemic

¹Department of Radiology, Asan Medical Center, University of Ulsan College of Medicine

Received May 28, 2001; Accepted October 26, 2001

Address reprint requests to : Kyoung-Sik Cho, M.D., Department of Radiology, Asan Medical Center, University of Ulsan College of Medicine, 388-1, Pungnap-dong, Songpa-gu, Seoul 138-736, Korea.

Tel. 82-2-3010-4400 Fax. 82-2-476-4719 E-mail: kscho@amc.seoul.kr

infiltration, or renal cell carcinoma with liver metastasis. We suggested that because the clinical and laboratory findings did not indicate infection, the existence of abscesses concomitantly involving both the kidney and liver was less likely. Repeated percutaneous fine-needle aspiration failed to provide confirmative diagnosis, and open biopsy was therefore performed. Histologic examination of the specimen thus obtained revealed multiple granulomas with caseation necrosis, consistent with TB.

Discussion

Among patients with pulmonary TB, renal TB has been identified in 4 - 8% (2), and among these, symptoms such as urinary frequency, microscopic hematuria, flank pain, sterile pyuria and acidic urine are usually present. Positive urine culture provides definite diagnosis, though several urine cultures for acid-fast organisms can be negative in spite of the presence of active disease, and needle aspiration or open biopsy is thus sometimes necessary (1).

The radiologic findings of renal TB show a wide spectrum, ranging from focal caliectasia to generalized hydronephrosis with cortical thinning and calcification. For the radiologic diagnosis of renal TB, intravenous urography has been commonly used for primary evaluation, but for the demonstration of cortical lesions the usefulness of this modality is limited. Although CT and ultrasonography are not the first steps in the diagnosis of renal TB, these imaging modalities are excellent for evaluation of the renal cortex and adjacent fat, as well as the urinary tract (3).

Renal TB commonly spreads hematogenously; inoculated bacilli are entrapped in the periglomerular capillaries and abscesses then form. In patients with intact cellular immunity, bacterial duplication is usually inhibited, and infection is confined to the cortex. The occurrence of small multiple cortical granulomas that are usually bilateral, asymptomatic and stable is therefore possible. Because they are small, lesion cannot, however, be identified radiologically unless they are calcified (1).

If there is breakdown in the host defense mechanism, cortical granulomas can reactivate, resulting in enlargement and coalescence, and renal TB may eventually extend to surrounding structures causing tissue destruction and fibrosis of the whole urinary tract. In rare cases, a coalesced cortical granuloma, a tuberculoma, may enlarge enough to be visible at ultrasonography and CT scanning. This uncommon manifestation of renal TB, the pseudotumoral type, is often associated with other urinary manifestations such as stricture and dilatation of the urinary tract. Pseudotumoral renal TB, which is not accompanied by other urinary tract abnormality is extremely unusual and has not been sufficiently discussed in the previous literature.

Mizunuma *et al.* (4) have stated that in renal TB, the attenuation of nodular lesions seen at CT scanning varies from hypodense to hyperdense, and depends on the degree of water absorption from caseous necrotizing materials. Kang *et al.* (7) showed that at angiography, renal TB appeared as a large parenchymal mass containing small calcifications and with irregular neovascularity.

In our case, the initial interpretation of ultrasonogra-

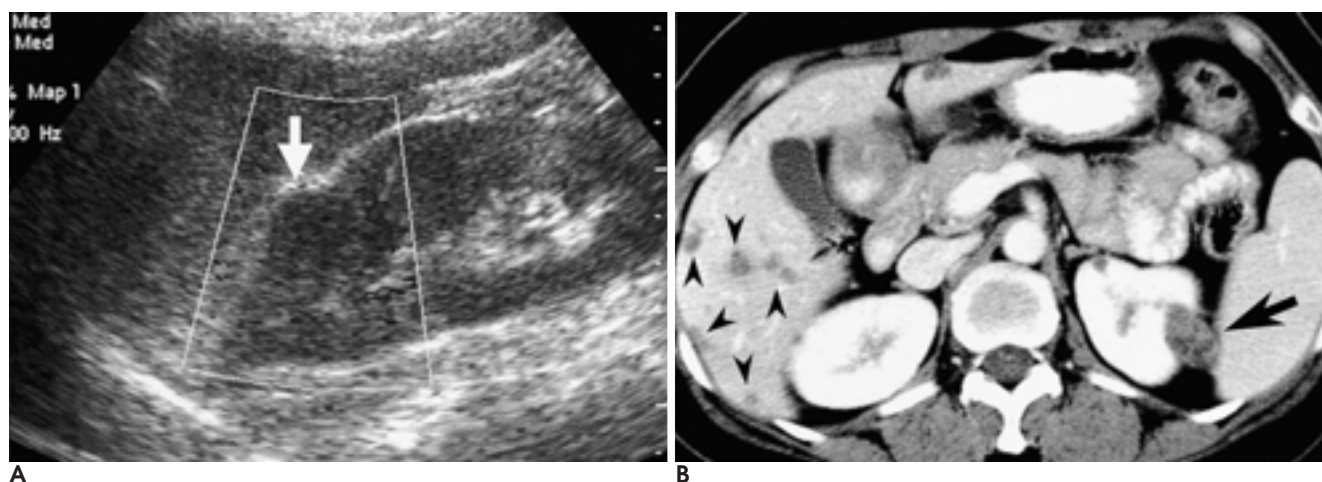


Fig. 1. Pseudotumoral type of renal tuberculosis involving the left kidney and liver in a 43-year-old woman.

A. Ultrasonography shows a hypoechoic mass (arrow) in the upper pole of the left kidney.

B. Contrast-enhanced CT shows a hypoattenuated, contour bulging mass (arrow) in the left kidney. Multiple ill-defined hypoattenuated nodules (arrowheads) are noted in the liver.

phy and CT scans was malignant tumor concomitantly involving the kidney and liver, and including leukemic infiltration, or renal cell carcinoma with liver metastasis. Retrospectively the presence of the liver of disseminated hypoattenuated nodules appeared to suggest TB. However, an isolated renal mass without other urinary tract abnormality and the absence of supportive clinical and laboratory data was too unusual to consider the possibility of TB.

In summary, we present a rare case of renal TB, seen at US and CT as an isolated renal mass without evidence of associated urinary abnormality. Awareness of this unusual manifestation may be helpful in understanding the variable features of renal TB.

References

1. Goldman SM, Fishman EK, Hartman DS, Kim YC, Siegelman SS. Computed tomography of renal tuberculosis and its pathologic correlates. *J Comput Assist Tomogr* 1985; 9:771-776
2. Lattimer JK, Kohen RJ. Renal tuberculosis. *Am J Med* 1954; 17:533-539
3. Premkumar A, Lattimer J, Newhouse JH. CT and sonography of advanced urinary tract tuberculosis. *AJR Am J Roentgenol* 1987; 148:65-69
4. Mizunuma K, Toyoda K, Tada S, Kaneko K, Yamaguchi M. Nodular lesions in renal tuberculosis. *Radiat Med* 1994; 12:263-267
5. Wang LJ, Wong YC, Chen CJ, Lim KE. CT features of genitourinary tuberculosis. *J Comput Assist Tomogr* 1997; 21:254-258
6. Murata Y, Yamada I, Sumiya Y, Shichijo Y, Suzuki Y. Abdominal macronodular tuberculosis: MR findings. *J Comput Assist Tomogr* 1996; 20:643-646
7. Kang JJ, Cho OK, Hah HK, Kang SR. Unusual tumefactive renal tuberculosis. *J Korean Radiol Soc* 1980; 16:602-605
8. Patanakar T, Prasad S, Armao D, Mukherji SK. Tuberculous Abscesses of the Liver *AJR Am J Roentgenol* 2000; 174:1166-1167
9. Marques LP, Rioja LS, Oliveira CA, Santos OD. AIDS-associated renal tuberculosis. *Nephron* 1996; 74:701-704
10. Sunderam G, McDonald RJ, Maniatis T, et al. Tuberculosis as a manifestation of the acquired immunodeficiency syndrome (AIDS). *JAMA* 1986;256:3362-3366

