



: 1 1

10

(Fig. 1E)

가 (1).
20% (3) S100
4.6%

(1, 2).
가

4.6%

(3),

(1).

10 가 1

1

가

CT MRI

(Fig. 1A)

Cushing (5)

(MRI)

T1

(Fig. 1B)

Zachariae (6)

가

, T2

(Fig. 1C)

(Fig. 1D).

T1

(Fig. 1B)

T2

(Fig. 1C)

(7).

가

3.8 × 1.5 × 1.0 cm

가

(EMA), vimentin, S100

EMA, vimentin

(8).

EMA

S100

, S100

0.8 × 0.5 cm

(4),

:

가 (4).

가

(8),

Lopez (9)

mm 6-

7 cm

(9).

가

(4).

가

가

가

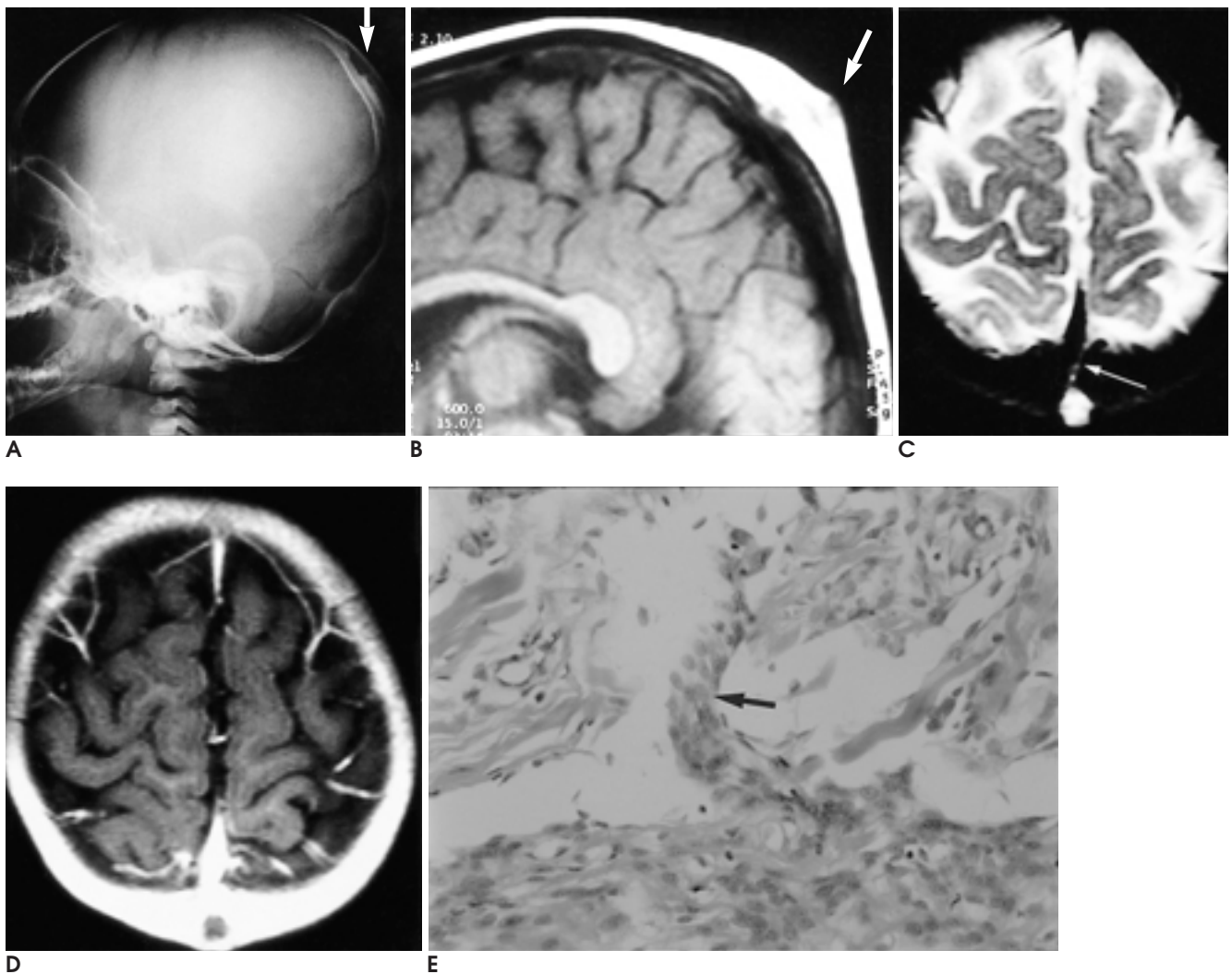


Fig. 1. Primary cutaneous meningioma at scalp

A. Conventional radiograph in the lateral projection shows small irregular bony erosion (arrow) in the parietal region.

B. On sagittal T1-weighted image, there is a bulging scalp mass (arrow) at the midline of parietal region. This mass is iso- or slightly hypointense with brain. The outer table of skull shows focal erosion by the mass.

C. On axial T2-weighted image, the scalp mass is connected with a thin linear structure of high signal intensity (arrow). The linear structure traverses the skull and suspiciously contiguous with outer dura or inner table of skull.

D. The mass is poorly enhanced.

E. Histologic section of the mass shows meningotheelial cell proliferation (arrow). (Hematoxylin eosin stain, $\times 250$)

(9).

T2

가

CT MRI

가

가

가

(2).

1. Altinörs N, Çetin A, Pak I. Scalp Meningioma: Case Report. *Neurosurgery* 1985;16:379-380
2. Ragoowansi R, Thomas V, Powell BWEM. Cutaneous meningioma of the scalp: a case report and review of literature. *Br J Plast Surg* 1998;51:402-404
3. Herz DA, Shapiro K, Shulman K. Intracranial meningiomas of infancy, childhood and adolescence. Review of the literature and addition of 9 case reports. *Childs Brain* 1980;7:43-56
4. Theaker JM, Fleming KA. Meningioma of the scalp. *J Cutan Pathol* 1987;14:49-53
5. Cushing H: The meningiomas (dural endotheliomas): Their source, and favoured seats of origin. *Brain* 1922;45:282-316
6. Zachariae L: A case of extracranial primary meningioma. *Acta Pathol Microbiol Scand* 1952;31:57-60
7. Siegel GJ, Anderson PJ: Extracalvarial meningioma: Case report. *J Neurosurg* 1966;25:83-86
8. Miyamoto T, Mihara M, Hagari Y, Shimao S. Primary cutaneous meningioma on the scalp: report of two siblings. *J Dermatol* 1995; 22:611-619
9. Lopez DA, CDR, MC, et al. Cutaneous meningiomas-a clinico-pathologic study. *Cancer* 1974;34:728-744

Primary Cutaneous Meningioma on the Scalp of an Infant: A Case Report¹

Su Jeong Kim, M.D., Ji Yeon Lim, M.D., Sung Mee Kim, M.D., Eun Ae Yoo, M.D.

¹Department of Radiology, Presbyterian Medical Center, Chunju

During childhood, meningioma is an uncommon tumor, and in infants, extracranial meningioma is very rare. We report a case of primary cutaneous meningioma occurring on the scalp of a ten-month-old girl.

Index words : Skin, disease
Skin, MR

Address reprint requests to : Su Jeong Kim, M.D., Department of Radiology, Presbyterian Medical Center,
300, Jungwhasan-dong Wansan-gu, Chunju 560-750, Korea.
Tel. 82-63-230-8436, 8446 Fax. 82-63-230-8463

2002 / 5 / 18 - 24	ISMRM, 10th Annual Scientific Meeting and Exhibition of the International Society of Magnetic Resonance in Medicine	2002 / 12 / 1 - 6	RSNA, 88th Scientific Assembly and 2002 Annual Meeting of the Radiological Society of North America
<ul style="list-style-type: none"> • Subject: • Location: • Contact: • Phone: • Fax: • E-Mail: • Internet: 	Imaging X-Ray Magnetic Resonance Imaging Medicine Pharmacology Honolulu Hawaii: Hawaii Convention Center USA Intl. Soc. f. Magnetic Resonance in, Medicine, Cordie Miller, 2118 Milvia Street, Suite 201, Berkeley, CA 94704, USA (510) 841-1899 Countryphone: + 1 (510) 841-2340 info@ismrm.org http://www.ismrm.org	<ul style="list-style-type: none"> • Subject: • Location: • Contact: • Phone: • Fax: • E-Mail: • Internet: 	Imaging X-Ray Pharmacology Pharmaceuticals Chicago Illinois: McCormick Place USA Radiological Soc. of North America, Delmar J. Stauffer, 820 Jorie Boulevard, Oak Brook, IL 60521, USA (630) 571-2670 Countryphone: + 1 (630) 571-7837 reginfo@rsna.org http://www.rsna.org
2002 / 11 / 1 - 5	12th World Congress on Ultrasound in Obstetrics and Gynecology		
<ul style="list-style-type: none"> • Subject: • Location: • Contact: • Phone: • Fax: • E-Mail: • Internet: 	Fertility Control/Hormone Therapy Obstetrics/Gynecology Imaging Ultrasound New York: Marriott Marquis USA Intl. School of Ultrasound in Obstetrics, & Gynecology, St. Georges Hosp., Cranmer Terrace, Lanesb. Wing, 3rd F., London SW17 0RE, Great Britain (0208) 725 2505 Countryphone: + 44 (0208) 725 0212 johnson@sghms.ac.uk http://www.isuog.org		