

CT : 1 1

. . 2 . 3 . .

1 .

polymerase chain reaction

Haemophilus influenza Ag

가 가 Kiu (1) 가 74. 5% 가 가 (Fig. 1A - C).
23% , 가 ,

42.5 cmCSF 가
가 13,750 가
가 95%, 가 5%
PCR (polymerase chain reaction)
Haemophilus influenza Ag
ceftriaxone metronidazole
5
(1 - 7).

가 6

51

1

가
Clostridium perfringens, anaerobic streptococcus,
Diphtheria bacillus, pneumococci, actinomyces (1,
3). 6

51

가

1

가

가
Clostridium perfringens

24

(2).

94

8 mm

Streptococcus pneumoniae

(4).

62

1
2
3

2000 7 12 2000 10 28

E. coli, Streptococcus viridans, Bacteroides fragilis가

(5).

57

가

가

가

S. pneumoniae

(6).

2

Clostridium septicum, Clostridium perfringens

1

(1, 4).

가

(3, 7).

(1 - 7).

, PCR Haemophilus influenza Ag
(94%, 96%) (8, 9)

가

7

5

가 13,750

가

가 95%

71%

가

Haemophilus influenza 가

가

0.5 cc

- 1000

(Hounsfield unit; HU)

(1, 5).

3

HU가 -694

(region of

HU

interest; ROI) 가 가 가

1. Kiu MC, Wan YL, Ng SH, Lee ST, Hao SP. Pneumocephalus due to nasopharyngeal carcinoma: case report. *Neuroradiology* 1996;38: 70-72

2. Goyal M, Sharma R, Berry M. Diffuse pneumocephalus due to

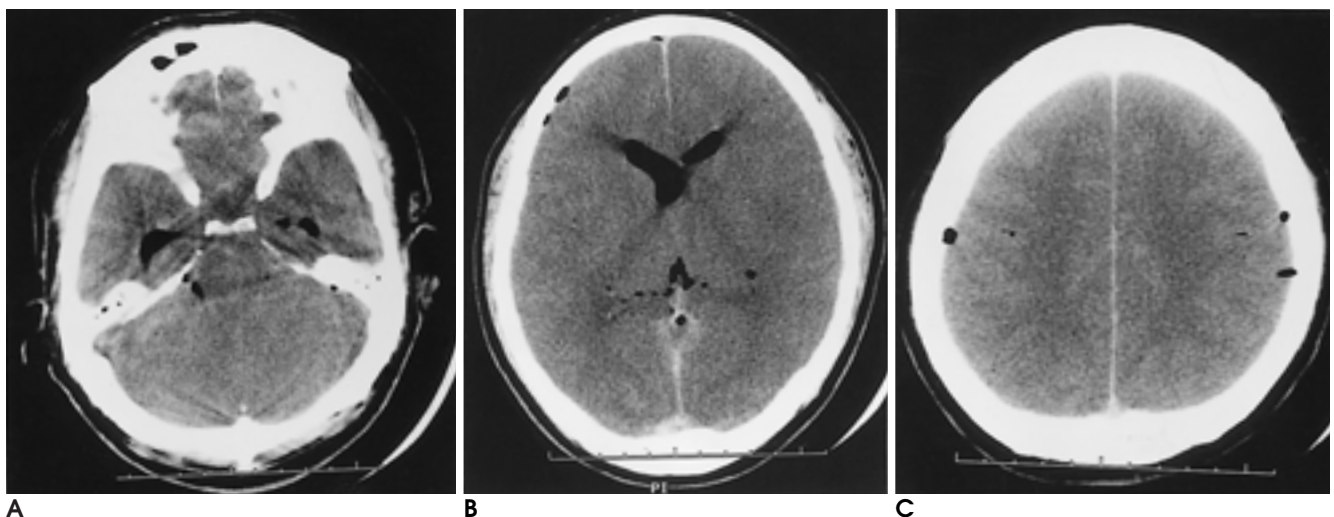


Fig. 1. Precontrast Brain CT scan of pneumocephalus from gas-forming bacterial infection.

A. The 4th ventricle is filled with soft tissue density; probably due to turbid-thick CSF or pus. Pneumocephalus is seen in the temporal horn of both side lateral ventricles and the subarachnoid space of the posterior fossa.

B. Pneumocephalus is seen in the frontal horn of both side lateral ventricles, the cavum interpositum, the right frontal subdural or epidural space and probably in the superior sagittal sinus.

C. Brain parenchyma shows diffuse brain swelling with effacement of sulci. Corticomedullary differentiation is preserved. Pneumocephalus is seen in the both parietal intracranial extraparenchymal space.

- meningitis : CT findings. *Pediatr Radiol* 1996;26:278-279
3. Klein MA, Kelly JK, Jacobs IG. Diffuse pneumocephalus due to *Clostridium perfringens* meningitis: CT findings. *AJNR Am J Neuroradiol* 1989;10:447
 4. Finelli PF, Bergen R. Spontaneous pneumocephalus with meningitis: CT demonstration. *J Comput Assist Tomogr* 1991;15:525-529
 5. Maliwan N. "Spontaneous" pneumocephalus associated with mixed aerobic-anaerobic bacterial meningitis. *J Infect Dis* 1985;152:847-848
 6. Winton MD, Everett ED, Watts CH. Pneumococcal infection and gurgling in the head. *Ann Intern Med* 1987;106(5):912-913
 7. Randall JM, Hall K, Coulthard MG. Diffuse pneumocephalus due to *Clostridium septicum* cerebritis in haemolytic uremic syndrome : CT demonstration. *Neuroradiology* 1993;35:218-220
 8. Backman A, Lantz P, Radstrom P, Olcen P. Evaluation of an extended diagnostic PCR assay for detection and verification of the common causes of bacterial meningitis in CSF and other biological samples. *Mol Cell Probes* 1999;13(1):49-60
 9. van Ketel RJ, de Wever B, van Alphen L. Detection of *Haemophilus influenzae* in cerebrospinal fluids by polymerase chain reaction DNA amplification. *J Med Microbiol* 1990;33(4):271-276

J Korean Radiol Soc 2001;44:15 - 17

CT Findings of Diffuse Pneumocephalus due to Bacterial Meningitis: A Case Report¹

Ji Yeon Seok, M.D., Hyun-Sook Kim, M.D., Hee-Joon Bae, M.D.²,
Hwa Ryung Chung, M.D.³, Dae-Hong Kim, M.D., Yong Kyu Yoon, M.D.

¹Department of Radiology, Eulji University, School of Medicine

²Department of Neurology, Eulji University, School of Medicine

³Department of Clinical Pathology, Eulji University, School of Medicine

We report a case of diffuse pneumocephalus due to infection. Brain CT revealed diffuse brain swelling and diffuse pneumocephalus in the ventricular system, subarachnoid space, subdural/epidural space and superior sagittal sinus. CSF disclosed the presence of a yellowish-green pus-like liquid. Polymerase chain reaction was positive for *Haemophilus influenzae* Ag.

Index words : Brain, CT
Brain, infection

Address reprint requests to : Hyun-Sook Kim, M.D., Department of Radiology, Nowon Eulji Hospital,
280-1, Hagye 1 Dong, Nowon Gu, Seoul 139-231, Korea.
Tel. 82-2-970-8290 Fax. 82-2-970-8346 E-mail: radhskim@medikorea.net

2001

()

	23	01. 6. 9()	
		01. 4. 28() 01. 4. 28()	
	2002 Scholarship	01. 7. 31()	
	2002 Fellowship	01. 7. 31()	
2002	, 2002	01. 9. 29()	
57	57	01. 10. 17() - 19()	
	가	01. 7. 31() 01. 7. 31() 01. 9. 15()	
		01. 11. 3()	
87th RSNA	87th RSNA()	01. 11. 25() - 30()	Chicago USA
Imaging Conference		01. 1. 17() 18:00 -	()
		01. 2. 21() "	"
		01. 3. 21() "	"
		01. 4. 18() "	"
		01. 5. 16() "	"
		01. 6. 20() "	"
		01. 7. 18() "	"
		01. 8. 29() "	"
		01. 9. 19() "	"
		01. 10. 10() "	"
		01. 11. 14() "	"
		01. 12. 19() "	"