

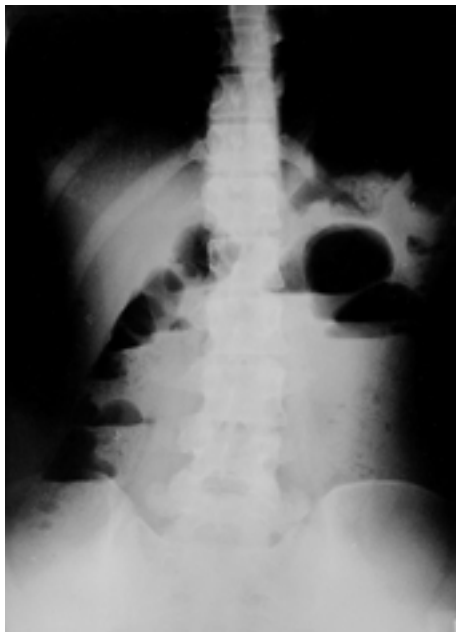# Peutz - Jeghers syndrome

: 2 1

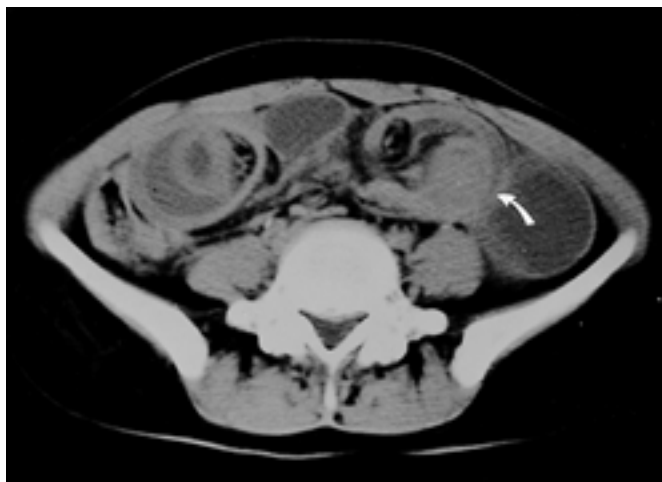
2

Peutz - Jeghers syndrome(PJS)  
( gastrointestinal polyposis)  
(intussusception) PJS 2

Peutz - Jeghers syndrome(PJS) PJS 1) 2)  
(gastrointestinal polyposis) 3)  
(intussusception) PJS 가  
2 (short bowel syndrome)



A



B

**Fig. 1.** Case 1 **A.** Plain radiograph of the abdomen shows dilated bowel loops with air-fluid levels.  
**B.** CT scan of the lower abdomen shows intussusception within the dilated intussusciens. Isodense hamartomatous polyp (arrow) is seen within the ileal bowel loop.

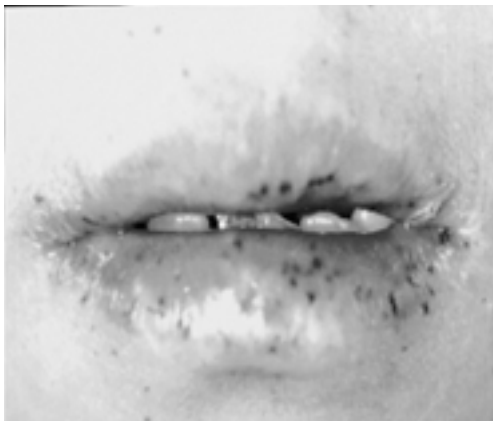1  
2

2001 3 9

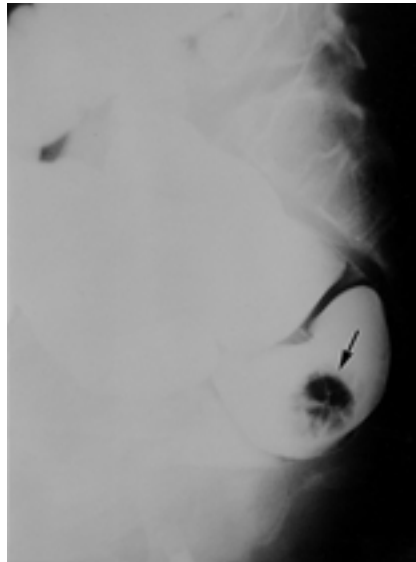
2001 4 25

: Peutz-Jeghers syndrome

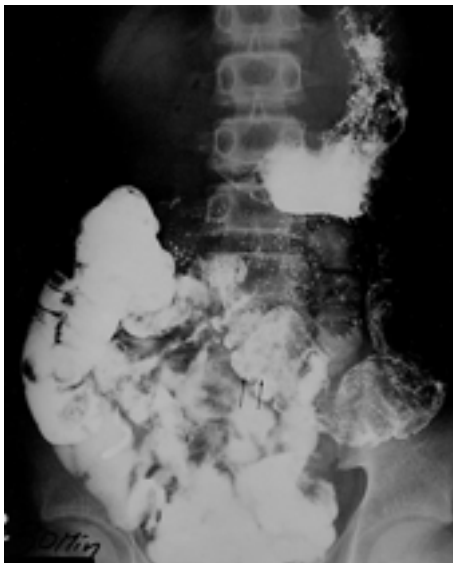(7-9) 가 (1-6) (Fig. 1B).  
 (Treitz ligament) 130 cm  
 (jejunum) 90 cm가  
 3×5 cm  
 PJS  
 (hamartomatous polyp)  
 (hyperplastic polyp)  
 21 가  
 5 가  
 PJS  
 (Fig. 1A) PJS  
 16 가



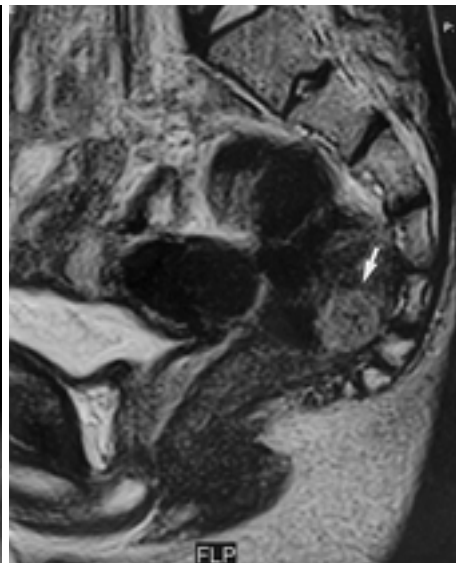
A



B



C



D

**Fig. 2.** Case 2 **A.** Face photograph of a 16-year-old boy shows melanin hyperpigmentation around the lips and nose.

**B.** Lateral view of double contrast enema shows hamartomatous polyp (arrow) in rectum.

**C.** Small bowel series shows multiple polypoid filling defects (arrows) in small bowel loops.

**D.** Sagittal T2-weighted FSE image shows isosignal intensity of hamartomatous polyp (arrow) in rectum.

(Fig. 2A).  
 (ileocecal valve) 100 cm  
 가 40 PJS 가 가  
 (barium enema) (Fig. 2B), (UGI)  
 (SBS) (Fig. 2C).  
 T1  
 T2 (Fig. 2D).  
 PJS  
 1 - 2 mm  
 (1). PJS 가  
 PJS  
 0.1 mm - 3 cm  
 (adenoma)  
 Harrisburg 가 49  
 PJS 가 12 2  
 (2), 31 13  
 PJS 31 15 (48%)  
 4 , 4 , 2  
 가 1 , (adenocarcino -

ma) 1 , (multiple myeloma) 1 (3).  
 PJS (8), , ,  
 (4), , , , ,  
 (3, 7).  
 가  
 (5, 9).  
 가 , , 가  
 (6). 가  
 가  
 (5).  
 30% (6). 1  
 2 가  
 가  
 PJS 가  
 1. Sener RN, Kumcuoglu Z, Elmas N, Oyar O, Tugran C. Peutz-Jeghers syndrome: CT and US demonstration of small bowel polyps. *Gastrointest Radiology* 1991;16:21-23  
 2. Raymond Foley T, McGarrity TJ, Abt AB. Peutz-Jeghers syndrome: a clinicopathologic survey of the "Harrisburg Family" with a 49-Year follow-up. *Gastroenterology* 1988;95:1535-1540  
 3. Giardiello FM, Welsh SB, Hamilton SR, et al. Increased risk of cancer in the Peutz-Jeghers syndrome. *N Engl J Med* 1987;316:1511-1514  
 4. Bowlby LS. Pancreatic adenocarcinoma in an adolescent male with Peutz-Jeghers syndrome. *Hum Pathol* 1986;17:97-99  
 5. Naganuma H, Ischida H, Konno K, et al. Intussusception in Peutz-Jegher syndrome: sonographic findings. *Abdom Imaging* 1999;24:333-335  
 6. Gonard JE, Dodds WJ, Phillips JC, Scanlon GT. Peutz-Jeghers syndrome: clinical and roentgenographic features. *AJR Am J Roentgenol* 1971;113:316-324  
 7. Peutz-Jeghers syndrome 1 . 1999;56:378-382  
 8. Peutz-Jeghers 1 . 1993;25:773-781  
 9. Peutz-Jeghers syndrome . 1996;51:740-746

## Two Case Reports of Intussusception in Patients with Peutz-Jeghers Syndrome<sup>1</sup>

Il Ju Yoon, M.D., Hyoungh Sim Ser, M.D., Chan Ho Ok, M.D.<sup>2</sup>

<sup>1</sup>*Department of Radiology, Myung-Ji St. Mary 's Hospital*

<sup>2</sup>*Department of General Surgery, Myung-Ji St. Mary 's Hospital*

Peutz-Jeghers syndrome(PJS) is a relatively rare autosomal-dominant disease characterized by the occurrence of extensive mucocutaneous hyperpigmentation and gastrointestinal polyps. PJS patients are considered to have a high prevalence of intussusception due to polyps. We report the radiological findings in two cases of intussusception due to polyps in patients with PJS, and review the literature.

**Index words :** Intestines, CT  
Intestinal, neoplasms  
Intussusception

Address reprint requests to : Il Ju Yoon, M.D., Department of Radiology, Myung-Ji St. Mary 's Hospital  
709-1, Dae lim 2-dong, Young dounng po-ku, Seoul 150-072, Korea.  
Tel. 82-2-8297-852 Fax. 82-2-8297-888 E-mail: iljyoon@hanmail.net