

: 1 1

(PVNS)

PVNS

PVNS 1

(Pigmented villonodular synovitis,

PVNS)

space)

가

(pseudoglandular

1980 Kleinman (1)

30 가

(2 - 7).

PVNS 1

PVNS

(Fig. 3A, B).

44

가 1

7

2

70° ; 60°

4 - 5

4 - 5

(thecal sac)

(Fig. 1).

가

(' CT ')

가

가

(Fig. 2A, B).

7

(bursitis)

4 - 5

가

가

1

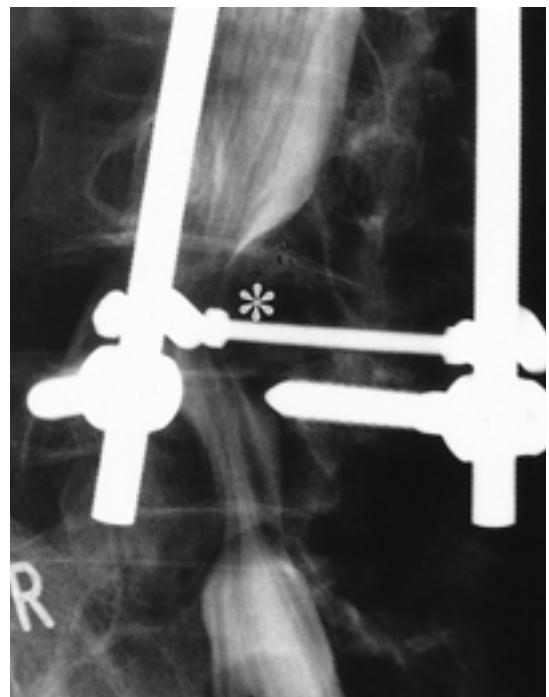


Fig. 1. Lumbar myelogram in oblique view shows the left-sided extradural mass(asterisk) at the level of the fourth and fifth lumbar disc space.

PVNS (15%), (80%) PVNS 가 (9). PVNS
 (2, 8, 9). PVNS 가
 siderin) (10 - 12). (hemo - (2). Giannini (2) 9
 8 가 5
 20 , 4 가
 (4, 13). PVNS 가 (41%) (2). PVNS 가 (diarthrodial
 joint) PVNS

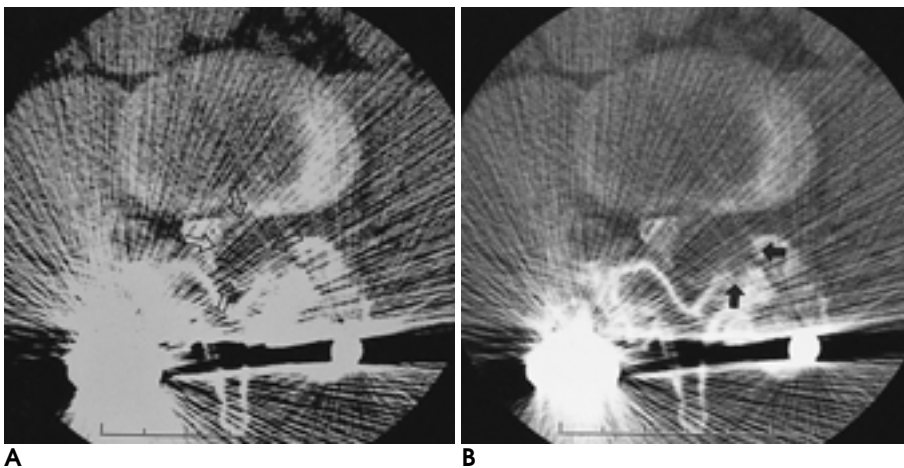


Fig. 2. Post-myelogram CT shows left-sided extradural soft-tissue mass(arrows) at the level of L4-5 disc space displacing the thecal sac(**A**). Note bony erosion of the left facet joint on bone setting(arrows on **B**).

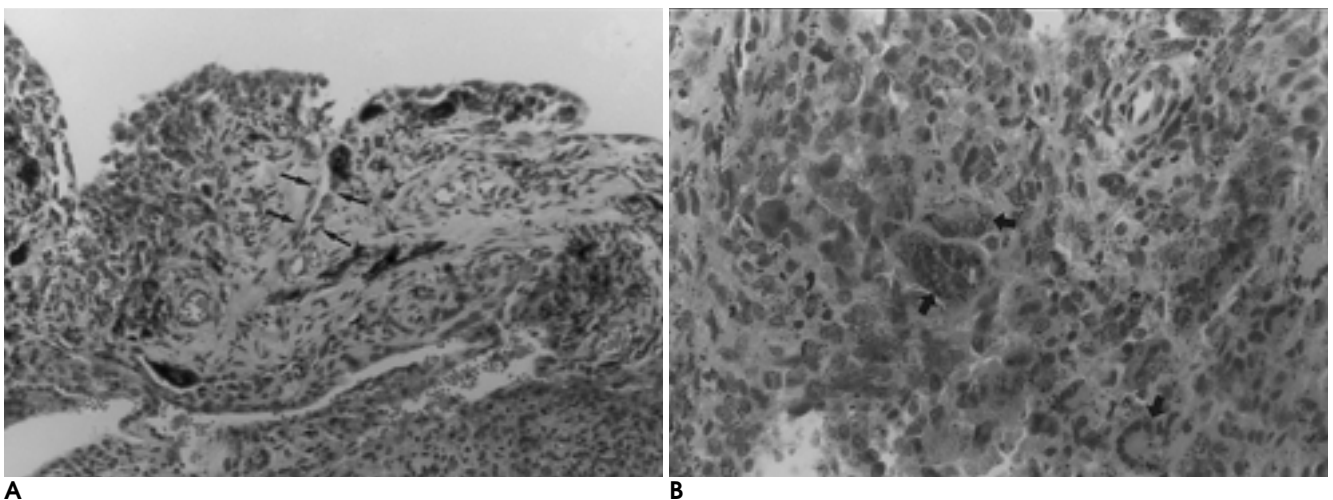


Fig. 3. Histology of PVNS
A. There is sheet-like synovial overgrowth pattern interrupted by pseudoglandular spaces(arrows). (H&E stain, $\times 100$)
B. The predominant cells which show round or polygonal are laden with hemosiderin. Note the multinucleated giant cells(arrows). (H&E stain, $\times 400$)

synovitis) . (hypertrophic
가 가 .
ovial cyst) (syn -
가 . PVNS
(osteoblastoma) (aneurysmal bone
cyst) .
; 가 , , ;)
가 (2).
PVNS (10).
가 가
(12).
(14).

1. Kleinman GM, Dagi TF, Poletti CE. Villonodular synovitis in the spinal canal: case report. *J Neurosurg* 1980;52:846-848
2. Giannini C, Scheithauer BW, Wenger DE, Unni KK. Pigmented villonodular synovitis of the spine: a clinical, radiological, and morphological study of 12 cases. *J Neurosurg* 1996;84:592-597
3. Gezen F, Akay KM, Aksu AY, Bedtk A, Seber N. Spinal pigment-

- ed villonodular synovitis: a case report. *Spine* 1996;21:642-645
4. Clark LJ, McCormick PW, Domenico DR, Savory L. Pigmented villonodular synovitis of the spine: case report. *J Neurosurg* 1993;79:456-459
5. Karnezis TA, McMillan RD, Ciric I. Pigmented villonodular synovitis in a vertebra: a case report. *J Bone Joint Surg[Am]* 1990;72:927-930
6. Campbell AJ, Wells IP. Pigmented villonodular synovitis of a lumbar vertebral facet joint: a case report. *J Bone Joint Surg[Am]* 1982;64:145-146
7. Bui-Mansfield LT, Youngberg RA, Coughlin W, Chooljian D. MRI of giant cell tumor of the tendon sheath in the cervical spine. *J Comput Assist Tomogr* 1996;20:113-115
8. Fechner RE, Mills SE. *Atlas of tumor pathology*. third series, fascicle 8: Tumors of the bones and joints. Washington DC: *Armed Forces Institute of Pathology*. 1993;282-287
9. Dorwart RH, Genant HK, Johnston WH, Morris JM. Pigmented villonodular synovitis of synovial joints: Clinical, pathologic, and radiographic features. *AJR Am J Roentgenol* 1984;143:877-885
10. Granowitz SP, D 'Antonio J, Mankin HL. The pathogenesis and long-term end results of pigmented villonodular synovitis. *Clin Orthop* 1976;114:335-351
11. Jaffe HL, Lichtenstein L, Sutro CJ. Pigmented villonodular synovitis, bursitis and tenosynovitis. A discussion of the synovial and bursal equivalents of the tenosynovial lesion commonly denoted as xanthoma, xanthogranuloma, giant cell tumor or myeloplaxoma of the tendon sheath with some consideration of this tendon sheath lesion itself. *Arch Pathol* 1941;31:731-765
12. Weidner N, Challa VR, Bonsib SM, Davis CH, Carroll TJ. Giant cell tumors of synovium[pigmented villonodular synovitis] involving the vertebral column. *Cancer* 1986;57:2030-2036
13. Goldman AB, DiCarlo EF. Pigmented villonodular synovitis. Diagnosis and differential diagnosis. *Radiol Clin North Am* 1988;26:1327-1347
14. Bentley G, McAuliffe T. Pigmented villonodular synovitis. *Ann Rheum Dis* 1990;49:210-211

Pigmented Villonodular Synovitis of the Spine: A Case Report¹

Su Ok Seong, M.D., Joo-Hyuk Lee, M.D., Jeong Geun Yi, M.D.

¹Department of Radiology, Cheongju St. Mary 's Hospital

Pigmented villonodular synovitis(PVNS) is a synovial lesion of joints or tendon sheaths, characterized by villous and nodular overgrowth of the synovial membrane. It commonly occurs in synovial joints of the appendicular skeleton, particularly those of the knee and hip, but rarely affecting those of the spine. We report a case of PVNS of the lumbar spine mimicking epidural mass.

Index words : Spine, CT
Spine, disease
Spine, facet joints
Synovitis

Address reprint requests to : Su Ok Seong, M.D., Department of Radiology, Cheongju St. Mary 's Hospital
589-5, Jujung-dong, Sangdang-gu, Cheongju, Choongchungbuk-do 360-568, Korea.
Tel. 82-43-212-5000 Fax. 82-43-212-1345 E-mail: SOS@medikorea.net