

Mixed Form of Congenital Cystic Adenomatoid Malformation and Extralobar Bronchopulmonary Sequestration : A Case Report¹

Wan Tae Kim, M.D., Mi Young Kim, M.D., Hyun Ja Shin, M.D.

Bronchopulmonary sequestration(BPS) and congenital cystic adenomatoid malformation (CCAM) are rare, but both should be included in the differential diagnosis of fetal lung mass. We experienced a mixed form of Stocker type-III CCAM and extralobar BPS, and present this case, together with a review of the related literature.

Index words : Fetus, respiratory system

Fetus, US

Fetus, MR

Congenital cystic adenomatoid malformation (CCAM) is a cystic, intraparenchymal lung mass in which histological examination reveals abnormal proliferation of bronchiolar like air spaces and a lack of normal alveoli. These lesions usually communicate with the tracheobronchial tree and derive their blood supply from the pulmonary circulation. In contrast, bronchopulmonary sequestration (BPS) is an immature, nonfunctional lung tissue that does not communicate with the tracheobronchial tree and has a separate anomalous systemic blood supply (1).

In Korea, CCAM and BPS have occasionally been reported, but the mixed form of CCAM and BPS has not been described. We report a case of the mixed form of Stocker type-III CCAM and extralobar BPS, describing the antenatal US and MR findings.

Case Report

A 35-year-old woman (gravida 1 : para 0) was referred at 24 weeks ' gestation after prenatal US performed at local clinics demonstrated pleural effusion. At our hospital, prenatal US revealed a huge, echogenic mass with

multiple variable sized cysts that occupied virtually all the left lower chest area (Fig. 1A). Both lungs were hypoplastic and the mediastinum was markedly displaced by the mass (Fig. 1B).

Color Doppler imaging revealed no systemic vessels, but coronal T2 weighted MR imaging demonstrated transdiaphragmatic anomalous systemic arterial supply to the lesion (Fig. 1C).

At 25 weeks ' gestation, the pregnancy was terminated; the fetus was male, and weighed 900gm.

A gross specimen obtained at autopsy showed a collapsed left lung, with a solid mass. The adjacent left diaphragm was supplied by an anomalous branch of the abdominal aorta. Histopathologically, the lesion demonstrated the classic features of Stocker type-III CCAM in extralobar BPS (Fig. 1D).

Discussion

Congenital cystic adenomatoid malformation is a rare benign pulmonary cystic disease. These lesions usually communicate with the tracheobronchial tree and derive their blood supply from the pulmonary circulation. In contrast, bronchopulmonary sequestration does not communicate with the tracheobronchial tree but has a separate, anomalous systemic blood supply.

CCAM has been associated with fetal hydrops and maternal polyhydramnios secondary to mass effect, as

¹Department of Radiology, Korea Veterans ' Hospital
Received August 17, 1999 ; Accepted December 17, 1999
Address reprint requests to : Wan Tae Kim, M.D., Department of Radiology,
Korea Veterans Hospital,
6-2 Dunchon-dong Kangdong-gu, Seoul, 134-060, Korea.
Tel. 82-2-2225-1426, Fax. 82-2-2225-1488

well as compression of the fetal mediastinum and heart (3), and in some cases of CCAM and many of extralobar pulmonary sequestration, shrinkage has been noted. It is therefore important to differentiate these lesions (4). Adzick et al. (1) reported that approximately 15% of CCAM lesions decreased in size during gestation, and that in most cases of extralobar pulmonary sequestration there was dramatic shrinkage.

Sonographically, pulmonary sequestration appears as a well-circumscribed, uniformly echogenic mass in the fetal thorax, though, detection by color Doppler ultrasonography of a systemic artery linking the aorta and

the fetal lung lesion is a pathognomonic feature of fetal extralobar pulmonary sequestration (2). On occasion, color Doppler ultrasonography fails to show the feeding systemic artery in the fetus, and echogenic microcystic CCAM and extralobar BPS can have an identical prenatal sonographic appearance (1). In our case, prenatal color Doppler sonography fail to demonstrate systemic arterial supply from the aorta, but coronal T2-weighted spin echo imaging clearly showed arterial supply to the mass.

Prenatal diagnosis of a mixed form of CCAM and BPS lesions is very difficult, though detection by color Dop-

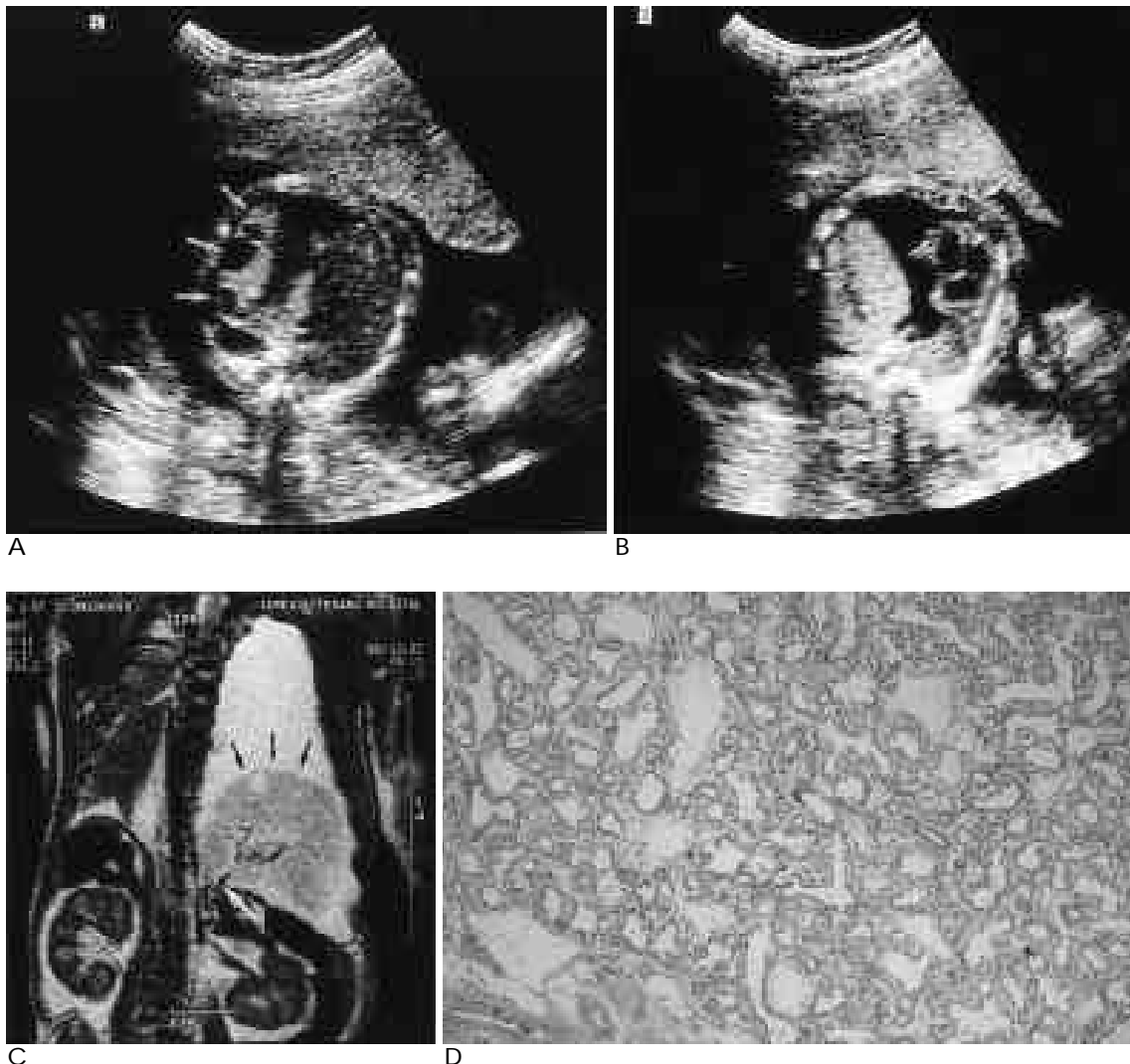


Fig. 1. A. Transverse sonogram of fetal chest shows a huge echogenic mass with multiple variable sized cyst (white arrows) that occupied the left lower chest. Left lung parenchyma is markedly collapsed and large amount pleural effusion is visible.

B. Transverse sonogram obtained caudal to 1a shows hypoplastic both lung and severely displaced mediastinum by the mass.

C. T2-weighted coronal spin echo MR image shows direct transdiaphragmatic anomalous systemic arterial supply to the lesion (white arrows) and intermediate signal intensity mass above the left diaphragm (black arrows).

D. Photomicrography of the resected mass.

This lesion show classic feature of type-III congenital cystic adenomatoid malformation including dilated, bronchiolelike airspaces (H & E stain, $\times 40$).

pler ultrasonography of systemic arterial blood supply from the aorta to the mass is a diagnostic indicator of echogenic fetal BPS (2). The mixed form of CCAM and BPS should be included in the differential diagnosis of fetal lung mass, and a careful search for systemic arterial vessels should be undertaken, especially when the mass is located contiguous to the diaphragm (5). Other differential diagnoses of fetal lung mass include bronchogenic cyst, congenital bronchial atresia and neuroenteric cyst (3).

For further characterization of a chest mass, MR imaging may be helpful. Hubbard et al. (6) reported that for the diagnosis of a fetal chest mass prenatal MR imaging is more accurate than prenatal US, and also provides additional valuable information such as the location of masses relative to the lobar anatomy of the lung. On MR images, BPS lesions show a well-defined homogenous high signal intensity mass, while CCAM lesions demonstrate a higher signal intensity than remaining normal lung, manifesting as either multiple large cysts with discrete walls or as more solid lesions with a few small cysts.

Both CCAM and BPS are thought to arise early in development, and their occurrence in the same patient reflects their similar embryological origins. Theoretically, an aberrant lung bud in the presence of abnormal mesenchyme might be caused by a combination of CCAM and BPS (5).

Primarily on the basis of cyst size, Stocker et al. defined three types of congenital cystic adenomatoid malformation: macrocystic, medium-sized cystic, and solid (7). Pathologically, a mixed form of CCAM and BPS showed the histological features of type-II or type-III C-

CAM (5, 8). In our case, type-III was histopathologically confirmed.

Prenatal sonography is assuming an increasingly important role in the detection of fetal lung mass and differential diagnosis, and prenatal MR imaging also provides additional valuable information for the diagnosis of fetal chest mass. When a well-circumscribed echogenic fetal lung mass is revealed by prenatal sonography, CCAM, BPS and the mixed form of CCAM and BPS must be included in the differential diagnosis.

References

1. Adzik NS, Harrison MR, Crombleholme TM, Flake AW, Howel LJ. Fetal lung lesions : management and outcome. *Am J Obstet Gynecol* 1998;179(4):884-889
2. Schulman MH, Stein SM, Neblett WW et al. Pulmonary sequestration : diagnosis with color Doppler sonography and a new theory of associated hydrothorax. *Radiology* 1991;180:817-821
3. Goldstein RB. *Ultrasound Evaluation of the Fetal Thorax*. In Callen PW. *Ultrasonography in obstetrics and gynecology*. Philadelphia : W.B.Saunders, 1994:340-343
4. MacGillivray TE, Harrison MR, Goldstein RB, et al. Disappearing fetal lung lesions. *J Pediatr Surg* 1993;28:1321-1325
5. Cass DL, Crombelholme TM, Howel LJ, Safford PW, Ruchelli ED, Adzik NS. Cystic lung lesions with systemic arterial blood supply : A hybrid of congenital cystic adenomatoid malformation and bronchopulmonary sequestration. *J Pediatr Surg* 1997;32(7):986-990
6. Hubbard AM, Adzick NS, Crombleholme TM, et al. Congenital chest lesions : diagnosis and characterization with prenatal MR imaging. *Radiology* 1999;212:43-48
7. Stocker TJ, Madewell JE, Drake RM. Congenital cystic adenomatoid malformation of the lung : classification and morphologic spectrum. *Hum Pathol* 1977;8:155-177
8. Schulman MH, Johnson JE, Holcomb III GW, Neblett III WW, Heller RM, Ambrosino MM. Retroperitoneal pulmonary sequestration : imaging findings, histopathologic correlation, and relationship to cystic adenomatoid malformation. *AJR* 1997;168:1277-1281

: 1 1

1

.

가

Stocker type-III

(1)

SIX-WEEK RADIOLOGIC PATHOLOGY COURSE

(2000 2 22 -3 1)

venue: Washington, DC, USA.

contact: Mr. Arnold Gittleston, Armed Forces Inst. of Pathology, 14th St. and Alaska Ave. N.W., Washington, D.C. 20306, USA.
(tel: 1-202-7822272; fax: 1-202-7828124
E-mail: gittleston@afip.osd.mil)

COURSE "IMAGING 2000": PROTOCOLS & PROCEDURES TO MEET THE NEW STANDARDS OF PRACTICE (2000 2 27 -3 3)

venue: Mauna Lani Bay Resort, Big Island of Hawaii, Hawaii.

contact: Marti Carter, CME Inc., 11011 W. North Avenue, Milwaukee, WI 53226, USA.
(tel: 1-877-2636459; fax: 414-7719520
E-mail: cmemilw@aol.com)

MR IMAGING: THE ESSENTIALS (INTRO/NOVICE LEVEL) (2000 2 28 -3 1)

venue: Uop Medical Center, Philadelphia, PA, USA.

contact: Melissa Zajdel, Univ. of PA Med. Ctr., MRI Ctr, 1 Founders Bldg., 3400 Spruce Street, Philadelphia, PA 19104, USA.
(tel: 1-215-6627825; fax: 1-215-3495925
E-mail: zajdel@oasis.rad.upenn.edu)

MEDITECH ASIA 2000-INTERNATIONAL EXHIBITION AND CONFERENCE ON MEDICAL, HOSPITAL EQUIPMENT AND SUPPLIES, INCORPORATING DENTAL ASIA 2000 (2000 3 1-4)

venue: Bangkok Int. Trade & Exh. Centre, Bangkok, Thailand.

contact: Sharon Lee, Project Manager, Hannover Fairs Asia Pte Ltd., 84 Amoy Street, 3rd floor, Singapore, Singapore 069903.
(tel: 65-2207633; fax: 65-2209733
E-mail: mta2000@hfasin.com)

IBUS-INTERNATIONAL BREAST ULTRASOUND SEMINAR (UNDER THE AUSPICES OF ECR 2000) (2000 3 4-5)

venue: Vienna, Austria.

contact: ECR Office, Neutorgasse 9/2A, A-1010 Vienna, Austria.
(tel: 43-1-5334064; fax: 43-1-53340649)

WORKSHOP RADIOLOGY FOR EMERGENCY & PRIMARY CARE PHYSICIANS (2000 3 4-11)

venue: Maui Marriott, Maui, Hawaii.

contact: Edith S. Bookstein, The Am. Inst. of Postgr. Educ., P.O. Box 2586, La Jolla, CA 92038, USA.
(tel: 1-619-4543212; fax: 1-619-4543556)

12TH EUROPEAN CONGRESS OF RADIOLOGY

(2000 3 5-10)

venue: Austria Centre, Vienna, Austria.

contact: ECR-Office, Neutorgasse 9/2A, A-1010 Vienna, Austria.
(tel: 43-1-5334064; fax: 43-1-5334064-9
E-mail: office@ecr.org)

COURSE RADIOLOGY UPDATE: BRAIN, BODY & BREAST (2000 3 6-10)

venue: The Silvertree Hotel, Snowmass, Colorado, USA.

contact: Janice Ford Benner, Univ. of PA Medical Center, 3400 Spruce Street, MRI Ctr., 1 Founders Bldg., Philadelphia, PA 19104, USA.
(tel: 1-215-6626904; fax: 1-215-3495925)

ANNUAL MEETING AND COURSE SOC. OF THORACIC RADIOLOGY: THORACIC IMAGING 2000 (2000 3 12-15)

venue: San Diego, CA, USA.

contact: Ms. Mary Ryals, Ryals & Associates, Inc., P.O. Box 1925, Roswell, GA 30077-1925, USA.
(tel: 1-770-6419773; fax: 1-770-5529859
E-mail: Webmaster@Ryalsmeet.com)

ANNUAL CONFERENCE OF THE SOCIETY OF GASTROINTESTINAL RADIOLOGISTS-ABDOMINAL RADIOLOGY ALLIANCE (2000 3 12-17)

venue: Hyatt Regency Kauai, Kauai, Hawaii.

contact: Karen Schmitt, Int. Meeting Managers, Inc., 4550 Post Oak Place, Suite 342, Houston, Texas 77027, USA.
(tel: 1-713-9650566; fax: 1-713-9600488
E-mail: imm@insync.net)

PRACTICAL TRAINING IN INTERVENTIONAL RADIOLOGY COURSE (2000 3 13-17)

venue: M.D. Anderson Cancer Center, Houston, TX, USA.

contact: Ken Wright, PhD, M.D. Anderson Cancer Center, Houston, Texas, USA.
(tel: 1-713-7922733; fax: 1-713-7453034
E-mail: kwright@di.mdacc.tmc.edu)

NEUROVASCULAR ULTRASOUND COURSE (2000 3 13-17)

venue: Winston-Salem, NC, USA.

contact: Wake Forest Univ. Sch. of Med., Center for Medical Ultrasound, Medical Center Boulevard, Winston-Salem, NC 27157-1039, USA.
(tel: 1-336-7164505; fax: 1-336-7164204
E-mail: cmu@wfubmc.edu)