

: 1 1

21

가

(1-3).

1

(Fig. 3).

21 가

2

가

2 10kg

가

가

가

12.8g/dL, 199,000/mm³, 6,400/mm³(
65%, 27%, 2%, 1%),
5mm/hr . IgE total(IRMA) 177.8IU/ml,

가

(Fig. 1).

가

(Fig. 2).

15

4 × 5cm

가

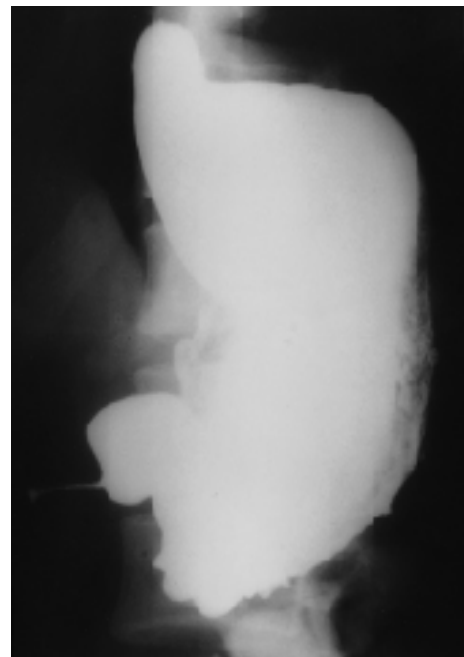


Fig. 1. UGI shows tumor-like obstruction in antrum with irregular contour change.

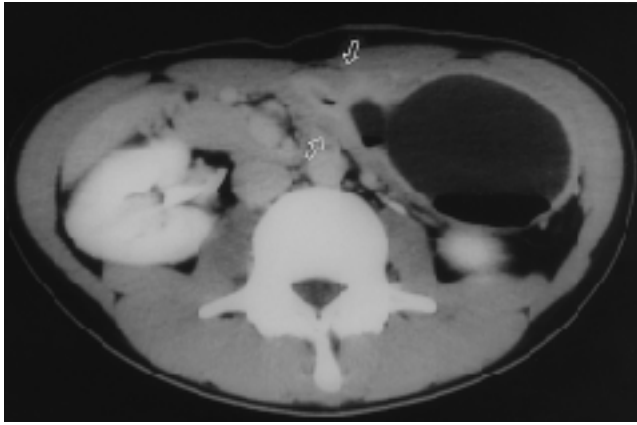


Fig. 2. Postcontrast CT scan shows marked submucosal thickening at antrum causing obstruction (arrows).

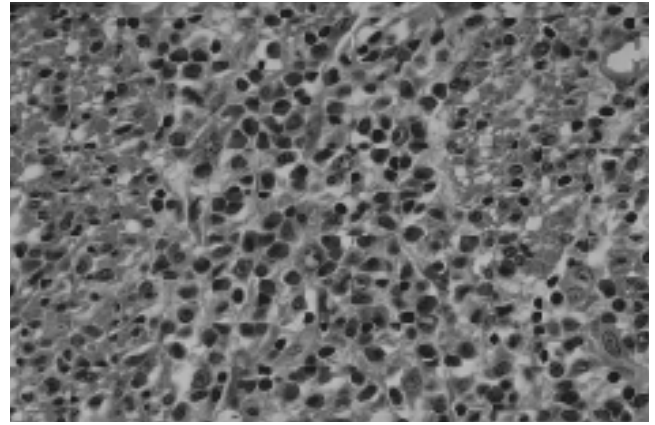


Fig. 3. Microscopic examination shows extensive transmural inflammation with dominance of mature eosinophils (H & E stain, $\times 400$).

가 50% (10-80%) (1-4). 가 (3). 가 (1), 가 (2), 가 (3-5), 가 (6-8), 가 (5-7). 가 (9) 64 15 (13%), 9 (14%),

8 (13%), 32 (50%) , Ureles (10) 가 25 18

Menetrier 가 (scirrhus) (5,7).

1. Edelman MJ, March JL. Eosinophilic gastroenteritis. *AJR* 1964;91: 773-778
2. Klein NC, Hargrove L, Sleisenger MH, et al. Eosinophilic gastroenteritis. *Medicine* 1970;49:299-319
3. Goldberg HI, O Kieffe D, Jenis EH, et al. Diffuse eosinophilic gastroenteritis. *AJR* 1973;119:342-351
4. Wehunt WD, Olmsted WW, Neiman HL, et al. Eosinophilic gastritis. *Radiology* 1976;120:85-89
5. MacCarty RL, Talley NJ. Barium studies in diffuse eosinophilic gastroenteritis. *Gastrointest Radiol* 1990;15:183-187
6. Stallmeyer MJB, Chew FS. Eosinophilic gastroenteritis. *AJR* 1993; 161:296
7. Herlinger H. *Malabsorption*. In Gore RM, Levine MS, Laufer I. *Textbook of gastrointestinal radiology*. 1st ed. Philadelphia: WB Saunders, 1994:880-882
8. Van Hoe L, Vanghillewe K, Baert AL, et al. CT findings in nonmucosal eosinophilic gastroenteritis. *J Comput Assist Tomogr* 1994;18: 818-820
9. 1995;48:347-358
10. Ureles AL, Alchibaja T, Lodico D, Stabins SJ. Idiopathic eosinophilic infiltration of the gastrointestinal tract, diffuse and circumscribed: a proposed classification and review of the literature, with two additional cases. *Am J Med* 1961;30:899-909

Diffuse Eosinophilic Gastroenteritis with Antral Obstruction : A Case Report¹

Sung Hee Moon, M.D., Young Bok Kim, M.D., Koung Hee Lee, M.D.

¹Department of Radiology, National Police Hospital

Eosinophilic gastroenteritis is a rare disease characterized by tissue eosinophilia that can involve different layers of the gut wall and cause various gastrointestinal symptoms. We describe the UGI and CT findings of a case of diffuse eosinophilic gastroenteritis with tumor-like antral obstruction due to thickening of the submucosa and muscle layer in a 21-year-old male.

Index words : Gastrointestinal tract, inflammation
Gastrointestinal tract, CT

Address reprint requests to : Sung Hee Moon, M.D., Department of Radiology, National Police Hospital.
58, Karakbon-dong, Songpa-ku, Seoul 138-169, Korea.
Tel. 82-2-3400-1318 Fax. 82-2-408-4547

: 2000 4 22 () 13:30-17:00

: A, B Hall

15-2

Tel (0561) 741-8100

	(2000 3 15)	(2000 3 15)
	10,000	15,000
	15,000	20,000

, Home Page ,
Fax .

: : 025-01-0001-042 :

: Home Page .

: Radiological Embryology

1:00 -		
1:30 - 1:45	Introduction	()
1:45 - 2:15	Central Nervous System	()
2:15 - 2:45	Cardiovascular System	()
2:45 - 3:15	Respiratory System	()
3:15 - 3:30		
3:30 - 4:00	Digestive System	()
4:00 - 4:30	Urogenital System	()
4:30 - 5:00	Musculoskeletal System	()