

CT MR : 1

2 3

(dermoid hairy polyp)

1

CT MR

가 ,

CT MR

CT MR

가

3 가

(1).

(, , ,)

가

CT (Fig. 1A)

(stalk)

MR T1 - (Fig. 1B) T2 -

(Fig. 1C)

(2).

(Fig. 1D).

(1 - 5).

가

(unilateral nostril

1D).

(Fig.

drainage)

(3, 4, 5),

(2, 5),

(1, 5)

가

2.5 × 1.5 cm

(Fig. 1E, F)

(ankyloglossia),

(facial hemihypertrophy),

(left caro - tid artery atresia),

(osteopetrosis)

(5).

가 (6).

¹가

²가

³가

1999 가

가

1999 12 18

2000 5 2

가

,

가

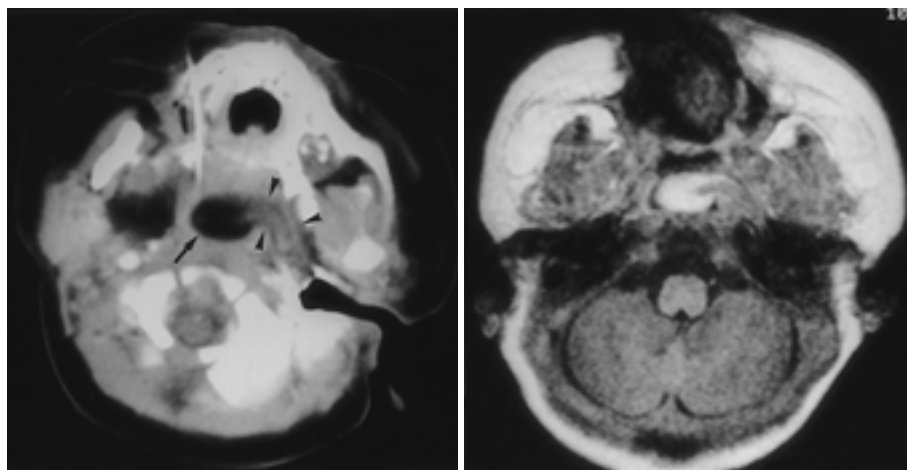
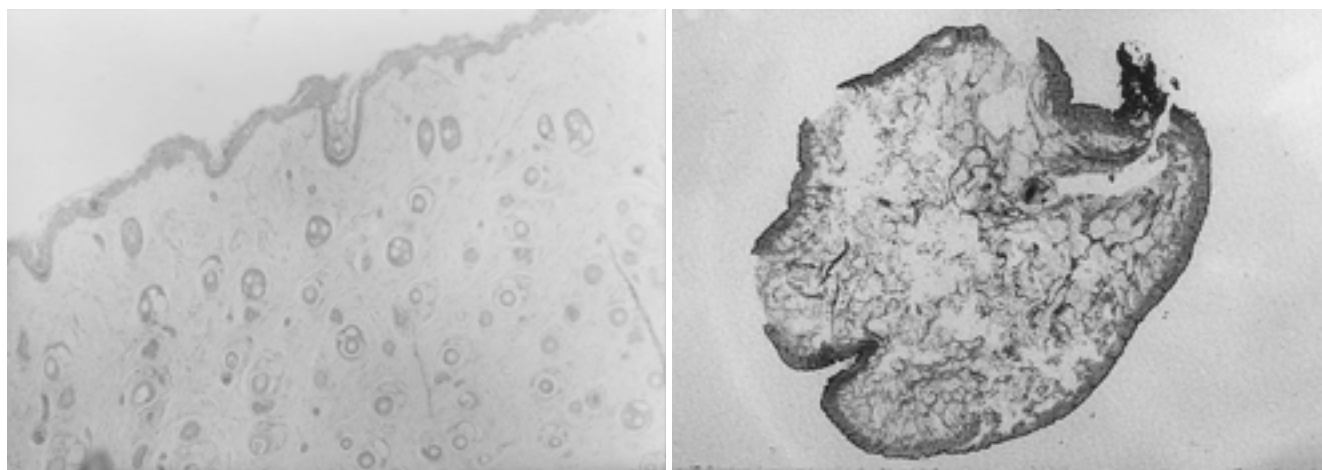
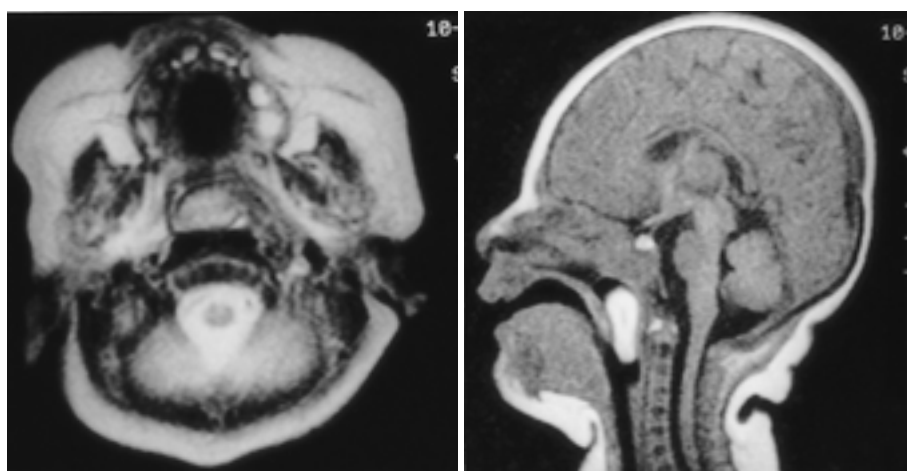


Fig. 1. Post contrast CT scan (**A**) shows a low density polyp (arrow) with pedicle (arrowheads) arising from left lateral wall of the nasopharynx. This polyp is high signal intensity on T1WI (**B**) and T2WI (**C**). It is not enhanced after infusion of the contrast media except for pedicle (not shown). Obstruction of the naso- and oro-pharyngeal air-way and no intracranial communication are well demonstrated on sagittal T1WI (**D**). Microphotograph shows that a polyp have a surface of mature keratinised stratified squamous epithelium with hair follicles and sebaceous glands ($\times 40$) (**E**). Adipose tissue and fibrous septa are found in the central portion of a polyp ($\times 5$) (**F**).



(Fig. 1A) , T1 - T2 -
(Fig. 1 A, B) , MR 가
(Fig. 1D).
MR . CT MR

- J Pediatr* 1985;143:209-210
2. Mitchell TE and Girling AC. Hairly polyp of the tonsil. *J Laryngol Otol* 1996;110:101-103
3. Kelly A, Bough ID, Luft JD, Conard K, Reilly JS, Tuttle D. Hairly polyp of the oropharynx: case report and literature review. *J Pediatric Surg* 1996;31(5):704-706
4. Kochanski SC, Burton EM, Seidel FG, Chanin LR, Hensley S, Acker JD. Neonatal nasopharyngeal hairy polyp: CT and MR appearance. *J Comput Assist Tomogr* 1990;14(6):1000-1001
5. McShane D, Sherif E, Doyle-Kelly W, Fennell G, and Waish M. Dermoid (hairy polyps) of the oro-nasopharynx. *J Laryngol Otol* 1989;103:612-615
6. Chaudhry AP, Lore JM, Fisher JF, Gambrino AG. So-called hairy polyps or teratoid tumors of the nasopharynx. *Arch Otolaryngol* 1978; 104:517-525

1. Simpson RM, Sorbie AL, McLay KA, Duffty P, and Lloyd DJ. Pharyngeal dermoid leading to respiratory failure in a neonate. *Eur*

J Korean Radiol Soc 2000;42:999 - 1001

CT and MR Findings of Neonatal Dermoid (" Hairy Polyp ") Developed at Eustachian Tube: A Case Report¹

Yeun Joo Jung, M.D., So Lyung Jung, M.D., Hei Sook Jang, M.D.², Youn Soo Lee, M.D.³,
Sang Hoon Lee, M.D., Sung Soo Hwang, M.D., Young Ha Park, M.D.

¹Department of Radiology, St. Vincent 's Hospital, The Catholic University of Korea

²Department of Radiology, Kangnam St. Mary 's Hospital, The Catholic University of Korea

³Department of Clinical Pathology, Kangnam St. Mary 's Hospital, The Catholic University of Korea

Nasopharyngeal dermoid is a rare disease which in neonates leads to respiratory failure. We report the CT and MR imaging findings of a case of neonatal dermoid which developed in the Eustachian tube. The neonate involved was referred to our hospital because of respiratory difficulties and cyanosis.

Index words : Nasopharynx
Dermoid
Computed tomography (CT), in infants and children
Magnetic resonance (MR), in infants and children

Address reprint requests to : So Lyung Jung, M.D., Department of Radiology, St. Vincent 's Hospital, The Catholic University of Korea.
93, Chi-dong, Paldal-ku, Suwon, Kyunggi-do 442-723, Korea.
Tel. 82-31-249-7484 Fax. 82-31-247-5713 E-mail: jsl6288@medikorea.net

**ULTRASOUND 2000: 1ST INTERNATIONAL
ULTRASOUND SYMPOSIUM (2000 9 10-14)**

venue: Gazi University, Istanbul, Turkey.
contact: Valör Tourism and Travel Ag., Portakalçiçeği Sokak
2/7, A, Ayrancı, 06690 Ankara, Turkey.
(tel: 90-312-4402490/4409758; fax: 90-312-4474610)

**ANNUAL CONFERENCE OF THE INTERNATIONAL
IMAGING SCIENCE AND TECHNOLOGY SOCIETY
(2000 9 11-14)**

venue: Montreal, QC, USA.
contact: Pam Forness, 7003 Kilworth LA, Springfield, VA
22151, USA
(tel: 1-703-6429090; fax: 1-703-6429094)

**17TH ANNUAL MEETING EUROPEAN SOCIETY FOR
MAGNETIC RESONANCE IN MEDICINE AND BIOLOGY
(2000 9 14-17)**

venue: Palais des Congrès, Paris, France.
contact: ESMRMB Secretariat, Neutorgasse 9/2a, A-1010
Vienna, Austria.
(tel: 43-1-5351306; fax: 43-1-5357041;
E-mail: office@esmrmmb.org)

**NICER HORIZON COURSE ADVANCED CHEST IMAGING
(2000 9 15-17)**

venue: Churchill College, Cambridge, United Kingdom.
contact: Britt D. Olsen, Course Secretary NICER,
The NICER Inst., P.O. Box 4220 Torshov, N-0401
Oslo, Norway.
(tel: 47-23185118/5867; fax: 47-23186015)

**THE UNIVERSITY OF UTAH DEPARTMENT OF
RADIOLOGY FIFTH ANNUAL INTENSIVE INTERACTIVE
HEAD AND NECK IMAGING COURSE
(2000 9 15-17)**

venue: University of Utah, Salt Lake City, Utah, USA.
contact: CME, The University of Utah, School of Medicine,
Rm 1C117, 50 North Medical Drive, Salt Lake City,
Utah 84132, USA.
(tel: 1-801-5818664; fax: 1-801-5812647)

VANCOUVER IMAGING UPDATE (2000 9 15-22)

venue: Pan Pacific Hotel, Vancouver, B.C., Canada.
contact: Dr. Peter L. Cooperberg, Radiology Dept., St.
Paul's, 1081 Burrard Street, Vancouver, B.C.,
Canada.
(tel: 1-604-6315026; fax: 1-604-6315283;
E-mail: cooperb@unixg.ubc.ca)

**SIX-WEEK RADIOLOGIC PATHOLOGY COURSE
(2000 9 18-27)**

venue: Washington, DC, USA.
contact: Mr. Arnold Gittleson, Armed Forces Inst. of
Pathology, 14th St. and Alaska Ave. N.W.,
Washington D.C. 20306, USA.
(tel: 1-202-7822272; fax: 1-202-7828124)

**ANNUAL MEETING AMERICAN OSTEOPATHIC COLLEGE
OF RADIOLOGY (2000 9 20-24)**

venue: Princess Hotel, Scottsdale, Az, USA.
contact: Rhonda Boehner, 119 E 2nd Street, Milan, MO
63556, USA.
(tel: 1-816-2654011; fax: 1-816-2653494)

**SECOND INTERNATIONAL CONGRESS ON MR -
MAMMOGRAPHY (2000 9 21-23)**

venue: Fr. Schiller University, Jena, Germany.
contact:
(fax: 49-3641-934038;
E-mail: mrm2000@bach.med.uni-jena.de)

**ESUR 2000: 7TH EUROPEAN SYMPOSIUM ON
UROGENITAL RADIOLOGY (2000 9 22-24)**

venue: Royal College of Physicians, London, United
Kingdom.
contact: Dr. Judith A.W. Webb, M.D., St. Bartholomew's
Hosp., West Smithfield, London ECLA 7BE, United
Kingdom.
(tel: 44-171-6018864; fax: 44-171-6018868;
E-mail: jk Jessop@mds.qmw.ac.uk)

**ANNUAL MEETING AMERICAN COLLEGE OF
RADIOLOGY (2000 9 23-27)**

venue: Hilton Hotel, New York, NY, USA.
contact: Barbara Rapp, 1891 Preston White Drive, Reston,
VA 22091, USA.
(tel: 1-703-6488900; fax: 1-703-7164487)

**3RD CONFERENCE ASIAN PACIFIC ASSOCIATION FOR
MEDICAL INFORMATICS (2000 10)**

venue: Hong Kong, Hong Kong.
contact: Dr. Sarah McGhee, dept. of Community Medicine,
7 Sassoon Road, Hong Kong, Hong Kong.
(tel: 852-28199193; fax: 852-28559528;
E-mail: smmcghee@hkucc.hku.hk)

**ANNUAL MEETING SOCIETY OF RADIOLOGISTS IN
ULTRASOUND (2000 10)**

venue: Chicago, IL, USA.
contact: Suzanne Bohn,
1891 Preston White Drive, Reston, VA 20191, USA.
(tel: 1-703-6488997; fax: 1-703-2629313)

**ESDIR SEMINAR: THE IMPACT OF IT AND COMPUTER
TECHNOLOGY ON THE FUTURE OF IMAGING
(2000 10)**

venue: Istanbul, Turkey.
contact: T.E.A.M., Rookery House,
The Rookery, Newmarket, Suffolk CB8 8EQ,
United Kingdom.
(tel: 44-1638-660220; fax: 44-1638-660202;
E-mail: esdir@team-events.co.uk)