

## Migrating Pieces of Glass in the Pleural Cavity Causing Chronic Chest Pain : A Case Report<sup>1</sup>

Jong Chul Kim, M.D.

A case in which broken pieces of glass are able to move freely in the pleural cavity without causing fatal or severe injury is very rare. I describe a case in which two pieces of glass which had penetrated the pleural cavity of a 14-year-old boy were surgically removed. Initial chest radiograph showed two crossed opacities in the right lateral chest wall around the minor fissure, while follow-up chest radiographs revealed migration of a vertical piece of glass to the right lower lateral thorax and finally to the right lower medial thorax.

**Index words :** Children, respiratory system  
Foreign bodies

Penetrating chest wounds due to fragments of glass may occur in falls and motor vehicle accidents. When a person inadvertently crashes into a plate glass door or window, injuries develop more frequently in the extremities or abdomen than in the thorax (1). I recently experienced a case in which two movable pieces of glass had penetrated the pleural cavity of a 14-year-old boy. I describe a rare case in which pieces of glass in the pleural cavity of this pediatric patient caused only chronic chest pain and were surgically removed.

### Case Report

A 14-year-old boy was admitted due to chronic recurrent pain in the right chest. Eighty-two days earlier he accidentally crashed into a plate glass door; the glass shredded causing a deep, 2 cm-long laceration with a surrounding hematoma in the right 6th posterior intercostal space, medial to the right posterior axillary line.

An initial chest radiograph showed "X"-like crossed opacities in the right lateral chest wall around the minor fissure (Fig. 1A). Inadvertently a simple suture was used to close the laceration.

Despite satisfactory healing, the patient suffered intermittent dull pain in his right chest, and 81 days after the initial injury, visited another local clinic. A subsequent chest radiograph showed a 3 cm-long bullet-like radiopacity in the vicinity of the minor fissure, and another 2 cm-long transversely lying lentiform radiopacity on the lateral side of the thorax (Fig. 1B). In order to remove the two radiopaque foreign bodies, the patient was readmitted. Comparison of the initial chest radiograph (Fig. 1A) with the one obtained at the local clinic (Fig. 1B) revealed migration of one object to the right lower lateral thorax. The third chest radiograph obtained with safety pin marking on the right upper back showed further migration of the object to the medial side of the right lower thorax (Fig. 1C) in comparison with the chest radiograph taken at the local clinic (Fig. 1B).

Thoracotomy revealed a bullet-like piece of glass in the minor fissure with surrounding inflammatory reaction, and another slender glass fragment in the mediastinal pleural cavity near the right inferior pulmonary ligament. The former was fixed in the minor fissure without adhesion to the lung parenchyma, while the latter was

<sup>1</sup>Department of Diagnostic Radiology, Chungnam National University Hospital  
Received September 27, 1999; Accepted December 13, 1999  
Address reprint requests to : Jong Chul Kim, M.D., Department of Diagnostic Radiology, Chungnam National University Hospital, #640 Daesa-dong, Jung-ku, Taejeon, 301-721, Korea.  
Tel: 82-42-220-7835 Fax: 82-42-253-0061  
E-mail: jckim@cnuh.co.kr

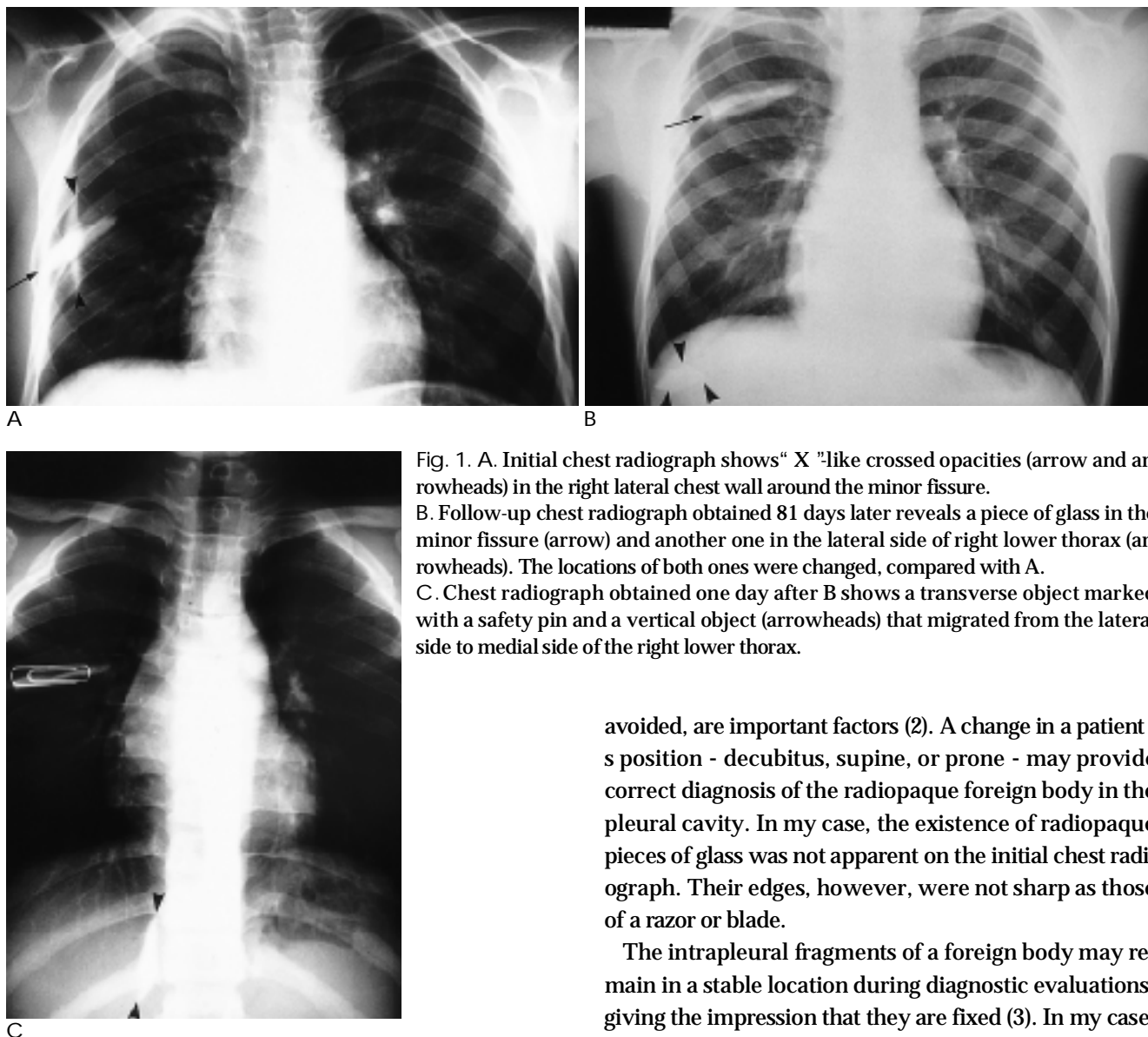


Fig. 1. A. Initial chest radiograph shows "X"-like crossed opacities (arrow and arrowheads) in the right lateral chest wall around the minor fissure. B. Follow-up chest radiograph obtained 81 days later reveals a piece of glass in the minor fissure (arrow) and another one in the lateral side of right lower thorax (arrowheads). The locations of both ones were changed, compared with A. C. Chest radiograph obtained one day after B shows a transverse object marked with a safety pin and a vertical object (arrowheads) that migrated from the lateral side to medial side of the right lower thorax.

able to move freely in the pleural cavity. Their edges were not sharp, and they did not penetrate the adjacent lung, heart, or other thoracic structures. They were removed without difficulty. During the recent follow-up period of more than two months, the patient's condition was good.

### Discussion

Most glass fragments, regardless of their lead content, are visible on simple radiographs. With regard to recognition, the size of a glass fragment, the orientation of its greatest dimension relative to the direction of the x-ray beam, and the appropriate positioning of the surrounding bony structure in such a way that superimposition is

avoided, are important factors (2). A change in a patient's position - decubitus, supine, or prone - may provide correct diagnosis of the radiopaque foreign body in the pleural cavity. In my case, the existence of radiopaque pieces of glass was not apparent on the initial chest radiograph. Their edges, however, were not sharp as those of a razor or blade.

The intrapleural fragments of a foreign body may remain in a stable location during diagnostic evaluations, giving the impression that they are fixed (3). In my case, a piece of glass in the pleural cavity adjacent to the minor fissure seemed to be fixed, but it also migrated slightly to the medial side. Another piece migrated from the right lateral pleural cavity around the minor fissure to the lateral side of the right lower pleural cavity, and finally migrated to the medial side of the right lower mediastinal pleural cavity adjacent to the right inferior pulmonary ligament. The minor fissure and the inferior pulmonary ligament might, therefore, act as a barrier to these two mobile pieces of glass.

Broken pieces of glass that are able to move freely in the pleural cavity may induce either severe complications such as dissection, perforation, hemorrhage and inflammation, or minor complications such as chronic chest pain. A mobile pleural foreign body that is poorly managed and not extracted can cause chronic chest pain (3). In my case, however, the nature and location of two


pieces of glass causing chronic chest pain were apparent on chest radiographs, so open thoracotomy was performed.

In conclusion, pieces of glass in the pleural cavity might cause chronic chest pain, and in the case described, recognition of migrating foreign bodies by sequential chest radiographs led to correct diagnosis.

## References

1. Murphy GK. A single fatal penetrating chest wound from shattered wind-blown glass. *Am J Forens Med Pathol* 1985;6:322-335
2. Silverman FN. *The limbs*. In Silverman FN, Kuhn JP, Berdon WE, et al, eds. *Caffey's pediatric X-ray diagnosis*, 9th ed. St Louis: Mosby, 1993:1448-1449
3. Demmy TL, Schmaltz R, Walls JT, Curtis JJ. Unrecognized intrapleural missile-a rare cause of chronic pain following gunshot wounds: case report. *J Trauma* 1994;36:433-435.

2000;42: 537- 539



(1)

**23RD ANNUAL WINTER SKELETAL SYMPOSIUM:  
MUSCULOSKELETAL MRI (2000 3 13-17 )**

venue: Sun Valley, Idaho, USA.  
contact: Janice Ford Benner, Hosp. of the Univ. of PA,  
MRI Ctr., 3400 Spruce Street, 1 Founders Bldg.,  
Philadelphia, PA 19104, USA.  
(tel: 1-215-6626904; fax: 1-215-3495925)

**TRANSCRANIAL DOPPLER COURSE**

**(2000 3 16-17 )**

venue: Winston-Salem, NC, USA.  
contact: Wake Forest Univ. Sch. of Med., Center for Medical  
Ultrasound, Medical Center Boulevard, Winston-  
Salem, NC 27157-1039, USA.  
(tel: 1-336-7164505; fax: 1-336-7164204  
E-mail: cmu@wfubmc.edu)

**1ST ANNUAL VASCULAR IMAGING WORKSHOP:  
VASCULAR IMAGING IN THE NEW MILLENNIUM**

**(2000 3 18-25 )**

venue: Hotel Alpenrose, Zürs/Arlberg, Austria.  
contact: Frau Sandner, Univ.-Klinik f.Radiodiagnostik,  
AKH, A-1090 Vienna, Austria.  
(tel: 43-1-404004893; fax: 43-1-404004894  
E-mail: siegfried.thurnher@univie.ac.at)

**COURSE MRI UPDATE (BODY MR AND VASCULAR  
TOPICS) (2000 3 20-24 )**

venue: Vail, Colorado, USA.  
contact: Janice Ford Benner, Univ. of PA Med. Center,  
MRI Ctr., 3400 Spruce Street, 1 Founders Bldg.,  
Philadelphia, PA 19104, USA.  
(tel: 1-215-6626904; fax: 1-215-3495925)

**43RD ANNUAL DIAGNOSTIC RADIOLOGY  
POSTGRADUATE COURSE (2000 3 20-24 )**

venue: The Fairmont Hotel & Tower, San Francisco, CA,  
USA.  
contact: UCSF, Univ. of CA School of Medicine, 3333  
California St., Suite 375, San Francisco,  
CA 94143-0629, USA.  
(tel: 1-415-4765731; fax: 1-415-4769213  
E-mail: cme@radiology.ucsf.edu)

**SALMED-INTERNATIONAL TRADE FAIR OF MEDICAL  
EQUIPMENT (2000 3 21-24 )**

venue: Fairgrounds, Poznan, Poland.  
contact: Ms. Agnieszka Malicka, Poznan International Fair  
Ltd., Glogowska 14, 60-734 Poznan, Poland.  
(tel: 48-61-8666312; fax: 48-61-8660643)

**10TH CONGRESS ASEAN ASSOCIATION OF  
RADIOLOGY (AAR) (2000 3 22-25 )**

venue: Bangkok, Thailand.  
contact: Saroj Vanapruks, M.D., Royal Golden Jubilee Bldg.,

9th floor, 2 Soi Soonvijai, New Petchburi RD.,  
Huay Kwang, Bangkok 10320, Thailand.  
(tel: 66-2-7165963; fax: 66-2-7165964)

**ONCOLOGY 2000: FROM MOLECULES TO  
MANAGEMENT (2000 3 23-24 )**

venue: Royal Plaza Hotel, Kowloon, Hong Kong.  
contact: Ms. Gigi Lui, Dept. of Clinical Oncology, Prince of  
Wales Hospital, Shatin, N.T., Hong Kong SAR.  
(tel: 852-26322119/26322144; fax: 852-26497426  
E-mail: gigilui@cuhk.edu.hk)

**25TH ANNUAL MEETING SOC. OF CARDIOVASCULAR  
AND INTERVENTIONAL RADIOLOGY**

**(2000 3 25-30 )**

venue: San Diego Convention Ctr., San Diego, CA, USA.  
contact: SCVIR, 10201 Lee Highway, Suite 500,  
Fairfax, VA 22030, USA.  
(tel: 1-703-6911805; fax: 1-703-6911855)

**COURSE ORTHOPEDIC RADIOLOGY**

**(2000 3 27-29 )**

venue: Ritz Carlton, Boston, MA, USA.  
contact: Danielle Pokorski, Dept. of Radiology,  
75 Francis Street, Boston, MA 02115, USA.  
(tel: 1-617-7326265; fax: 1-617-7326509)

**PERIPHERAL VASCULAR ULTRASOUND COURSE**

**(2000 3 27-30 )**

venue: Winston-Salem, NC, USA.  
contact: Wake Forest Univ. Sch. of Med., Center for Medical  
Ultrasound, Medical Center Boulevard, Winston-  
Salem, NC, USA.  
(tel: 1-336-7164505; fax: 1-336-7164204  
E-mail: cmu@wfubmc.edu)

**COUNCIL ON DIAGNOSTIC IMAGING (2000 4 )**

venue: Marriott Hotel, Schaumburg, IL, USA.  
contact: Dr. Lawrence Pyzik, P.O. Box 25, Palatine,  
IL 60078-0025, USA.  
(tel: 1-847-7051177; fax: 1-847-7051178)

**MEETING ON CARDIAC MRI AND MR ANGIOGRAPHY  
(2000 4 )**

venue: London, United Kingdom.  
contact: Kitti Kottasz, BIR, 36 Portland Place,  
London WIN 4AT, United Kingdom.  
(tel: 44-171-3071429; fax: 44-171-3071414)

**MEETING ON TECHNOLOGICAL ADVANCES IN  
ULTRASOUND (2000 4 )**

venue: United Kingdom.  
contact: Kitti kottasz, BIR, 36 portland Place,  
London WIN 4AT, United Kingdom.  
(tel: 44-171-3071429; fax: 44-171-3071414)