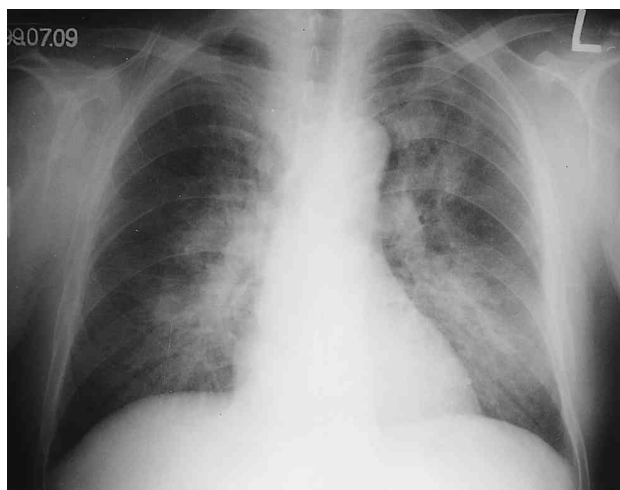
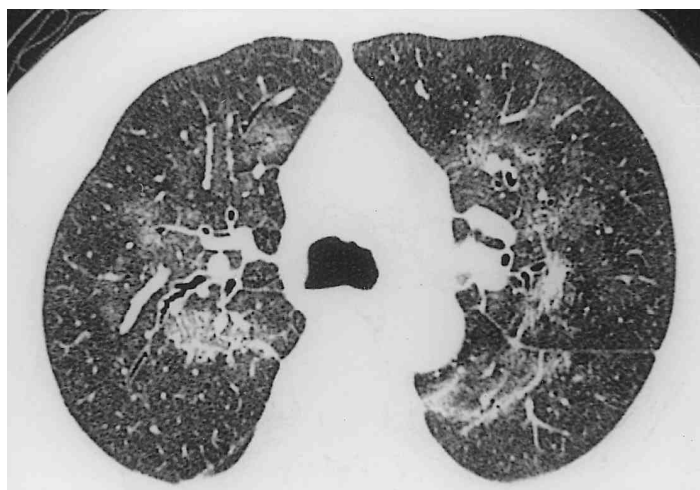


가
가
1 CT
(acquired immunodeficiency syndrome, AIDS)
(Pneumocystis carinii) 가
AIDS 가
(1). 1A). CT (Fig.
(cytomega- lovirus, (Figs. 1B and
CMV) (mycobacterium) 1C).
(Kaposi sarcoma) AIDS
(diffuse alveolar damage) 가
AIDS
(nonspecific intersti-
tial pneumonitis, NIP) CT
(2). 가
AIDS NIP
CT AIDS
(NIP)
61 가 2 , 가
3 10
trimethoprim-sulfamethoxazole(TMP-SMX) 5

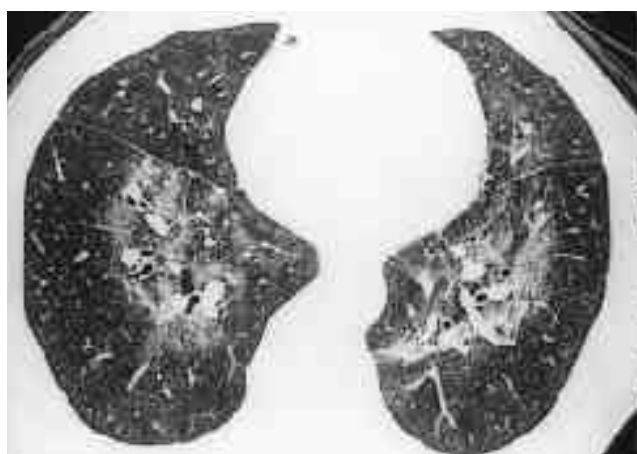
:
 Suffredini NIP
 (3). AIDS AIDS 38%
 (5).
 (3,4).
 가
 가
 가 AIDS 가
 가
 NIP, (lymphocytic interstitial pneumo-
 nia), (bullous lung disease), (2,5). (air-space opacity) NIP
 (bronchiolitis obliterans) NIP AIDS (ple- ural effusion) (2).
 가 (5, 6). (7). CT



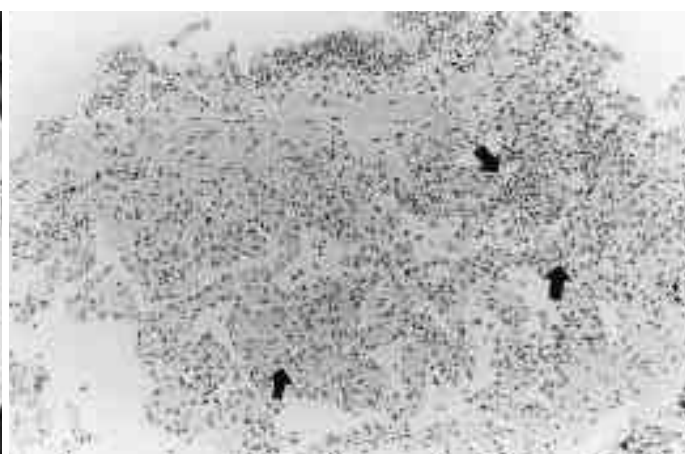
A



B



C



D

Fig. 1. Nonspecific interstitial pneumonitis in a 61-year-old man with AIDS

A. Chest radiograph shows bilateral symmetric consolidation and ground glass opacity in a perihilar and central distribution.

B, C. Thin-section CT scans at carina level (B) and lung bases (C) obtained 2 days after A show bilateral mixed ground-glass opacity and reticulonodular opacity with a peribronchovascular distribution. Peripheral lung regions are relatively preserved.

D. Photomicrograph of transbronchial lung biopsy specimen shows a mild interstitial lymphocytic infiltration (arrows) (H and E, $\times 40$).

가

(8). CT

(interlobular septum)

(9). 1/3

(10). Peta-midine

Pentamidine

(11). 가

(11). NIP CT

가

NIP CT

가 (9). AIDS

NIP

(diffuse alveolar damage)

(12).

NIP

NIP

. CMV, HIV, EBV(Ebstein-Barr virus)

HIV

NIP가

가 (12). NIP

- (13). AIDS
- CT
- NIP
1. Gruden JF, Huang L, Turner J, et al. High-resolution CT in the evaluation of clinically suspected *Pneumocystis carinii* pneumonia in AIDS patients with normal, equivocal, or nonspecific radiographic findings. *AJR* 1997; 169: 967-975
 2. Simmons JT, Suffredini AF, Lack EE, et al. Nonspecific interstitial pneumonitis in patients with AIDS: radiologic features. *AJR* 1987; 149:265-268
 3. Miller R. HIV-associated respiratory diseases. *Lancet* 1996;348: 307-312
 4. White DA, Matthay RA. Noninfectious pulmonary complications of infection with the human immunodeficiency virus. *Am Rev Respir Dis* 1989;140:1763-1787
 5. Suffredini AF, Ognibene FP, Lack EE, et al. Nonspecific interstitial pneumonitis: a common cause of pulmonary disease in the acquired immunodeficiency syndrome. *Ann Intern Med* 1987;107:7-13
 6. McGuinness G. Changing trends in the pulmonary manifestations of AIDS. *Radiol Clin North Am* 1997; 35:1029-1082
 7. Sattler F, Nichols L, Hirano L, et al. Nonspecific interstitial pneumonitis mimicking *Pneumocystis carinii* pneumonia. *Am J Respir Crit Care Med* 1997;156:912-917
 8. Kuhlman JE. *Pneumocystis* infections: the radiologist's perspective. *Radiology* 1996;198:623-635
 9. Bergin CJ, Wirth RL, Berry GJ, Castellino RA. *Pneumocystis carinii* pneumonia: CT and HRCT observations. *J Comput Assist Tomogr* 1990;14:756-759
 10. Chow C, Templeton PA, White CS. Lung cysts associated with *Pneumocystis carinii* pneumonia: radiographic characteristics, natural history, and complications. *AJR* 1993; 161:527-531
 11. Boisselle PM, Crans CA, Kaplan MA. The changing face of *Pneumocystis carinii* pneumonia in AIDS patients. *AJR* 1999;172: 1301-1309
 12. Travis WD, Fox CH, Devaney KO, et al. Lymphoid pneumonitis in 50 adult patients infected with the human immunodeficiency virus: lymphocytic interstitial pneumonitis versus nonspecific interstitial pneumonitis. *Hum Pathol* 1992;23:529-541
 13. Griffiths MH, Miller RF, Semple SJG. Interstitial pneumonitis in patients infected with the human immunodeficiency virus. *Thorax* 1995;50:1141-1146

Nonspecific Interstitial Pneumonitis in a Patient with Acquired Immunodeficiency Syndrome : A Case Report¹

Hyun Soon Pyo, M.D.², Yu-Whan Oh, M.D., Kyoung-Mi Moon, M.D.,
Eun-Young Kang, M.D., Han Kyeom Kim, M.D.³

¹*Department of Diagnostic Radiology, Korea University Medical School*

²*Department of Diagnostic Radiology, Kwangmyong Sungae Hospital*

³*Department of Pathology, Korea University Medical School*

A variety of pulmonary complications, including infection and neoplastic and inflammatory diseases, commonly develop in patients with acquired immunodeficiency syndrome. Nonspecific interstitial pneumonitis, one such complication, is not uncommon, and is very difficult to differentiate, clinically and radiologically, from *Pneumocystis carinii* pneumonia. We describe a case of nonspecific interstitial pneumonitis, including the chest radiographic and HRCT findings, occurring in an AIDS patient and involving complications.

Index words : Lung, diseases

Lung, interstitial disease

Lung, CT

Acquired immunodeficiency syndrome (AIDS)

Address reprint requests to : Yu-Whan Oh, M.D., Department of Diagnostic Radiology, Korea University Hospital
#126-1, 5-Ka, Anam-Dong, Sungbuk-Ku, Seoul, 136-705, Korea
Tel: 82-2-920-5657 Fax: 82-2-929-3796 E-mail: yuwhan@medikorea.net