

Transjugular Intrahepatic Portosystemic Shunt with PTFE-Covered Spiral Z-stent: An Experimental Study in Swine¹

Hyung Jin Shim, M.D., Jae Ryang Juhn, M.D.², Young Soo Do, M.D.³, In Sup Song, M.D., Yang Soo Kim, M.D., Kyioshi Nishimine, M.D.⁴, Barry Uchida, B.S.⁵, Josef Rösch, M.D.⁵

Purpose : To improve TIPS patency by inserting polytetrafluoroethylene(PTFE)-covered spiral Z-stents in swine.

Materials and Methods : Using PTFE covered spiral Z-stents lined with TIPS tract from the portal vein wall to the inferior vena caval orifice of the right hepatic vein, TIPS were created in seven young swine. The animals were followed up by portal venography and venous pressure was measured at two-week intervals for 12 weeks or until shunt occlusion. After sacrifice, resected liver was examined grossly and prepared for histology.

Results : The fifty percent patency rate using lifetime analysis was 83 % at 4 weeks, 33 % at 6 weeks, 17 % at 8 weeks and 0 % at 10 weeks. Venography demonstrated that the predominant sites of stenosis were the portal vein wall(2/6), the TIPS tract(2/6) and the IVC orifice of the right hepatic vein(2/6). One swine died 11 days after TIPS due to illness, and bile leaks were discovered in two of the seven animals. Histologic study demonstrated intimal hyperplasia in either the portal vein wall or the end of the stent at which the IVC orifice was located, as well as thrombus and pseudointimal hyperplasia in the TIPS tract.

Conclusion : PTFE-covered spiral Z-stents were easily placed and significantly improved TIPS patency.

Index words: Liver, interventional procedure
Shunts, portosystemic
Stents and prostheses

The transjugular intrahepatic portosystemic shunt (TIPS) has proved to be an effective and relatively safe

nonsurgical and nonendoscopic means of decompressing the portal venous system and controlling active variceal bleeding (1-3). The patency rate of a TIPS tract is good in the short term, but after 3-6 months, late shunt malfunction occurs due to delayed stenosis which can arise in the parenchymal tract or at the portal and hepatic vein sites as intimal and/or pseudointimal hyperplasia(PIH). The reported rates of shunt stenosis within 6 months range from 17 % to 50 % of patients(4-6).

Bile leakage in the shunt tract can also occur and may contribute to thrombus formation leading to early shunt malfunction(7-11). Though the deployment of stent graft systems in complicated, their use has recently

¹Department of Radiology, Chung-Ang University, College of Medicine, Seoul, Korea

²Department of Diagnostic Radiology, Pusan Paik Hospital, Inje medical University, Pusan, Korea

³Department of Diagnostic Radiology, Samsung Medical Center, Sung Kyun Kwan University, Seoul, Korea

⁴Department of Radiology and Oncoradiology, Nara Medical University, Nara, Japan

⁵Dotter Interventional Institute, Oregon Health Sciences University, Portland, Oregon, USA

Received November 4, 1998 ; Accepted April 16, 1999

Address reprint requests to : Hyung Jin Shim, MD., Department of Radiology, Chung-Ang University Hospital
#82-1, Pildong 2ka, Chung-ku, Seoul 100-272, Korea.

Tel. 82-2-2260-2275 Fax. 82-2-2272-8351 E-mail. shimhj@cau.ac.kr

been investigated for the treatment of aneurysmal vascular disease as well as TIPS(9,12-14). Using this same approach, and a simple and easily deployable stent graft design, polytetrafluoroethylene(PTFE)-covered spiral Z-stents were created in swine to improve TIPS patency and prevent the effect of bile leakage into the shunt. The length of the stent graft was such that it extended from the portal vein wall to the inferior vena cava(IVC), including the injured hepatic vein.

Materials and Methods

TIPS using PTFE covered spiral Z-stents were created in seven normotensive 6 to 8-week-old domestic swine, weighing 15 to 20 kg. The animals were tranquilized with Telazol 10 mg/kg IM(Fort Dodge Laboratories, Fort Dodge, Ia.) and atropine 1 mg IM(Elkins-Shinn, Inc., Cherry Hill, N.J.) then masked with halothane(Halocarbon Laboratories, River Edge, N.J.) until intubation was possible. They were maintained at 1.5-2.0 % halothane with 2 L/min oxygen. All procedures were carried out under the guidelines established by the National Institutes of Health publication No.80-23, Principles of Laboratory Care and Guide for the Care and Use of

Laboratory Animals and with the approval of the Institutional Animal Care and Use Committee.

Technique

The right external jugular vein was exposed under sterile conditions and a Rosch-Uchida Transjugular Liver Access Set(RUPS 100 system, Cook Inc., Bloomington, Ind.) was used to gain TIPS access from the IVC(15). For percutaneous transhepatic portal venography and pressure measurement, a 20 gauge needle and an 0.018 inch Cope type guide wire were used to place a 5 F multi-sidehole teflon catheter into the portal vein utilizing the right mid-axillary approach. Two thousand units of heparin were injected and pressures in the portal vein and IVC were measured using a Gould TA 400 monitor with a carrier amplifier(Gould Electronics, Cleveland, Oh.).

To gain TIPS access to the portal vein, the right hepatic vein approach via the IVC from the right jugular vein was followed, using the RUPS 100 system and employing the same clinical technique. The simultaneous injection of contrast material through the transhepatic portal catheter and a 10-F sheath of the RUPS 100 system in the right hepatic vein allowed visualization of TIPS tract length and of the outflow from the right hepatic vein. A 10 mm diameter, 4-cm-long angioplasty balloon catheter(Cook Inc., Bloomington, Ind.) was used to dilate the parenchymal tract. For stenting, the 10-F sheath was then advanced, following the partially inflated balloon catheter, 3-4 cm into the portal vein. An additional 1000 units of heparin were administered into the portal vein.

Stents

A spiral Z-stent, 10 mm in diameter and 5.5 cm long, made of 0.012-inch stainless wire was covered with a 10-mm-diameter thin-walled PTFE tube(Atrium, W. L. Gore, Flagstaff, Ariz.) attached at both ends by a 6-0 polypropylene suture. A single Z-stent "skirt" was connected on the outside with suture, 2 mm beyond the leading end of the graft(Fig. 1). When the covered stent was compressed and pushed through the 10-F delivery sheath, the skirt was deployed and allowed to expand well within the main portal vein while the rest of the graft was still compressed. Under fluoroscopic guidance, retraction of the entire delivery system caused the skirt to contract at the portal vein wall, the remainder of the covered spiral Z-stent was then released by further sheath withdrawal. In this manner the entire TIPS tract from the portal vein wall, through the right hepatic vein



Fig. 1. A spiral Z-stent is covered with a 10-mm-diameter PTFE tube. TIPS tract extending from the portal vein wall to the inferior vena caval orifice of the right hepatic vein was lined with this stent-graft. A single Z-stent "skirt" is connected to the leading end of stent-graft.

and extending to the IVC orifice, was lined with PTFE.

Follow-up venography and histologic evaluation

Pre- and post-TIPS portal venography and pressure measurements were obtained in all animals, which were then followed up at 2-week intervals for 12 weeks or until shunts occluded.

In order to evaluate the effect of acute occlusion of the right hepatic vein due to covered stent, a direct right hepatic venogram was obtained.

For euthanasia, heparin 2000 units and Beuthanasia-D 5 ml(Schering-Plough Animal Health Corp., Kenilworth, N.J.) were intravenously injected while the animal was still under anesthesia. Resected liver was examined grossly and prepared for histology. After soaking for more than 12 hours in 10 % buffered formalin, specimens were cut in half longitudinally and the inner lumen of the TIPS tract was grossly examined. These bivalvular specimens were cut transversely into 5-mm-long sections from the IVC orifice of the right hepatic vein to the portal vein and the stent wires were carefully removed. The right hepatic vein wall, the TIPS tract, and the portal vein wall were embedded. Thereafter,

5 μ m sections were prepared from paraffin blocks and stained with hematoxylin and eosin.

Results

The deployment of the PTFE covered spiral Z-stent was similar to delivering uncovered spiral Z-stents(8), it pushed easily through a 10-F sheath and all seven covered stents were successfully placed for TIPS.

One swine(#7) died 11 days after TIPS; its failure to thrive might have been due to encephalopathy. A venogram was not possible but minimal pseudointimal hyperplasia was noted in the explanted specimen. The remaining six swine underwent complete follow-up until shunt occlusion or termination at 12 weeks.

Portal venography and pressure measurement

Percent stenoses of each animal during follow-up are listed in Table 1. In all seven, immediate post-TIPS anterior-posterior and lateral venography showed widely patent shunts. Occlusion occurred at 4 weeks(#4), 8 weeks(#2,5), 10 weeks(#6), 12 weeks(#3), and the remaining TIPS, #1, was still patent at 12 weeks. Stenosis

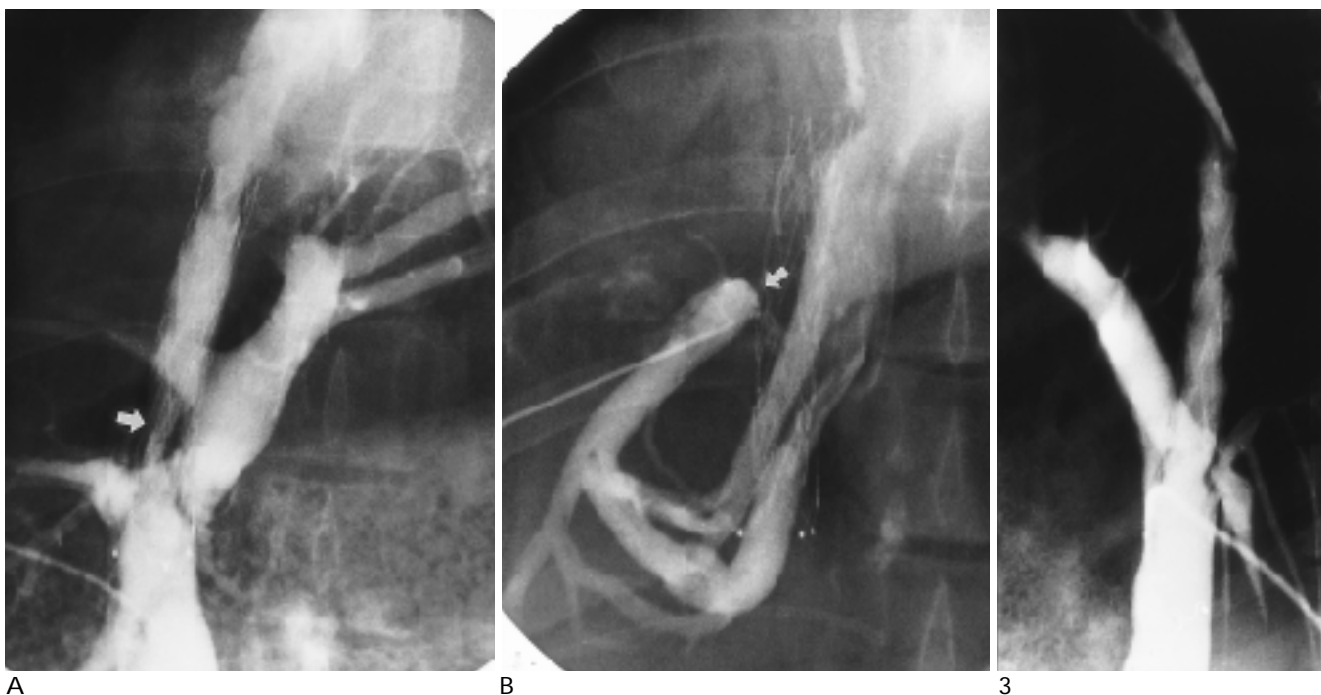


Fig. 2. Obstruction of the portal vein wall level, 12 weeks follow-up of TIPS created with a PTFE-covered spiral Z-stent.

A. The follow-up portal venogram 10 weeks after TIPS demonstrates main stenosis is located at the portal vein wall level(arrow).

B. The direct right hepatic venogram after transhepatic puncture at 12 weeks shows obstruction of the right hepatic vein at the level of PTFE-covered spiral Z-stent (arrow), but patent with collaterals. The flow direction of the right hepatic vein was reversed and drained to the collaterals into the inferior vena cava.

Fig. 3. Lateral portogram 2 weeks after TIPS shows multiple parenchymal tract stenoses in TIPS tract.

was calculated at the narrowest luminal diameters over the fully expanded diameter of the stent. For the purpose of evaluation, a 50 % luminal narrowing was considered significant. Using the Kaplan-Meier lifetime analysis system, a 50 % luminal patency rate (less than 50 % luminal narrowing) was seen in 83 % of animals at 4 weeks, 33 % at 6 weeks, 17 % at 8 weeks, and 0 % at 10 weeks (Table 2). Venography showed the predominant sites of stenosis were the portal vein wall (n= 2) (Fig. 2A), the parenchymal tract (n= 2) (Fig. 3) and the end of the stent graft in the IVC (n= 2) (Fig. 4B). In swine in which the stent did not cover the portal vein wall there was occlusion at that level at the 4-week follow-up (#4).

Venacavography at 12 weeks showed that in two animals, the middle and left hepatic veins were patent, but there was no right hepatic vein. Percutaneous injection into the right lower lobe of the liver revealed an obstructed right hepatic vein at the stent graft level but a patent right hepatic vein which drained into the IVC through multiple small collaterals (#1) (Fig. 4C). Another animal (#3) showed large collaterals from the right hepatic vein to the IVC. In the obstructed right hepatic vein there was reverse flow through collaterals (Fig. 2B).

Direct portal vein pressure was measured in all animals but data did not correlate with venographic and histologic changes.

Gross and histologic evaluation

In six swine covered stents were placed in the optimal position from the portal vein wall to the IVC. In one animal (#4) it was misplaced, being a little higher than the preferred location, and the portal vein wall and a small part of the liver parenchyma were exposed. In four animals the stent graft protruded about 1 cm into the IVC, and in other swine (#3,6), the medial corner of the stent graft protruded into the IVC but the lateral corner of the stent graft was in the hepatic vein near the junction with the IVC.

Gross findings demonstrated intimal hyperplasia (IH) at both ends of the stents (portal vein wall and IVC) and in the TIPS tract. The stent graft protruding into the IVC was completely covered with neointima and adherent to the adjacent IVC lumen. In the tract, occluded shunt specimens were filled with thrombus, but this was easily distinguished from PIH.

In two of seven animals (#1,2), bile leakage was noted

Table 1. Percent Stenoses of TIPS Using PTFE-covered Spiral Z-stent.

Swine	2 W			4 W			6 W			8 W			10 W			12 W		
	P	T	I	P	T	I	P	T	I	P	T	I	P	T	I	P	T	I (%)
#1	16	0	0	16	0	21	33	0	33	33	0	33	33	0	50	33	0	80
#2	29	43	25	29	43	43	43	80	60	100	100	100						
#3	16	16	16	16	16	33	20	19	50	33	19	50	60	19	50	100	100	100
#4	33	29	29	100	100	100												
#5	0	0	0	33	16	14	40	40	16	100	100	100						
#6	0	0	16	0	0	25	20	0	40	42	42	83	100	100	100			
#7	0	0	0															

W; weeks. P; portal vein wall level. T; TIPS tract in the liver parenchyma. I; IVC orifice level.

Table 2. Results of 50% Luminal Patency Rate of TIPS Using Covered and Uncovered Stents (Kaplan-Meier Life Table Analysis).

	1W	2W	3W	4W	6W	8W	10W	12W (percent patency)
A. Covered spiral Z								
100		100	100	83	33	17	0	0
B. Uncovered spiral Z(8)								
94		32.5	5.3	-	5.3	-	-	-
C. Uncovered Wallstent(9)								
100		38	23	8	8	8	8	8
D. Stent graft using Wallstent(9)								
100		77	69	69	69	69	69	38

W; week(s), A; PTFE-covered spiral Z-Stent (n= 7), B; uncovered spiral Z-stent (n= 18), C; uncovered Wallstent (n= 13),

D; PTFE stent graft using Wallstents (n= 13), (8), (9); reference number.

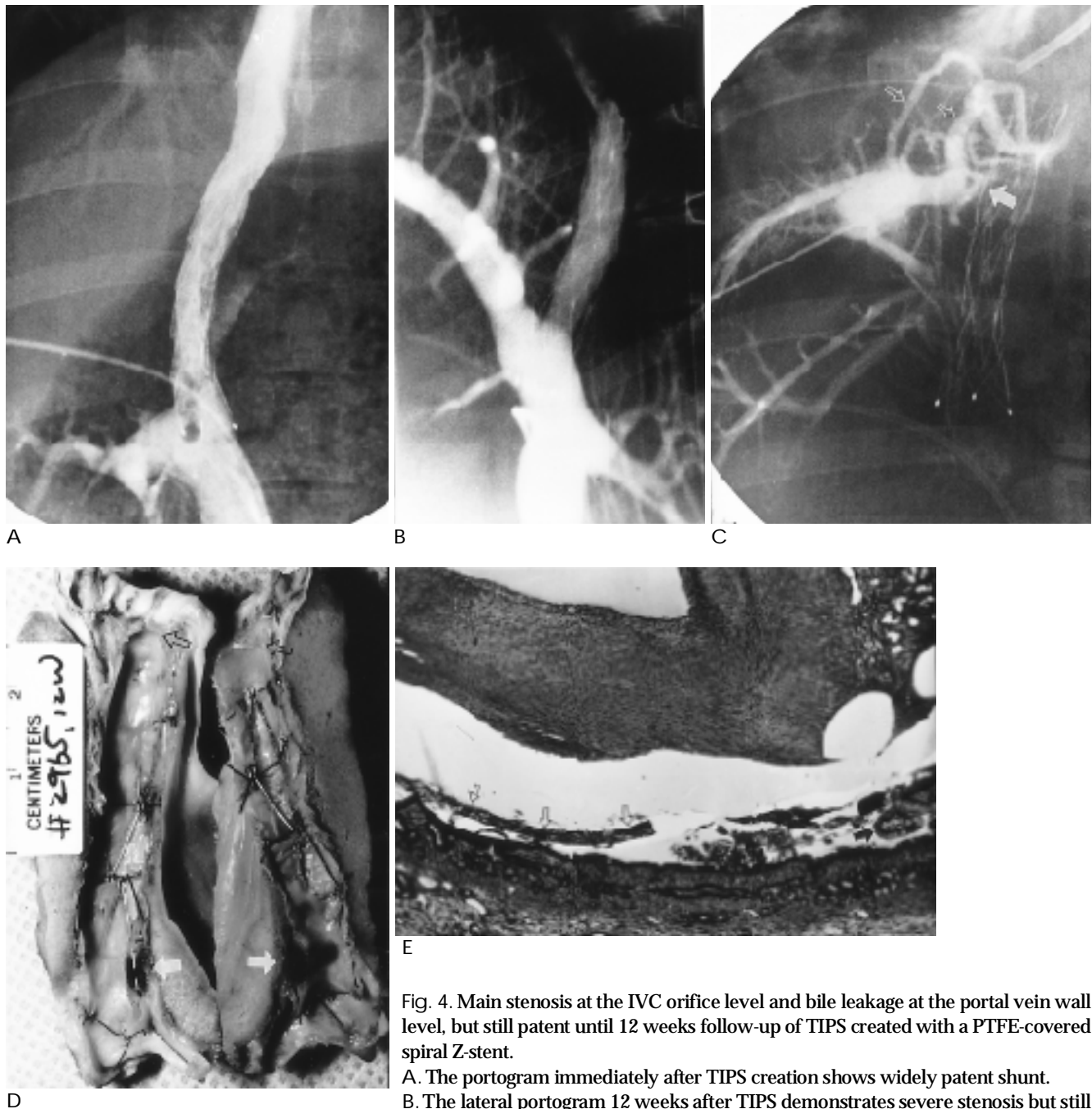


Fig. 4. Main stenosis at the IVC orifice level and bile leakage at the portal vein wall level, but still patent until 12 weeks follow-up of TIPS created with a PTFE-covered spiral Z-stent.

- A. The portogram immediately after TIPS creation shows widely patent shunt.
- B. The lateral portogram 12 weeks after TIPS demonstrates severe stenosis but still patent at the IVC orifice of the right hepatic vein with slight luminal narrowing at the portal vein wall level.
- C. Direct right hepatic venogram at the 12 weeks reveals near obstruction (arrow) of the right hepatic vein at the stent graft level, but flow is still patent and drained into the IVC through the multiple collaterals (open arrows).
- D. A gross specimen of this 12 weeks follow-up shows tight stenosis at the IVC orifice level of the right hepatic vein (open arrows). Bile precipitation with mild pseudointimal hyperplasia (arrows) is noted at the parenchymal tract near the portal vein wall. This bile leakage is located under the PIH but both sides of the porous PTFE graft. Minimal pseudointimal hyperplasia is shown in the parenchymal tract.
- E. Histologic evaluation at the bile leak area of this specimen shows granulation tissue pseudointima with an endothelial cell lining. Cavitated bile precipitation necrosis is demonstrated in the thick pseudointimal hyperplasia area. PTFE (open arrows) is noted between the liver and pseudointimal hyperplasia. PTFE and pseudointimal hyperplasia were often fragmented and separated from the adjacent liver tissue during the preparation procedure of histologic specimens. Bile duct proliferations (arrow) are found under the PTFE with bile precipitation (H&E stain $\times 40$).

in the parenchymal tract near the portal vein wall. One animal(#1, Fig. 4), still patent at 12 weeks, had a large bile leak(7 × 4 mm and 2 mm in thickness) along the underside of the graft between the PTFE graft and the PIH, and a thin-layered bile leak along the inside(luminal side) of the graft(Fig. 4 D). Another animal(#2) demonstrated tract stenosis at 6 weeks and was sacrificed at 8 weeks due to an occlusion located away from the area of the bile leak, which was a thin layer along the outside of the graft.

Histology demonstrated bile leakage both inside and outside the graft, suggesting that bile was precipitated through the porous PTFE graft. In both cases in which there was bile leakage, bile duct proliferation was noted under the PTFE(Fig. 4 E).

Discussion

Experimental TIPS studies in swine have investigated the use of Z-stents, spiral Z-stents, Wallstents, and stent grafts with Wallstents(8, 9). Kichikawa et al. demonstrated significant early PIH and later developing liver protrusion between spiral Z-stent wires, leading to shunt stenosis and occlusion around 3 or 4 weeks(8). Most animals showed central parenchymal tract stenosis and occlusion, and no predominant hepatic or portal vein wall stenosis; this was most likely due to early occlusion. In swine with uncovered Wallstents, the findings were also similar to those for TIPS.

LaBerge et al.(1) defined TIPS stenosis as a narrowing of more than 50 % of the diameter or a pressure gradient of 15 mm Hg across the narrowing. Occlusions were defined as the absence of flow through the shunt as judged by the injection of contrast material into the portal vein or because of inability to catheterize an occluded shunt. In this study, a 50 % luminal narrowing was considered significant for the purpose of comparison. Fifty percent luminal patency rates of uncovered spiral Z-stents and uncovered Wallstents(Table 2) were nearly the same (log rank test, $p > 0.5$) and TIPS stenosis/occlusion usually occurred around 3 to 4 weeks(8,9). PTFE-covered spiral Z-stents significantly improved TIPS patency when compared to uncovered spiral Z-stents and uncovered Wallstents(log rank test, $p < 0.5$ until 5 weeks)(Table 2).

Nishimine et al.(9) used stent grafts made with thin-walled PTFE graft material anchored at both ends by Z-stents and centrally supported by one or two Wallstents. The stent graft was 10 mm in diameter and 40-45 mm

long, and lined the TIPS tract from the portal vein wall to the hepatic vein. In his study, at 4 weeks, 12 of 13 uncovered shunts were stenotic or occluded compared to only 4 of 13 stent-grafted shunts. TIPS patency significantly better than in a control group of 10-mm uncovered Wallstents. The 50 % luminal patency rate was 69 % of 13 animals at 10 weeks. Predominant hepatic vein wall stenosis developed in 8 of 13 stent grafts when the covering extended only slightly past the puncture site of the hepatic vein wall. When the graft extended all the way from the portal vein to the IVC, minimal PIH occurred and durable shunt patency was achieved.

TIPS created with PTFE-covered stent grafts(Wallstent) demonstrated a marked improvement in patency over those created with traditional uncovered Wallstents in a swine model(9). This was mostly due to a dramatic decrease in tract stenoses and occlusions and was linked to the exclusion of transected bile ducts from direct communication with the shunt lumen(18). Saxon et al. applied stent grafts in three patients in whom biliary-TIPS fistulas had led to early occlusion, and in all cases created an excellent shunt lumen(18). Stent grafts also limited the development of hepatic vein stenoses when the graft material extended as far as the inferior vena cava(9).

Aware of improved TIPS tract patency by using covered stents, we tried to solve the problem of hepatic vein stenosis by using a longer PTFE-covered spiral Z-stent to line the tract from the portal vein wall through the hepatic vein into the IVC. To decide the average distance from the wall of the portal vein to the IVC through the TIPS tract, twenty examples of swine TIPS described in previous studies were examined(8,9). The average was 4 cm, with a few at 5cm. It was decided that 5.5 cm would be the adequate length for a covered stent extending from the portal vein to the level of the IVC.

The PTFE-covered spiral Z-stent has some advantages. It is easy and simple to deploy and also less expensive than stent grafts using Wallstents. However, a PTFE-covered spiral Z-stent has an uneven luminal graft surface due to the irregular and wide spaces between the wires. When a spiral Z-stent curves inside the graft, the angle of the Z's will protrude into the lumen creating spaces between the wires and the graft surface. Thrombus may arise from these spaces(Fig. 3).

Occlusions of the right hepatic vein did not appear to be a problem for the normal healthy growing swine used in our study. Two swine for which we obtained a

direct right hepatic venogram displayed collaterals draining around the occluded area. We were not able to induce liver cirrhosis in these swine, but in cirrhotic patients, when a long graft which may cause occlusion of the right hepatic vein is used, liver function should be analysed.

Bile duct injury can occur during TIPS(7,9-11,18). Laberge et al found transected bile ducts in three of five explanted TIPS specimens(7). Bile staining was detected around the transected ducts, and bile pigment was incorporated into the developing thrombus and pseudointima. Teng et al., in their recent experimental study, insisted that bile leak may promote TIPS tract thrombosis, but in vitro study appears to have shown that it inhibits myointimal proliferation itself(10). Desmet has described the inflammatory nature of bile pigment, and in two patients this effect may have contributed to PIH(17). Saxon et al. documented three biliary-TIPS fistula patients who developed recurrent TIPS stenosis or occlusion of the parenchymal tract(18). In one case this was pathologically confirmed after liver transplantation. The other two were confirmed after the biliary tree was opacified when contrast material was injected into the thrombus within the parenchymal shunt tract using a prototype double occlusion balloon catheter.

A recent animal study using Wallstents showed a high incidence of bile leakage and early thrombosis in shunts created with uncovered Wallstents(9). Six of 13 TIPS had grossly visible bile leaks and all these shunts were occluded within 2 to 4 weeks. For stent graft using Wallstents, only two of the 13 showed evidence of bile leakage. In our study, bile leakage was discovered in two of seven specimens. In both cases there was penetration of the porous PTFE membrane, but only confinement under - rather than incorporation into - the PIH. Thrombus formation incorporated with bile leakage did not precipitate along the graft lumen. PTFE graft(Atrium) did not completely seal the bile leak but might prevent acute thrombus precipitation and might work well as a functional barrier. In both cases involving leakage, bile duct proliferation was demonstrated in the area of bile leakage under the PTFE graft. Bile ducts proliferated from the injured portion, though we were able to explain exactly why. There may be a correlation with active proliferative ability in young growing pig.

In conclusion, PTFE-covered stent grafts offer significantly improved TIPS patency in swine as compared to uncovered stents. However, placing the graft so that it extends precisely from the portal vein wall to the IVC

through the hepatic vein is still a technical challenge and may cause hepatic venous obstruction around the graft with unknown consequences for liver function.

References

1. LaBerge JM, Ring EJ, Gordon RL, et al. Creation of transjugular intrahepatic portosystemic shunts with the Wallstent endoprosthesis: results in 100 patients. *Radiology* 1993;187:413-420
2. Rossle M, Haag K, Ochs A, et al. The transjugular intrahepatic portosystemic stent-shunt procedure for variceal bleeding. *N Engl J Med* 1994;330:165-171
3. Rousseau H, Vinel J-P, Bilbao JJ, et al. Transjugular intrahepatic portosystemic shunts using the Wallstent prosthesis: a follow-up study. *Cardiovasc Intervent Radiol* 1994;17:7-11
4. Conn HO. Transjugular intrahepatic portal-systemic shunts: the state of the art. *Hepatology* 1993;17:148-158
5. Haskal ZJ, Pentecost MJ, Soulen MC, Shlansky-Goldberg RD, Baum RA, Cope C. Transjugular intrahepatic portosystemic shunt stenosis and revision: early and midterm results. *AJR* 1994;163:439-444
6. Saxon RR, Barton RE, Peterson BD, Lakin PC, Keller FS, Rosch J. Transjugular intrahepatic portosystemic shunt: middle-term shunt patency.(abstract) *Radiology* 1993;189(Program book):227
7. LaBerge JM, Ferrell LD, Ring EJ, Gordon RL. Histopathologic study of stenotic and occluded transjugular intrahepatic portosystemic shunts. *J Vasc Interv Radiol* 1993;4:779-786
8. Kichikawa K, Saxon RR, Nishimine K, Nishida N, Uchida BT. Experimental TIPS with spiral Z-stents in swine with and without induced portal hypertension. *Cardiovasc Intervent Radiol* 1997;20:197-203
9. Nishimine K, Saxon RR, Kichikawa K, et al. Improved transjugular intrahepatic portosystemic shunt patency with PTFE-covered stent-grafts: experimental results in swine. *Radiology* 1995;196:341-347
10. Teng GJ, Bettmann MA, Hoopes PJ, et al. Transjugular intrahepatic portosystemic shunt: effect of bile leak on smooth muscle cell proliferation. *Radiology* 1998;208:799-805
11. Saxon RR, Mendel-Hartvig J, Corless CL, et al. Bile duct injury as a major cause of stenosis and occlusion in transjugular intrahepatic portosystemic shunts: comparative histopathologic analysis in humans and swine. *J Vasc Interv Radiol* 1996;7:487-497
12. Semba CP, Mitchell RS, Miller DC, et al. Thoracic aortic aneurysm repair with endovascular stent-grafts. *Vasc Med* 1997;2:98-103
13. Gordon MK, Lawrence-Brown MM, Hartley D, et al. A self-expanding endoluminal graft for treatment of aneurysms: results through the development phase. *Aust N Z J Surg* 1996;66:621-625
14. Haskal ZL, Davis A, McAllister A, Furth EE. PTFE-encapsulated endovascular stent-graft for transjugular intrahepatic portosystemic shunts: experimental evaluation. *Radiology* 1997;205:682-688
15. Rosch J, Uchida BT, Barton RE, Keller FS. Coaxial catheter-needle system for transjugular portal vein entrance. *J Vasc Interv Radiol* 1993;4:145-147
16. Freedman AM, Sanyal AJ. Complications of transjugular intrahepatic portosystemic shunts. *Semin Intervent Radiol* 1994;11:161-177
17. Desmet VJ. *Cholestasis: extrahepatic obstruction and secondary bil-*

iliary cirrhosis. In: Macsween RNM, Anthony PP, Scheuer PJ, eds.
Pathology of the liver. New York, NY: Churchill Livingstone, 1987
 18. Saxon RR, Timmermans HA, Uchida BT, et al. Stent-grafts for re-

vision of TIPS stenoses and occlusions: a clinical pilot study. *J Vasc
 Interv Radiol* 1997;8:539-548

1999;41:37-44

PTFE-covered Spiral Z-stent

1

1

2

3

⁴Department of Radiology and Oncoradiology, Nara Medical University, Nara, Japan

⁵Dotter Interventional Institute, Oregon Health Sciences University, Portland, Oregon, USA

² . ³ . . Kyioshi Nishimine, M.D.⁴,
 Barry Uchida, B.S.⁵, Josef Rősch, M.D.⁵

:

PTFE-covered spiral Z-stent

: 7

PTFE-covered spiral Z-stent

2

12

,
 가

: Lifetime

50%

4

83%, 6

33%, 8

17%

10

0%

(2/6)

(2/6),

(2/6)

11

7

2

: PTFE-covered spiral Z-stent