

## Kimura's Disease : CT Features of Abdominal Involvement in a Case<sup>1</sup>

In Jae Lee, M.D.<sup>2</sup>, Soo Youn Park, M.D., Hyun Kwon Ha, M.D., Pyo Nyun Kim, M.D.,  
Moon-Gyu Lee, M.D., Yong Ho Auh, M.D.

Kimura's disease is a benign chronic inflammatory condition with good prognosis, commonly involving the head and neck area. With regard to abdominal manifestations, however, the information contained in the literature is limited. Diagnosis on the basis of imaging is difficult, especially in abdominal cases manifesting as lymphadenopathy. The purpose of this report is to illustrate and discuss an abdominal case of the disease manifesting as lymphadenopathy.

**Index words :** Abdomen, CT  
Abdomen, diseases

Kimura's disease is a benign chronic inflammatory disease of unknown etiology that occurs primarily in Orientals of young to middle age (1,2). Patients usually present with subcutaneous or soft tissue masses of the head and neck, often with involvement of the salivary glands and regional lymph nodes (3). It is characterized pathologically by lymph-folliculoid granuloma with infiltration of the mass and surrounding tissues by eosinophils (2). Since the prognosis of this disease is good, accurate diagnosis after lymph node biopsy may spare patients from unnecessary radical surgery (3). However, abdominal manifestation of this disease is rare (4). The purpose of this report is to describe a case of Kimura's disease involving the abdominal and pelvic area that was demonstrated by computed tomography (CT).

### Case Report

A 44-year-old man presented with a mass in the right

lower abdominal and inguinal area. Blood studies revealed peripheral eosinophilia of 55.3% and a slightly elevated white blood cell count (11700-15900/mm<sup>3</sup>). Laboratory study of serum IgE was not performed. At age 42 years, the patient had undergone surgical excision of a left thigh and neck mass at another hospital. At that time, Kimura's disease was diagnosed on the basis of pathologic findings.

Medical treatment with steroids was first attempted, and physical examination showed that the results were satisfactory. After treatment was discontinued, however, the condition recurred, and newly developed swelling of the right thigh was noted.

Postcontrast CT performed during the present admission showed that aggregated lymphadenopathy extended from the renal hilar level of the right para-aortic area to the right inguinal area. Although there were several weakly enhanced foci, the lesion was relatively homogeneous in nature. Moreover, there were no internal low attenuation foci suggesting nodal necrosis. There was no evidence of other mass formation or infiltrative change in surrounding tissue.

The patient underwent excision of the right inguinal mass, and pathologic diagnosis was consistent with Kimura's disease.

<sup>1</sup>Department of Diagnostic Radiology, University of Ulsan Asan Medical Center

<sup>2</sup>Department of Diagnostic Radiology, Hallym University College of Medicine

Received February 1, 1999 ; Accepted April 15, 1999

Address reprint requests to : Moon-Gyu Lee, M.D., Department of Diagnostic Radiology, University of Ulsan Asan Medical Center

#388-1 Poongnap-dong, Songpa-ku, Seoul 138-736, Korea.

Tel. 82-2-224-4400 Fax. 82-2-476-4719

## Discussion

Kimura's disease was described in 1948 by Kimura et al as "unusual granulation combined with hyperplastic changes in lymphoid tissue" (2). The histologic features of the condition are proliferation of folliculoid structures with infiltration mainly by eosinophils, some plasma cells, lymphocytes, and mast cells (1). Involved lymph nodes usually show florid reactive follicular hyperplasia, increased vascularity, and marked eosinophilia of the paracortical region (2). The disease occurs primarily in Orientals, especially those of Chinese or Japanese extraction (3). Men are more commonly affected than women, and the male-to-female ratio is greater than 3:1 (2). Although patients range in age from 1 to 76 years, most cases have occurred during the second and third decades of life (1,3,5-7). The common clinical features of the disease are an asymptomatic mass and local lymphadenopathy. Most lesions occur in the head and neck, especially in the parotid and submandibular re-

gions (1,3). Other less frequent sites of involvement are the axilla, groin, popliteal region, and forearm (1). Nodal involvement is characterized by eosinophilic infiltration with microabscesses, increased numbers of small blood vessels, peripheral eosinophilic infiltration, and eosinophilic folliculosis (3). There is often accompanying peripheral blood eosinophilia and elevated serum IgE (1-3). The IgE receptor is present in the germinal center and on follicular dendritic cells (3,8), and this suggests a close relationship to IgE immune response, which may play an important role in the pathogenesis of Kimura's disease (3,8). Lesions tend to recur and therapy usually consists of either local surgical extirpation or local irradiation with 25 to 30 Gy (3). Many clinicians are reluctant to treat with radiation, because the disease is benign and mainly occurs in the young (1,3). On the other hand, complete resection is difficult because of the diffuse nature of the disease (1). Transient local relief has also been achieved using steroids (1,3).

The radiologic findings of Kimura's disease involving the head and neck area have been documented; the re-

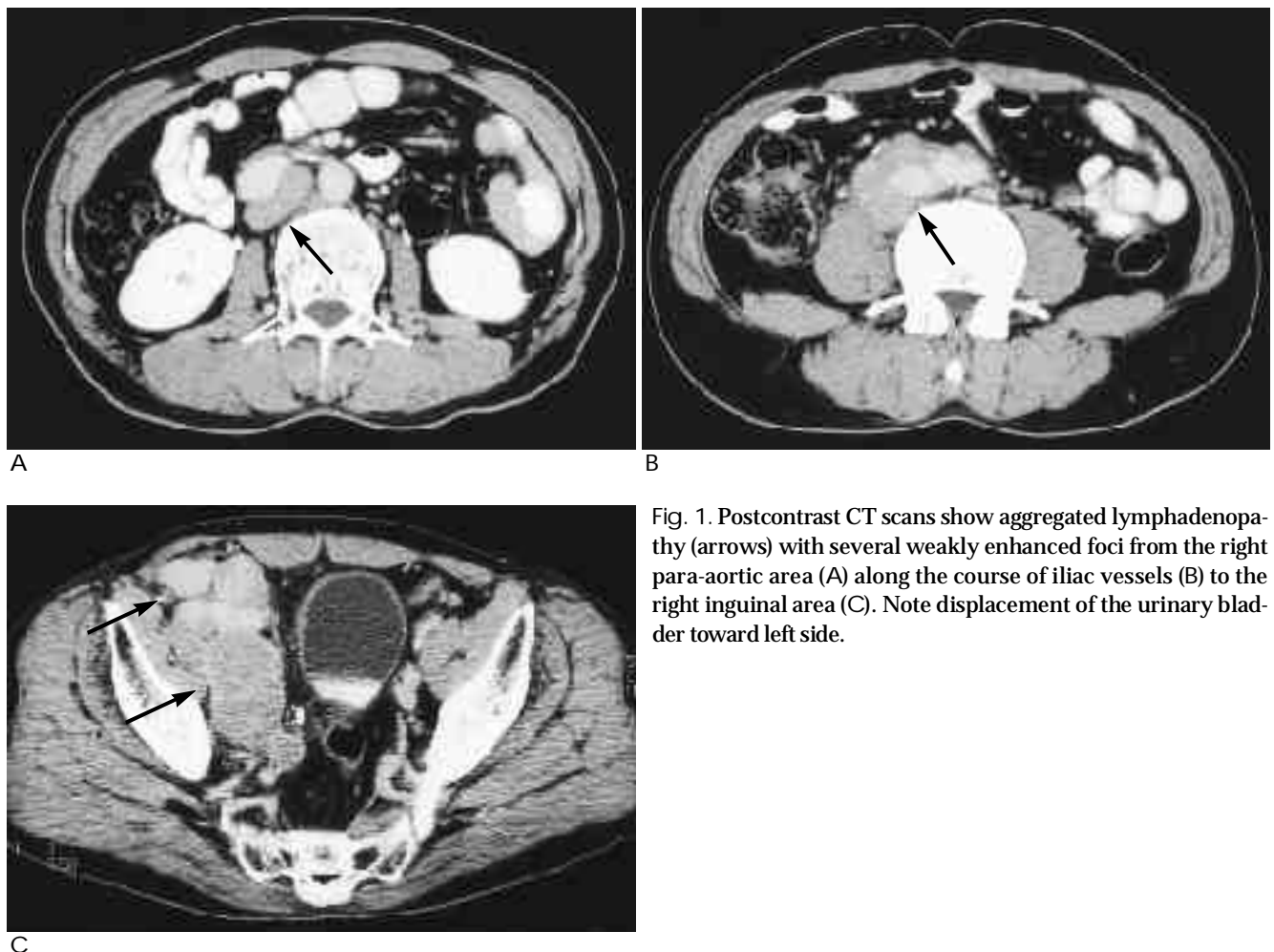


Fig. 1. Postcontrast CT scans show aggregated lymphadenopathy (arrows) with several weakly enhanced foci from the right para-aortic area (A) along the course of iliac vessels (B) to the right inguinal area (C). Note displacement of the urinary bladder toward left side.

ported CT findings of this disease include enhanced mass involving an enlarged major salivary glands, with subcutaneous extension, and enlarged regional lymph nodes (1,3,7). Since the degree of enhancement was comparable to that of the internal carotid artery and internal jugular vein, those findings suggested the vascular nature of the mass. The presence of significant enhancement is suggestive of an inflammatory process (3,7). Our case showed extensive, aggregated lymphadenopathy in the lower abdominal and pelvic area; there was, however, no evidence of other mass formation in this area. Although there were several foci of subtle enhancement, the lesion was relatively homogeneous; no internal low attenuation foci suggesting nodal necrosis were noted. According to reported descriptions of the MR (magnetic resonance) features of the head and neck lesions, the signal intensity varied (1,3). On T2-weighted images, lesions including mass and lymph node displayed slightly high to very high signal intensity, and this was attributed to different degrees of fibrosis (1,3). High signal intensity on T1-weighted images, suggestive of methemoglobin was noted within lesions (3). Differences in vascular proliferation may have caused different degrees of enhancement of the lesion, and flow voids (1,3).

It is difficult to diagnose Kimura's disease on the basis of radiologic appearance alone. The entity could be suggested in patients of Oriental extraction in the presence of a salivary gland mass with cervical lymphadenopathy (1,3), however, patients may occasionally present with

isolated lymphadenopathy (2). In abdominal cases, diagnosis of this disease on the basis of imaging can be very difficult, since the radiologic appearance of nodal manifestation is similar to lymphoma, tuberculosis, Langerhans cell histiocytosis, drug-induced lymphadenopathy, and Castleman's disease (1,3). Peripheral blood eosinophilia with elevated serum IgE levels may be helpful in differential diagnosis, though, definite diagnosis can only be made by biopsy. In order to avoid unnecessary radical surgery or inadequate medical treatment, accurate diagnosis is essential.

## References

1. Takahashi S, Ueda J, Furukawa T, et al. Kimura disease: CT and MR findings. *AJNR* 1996;17:382-385
2. Hui PK, Chan JKC, Ng CS, Kung ITM, Gwi E. Lymphadenopathy of Kimura's disease. *Am J Surg Pathol* 1989;13(3):177-186
3. Som PM, Biller HF. Kimura's disease involving parotid gland and cervical nodes: CT and MR findings. *J Comput Assist Tomogr* 1992;16:320-322
4. Kung ITM, Gibson JB, Banatyne PM. Kimura's disease: a clinicopathological study of 21 cases and its distinction from angiolymphoid hyperplasia with eosinophilia. *Pathology* 1984;16:39-44
5. Day TA, Abreo F, Hoajsoe DK, Arastad RF, Stucker FJ. Treatment of Kimura's disease: a therapeutic enigma. *Otolaryngol Head Neck Surg* 1995;112:333-337
6. Tham KT, Leung PC, Saw D, Gwi E. Kimura's disease with salivary gland involvement. *Br J Surg* 1981;68:495-497
7. Smith JRG, Hadgis C, Van Hasselt A, Metreweli C. CT of Kimura's disease. *AJNR* 1989;10:S34-36
8. Chan JK, Hui PK, Ng CS, Yuen NW, Kung IT, Gwi E. Epithelioid hemangioma (angiolymphoid hyperplasia with eosinophilia) and Kimura's disease in Chinese. *Histopathology* 1989;15:557-574

1999;41: 125-127

