

CT Findings of Portal Vein Aneurysm¹

**Dal Mo Yang, M.D., Mi Son Chang, M.D., Myung Hwan Yoon, M.D.,
Hak Soo Kim, M.D., Hyung Sik Kim, M.D., Hyo Sun Chung, M.D., Jin Woo Chung, M.D.**

Purpose: To describe the CT findings of portal vein aneurysm in eight patients.

Materials and Methods: All patients included in this study (two men and six women) underwent CT examinations between October 1996 and June 1998. Of these eight, three were suffering from hepatic disease and portal hypertension. We determined the location, shape, size, and characteristics of the lesions, and the presence or absence of portal vein anomaly.

Results: Seven patients had intrahepatic portal vein aneurysm (at the umbilical portion of the left portal vein in five patients, between the transverse and umbilical portion of the left portal vein in one, and at the bifurcation of the anterior and posterior branch of the right portal vein in one), while extrahepatic portal vein aneurysm, at the confluence of the superior mesenteric and splenic vein was found in only one. Lesions were cyst-shaped in seven cases and saccular in one, and showed well-circumscribed, markedly enhanced mass, which communicated with the portal vein and/or gives off major branches. Portal vein anomaly, in which the right anterior segmental portal vein originated from the umbilical portion of the left portal vein, was seen in three patients. In all three, intrahepatic portal vein aneurysm was present at the umbilical portion of the left portal vein, and in one, the umbilical portion of the left portal vein was located to the right of the Cantlie line.

Conclusion: CT examination can help reveal portal vein aneurysm by detecting a well-circumscribed, markedly enhanced mass which communicates with the portal vein and/or gives off major branches.

Index words: Aneurysm, portal vein
Portal vein, abnormalities
Portal vein, CT

Portal vein aneurysm is a rare disorder, first documented in 1956 (1). Since then a total of 46 cases have been reported in the clinical and radiologic literature (2, 3), but the pathogenesis of these aneurysmal dilatations is still unknown. The sonographic findings of portal

vein aneurysm have been extensively described (2-13). Although there have been some case reports of the computed tomography (CT) findings of portal vein aneurysm (3, 8, 12, 14, 15), the CT features have not been described in detail, to our knowledge. In this paper, we describe the CT findings of portal vein aneurysm in eight patients.

¹Department of Radiology, Gachon Medical College Gil Medical Center
Received November 25, 1998 ; Accepted February 18, 1999
Address reprint requests to : Dr. D. M. Yang, Department of Radiology,
Gachon Medical College Gil Medical Center, 1198, Kuwol-Dong,
Namdong-Ku, Incheon # 405-220, Korea.
Tel. 82-32-460-3060 Fax. 82-32-460-3055

Materials and Methods

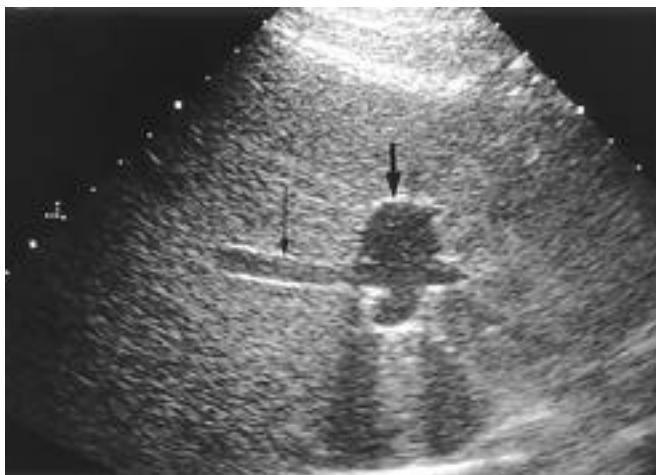Between October 1996 and June 1998, eight cases of portal vein aneurysm were diagnosed by CT. Of these eight patients, two had liver cirrhosis, one had hepatocellular carcinoma, and two had stomach carcinoma. The remaining three were asymptomatic. The patients ranged in age from 40 to 82 (mean 56) years; six were female and two were male.

These patients had been referred for CT scanning for several reasons: for screening of liver lesions in three cases, for staging of stomach carcinoma in two, and for further evaluation of portal vein aneurysm or common bile duct dilatation on the basis of sonographic findings in three. Three of the eight patients were suffering from hepatic disease and portal hypertension, diagnoses based on clinical (liver function tests, test for hepatitis B virus antigen) and radiological findings (liver and splenic size, surface of contour of liver, and the presence

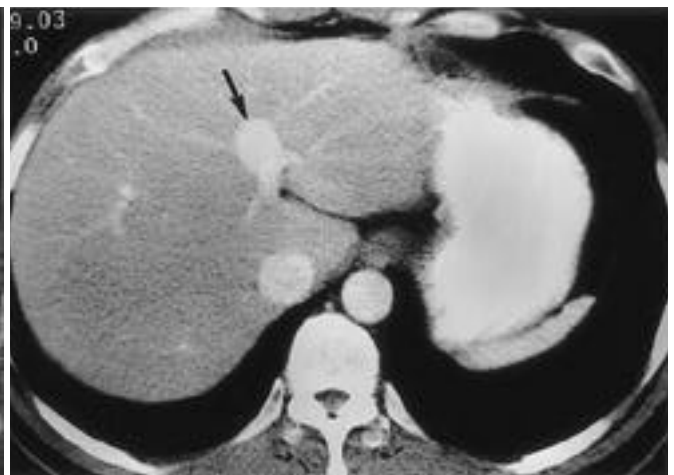of portosystemic collateral vessels).

Helical CT examinations were performed using a Somatom Plus S or a Somatom Plus 4 scanner (Siemens Medical Systems, Erlangen, Germany). For each patient, the results of a dual-phase (n= 3) or triple-phase study (n= 5) were obtained as follows: after the IV infusion of 120ml of Iopromide (Ultravist 300, Schering AG, Berlin, Germany) at a rate of 3ml/sec, an early phase sequence was obtained after a delay of 35 sec, followed by a delayed phase sequence beginning at 4 min, or, after the start of contrast infusion, an arterial phase (30 sec), portal phase (60 sec), and delayed phase (5 min) sequence was obtained. A craniocaudal scanning direction with beam collimation of 10-mm and table speed of 10-mm/sec was used in all examinations. Images were reconstructed at 8-mm intervals.

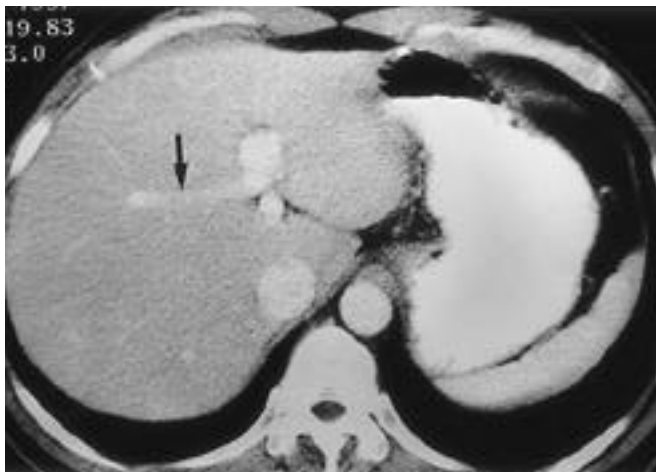
Diagnosis was based on localized dilatation of the intrahepatic portal vein (greater than 1.5cm in short axis diameter) or extrahepatic portal vein (greater than 2cm in short axis diameter) as seen on CT. For each study,



A



B



C

Fig.1. 42-year-old man with intrahepatic portal vein aneurysm. A. Transverse sonography of the liver shows a cystic dilatation of the umbilical portion of the left portal vein (short arrow). The right anterior segmental portal vein (long arrow) is originated from umbilical portion of the left portal vein. B. Portal-venous phase helical CT scan shows a cystic dilatation of the umbilical portion of the left portal vein (arrow) with giving off portal vein branches. C. Portal-venous phase helical CT scan at more caudal level than A reveals the right anterior segmental portal vein (arrow) is originated from umbilical portion of the left portal vein.

Table 1. Case Summaries of Eight Patients with Portal Vein Aneurysm

Pt. No.	Age	Sex	Location	Shape	Size(cm)	Portal vein anomaly	Hepatic disease	Portal hypertension
1	42	M	Intrahepatic*	Cystic	2.8 × 2.0	+	-	-
2	71	F	Intrahepatic*	Cystic	2.2 × 1.9	+	Liver cirrhosis	+
3	53	F	Intrahepatic*	Cystic	2.1 × 2.1	-	Liver cirrhosis	+
4	57	F	Intrahepatic*	Cystic	1.8 × 1.8	+	-	-
5	56	M	Intrahepatic*	Cystic	2.0 × 2.0	-	HCC †	+
6	82	F	Intrahepatic ‡	Saccular	2.2 × 2.0	-	-	-
7	40	F	Intrahepatic ‡	Cystic	2.0 × 1.9	-	-	-
8	46	F	Extrahepatic §	Cystic	4.0 × 3.0	-	-	-

* Umbilical portion of the left portal vein

† Between transverse and umbilical portion of the left portal vein

‡ Bifurcation of the anterior and posterior branch of the right portal vein

§ Confluence of the superior mesenteric vein and the splenic vein

¶ Hepatocellular carcinoma

the location, shape, size, and characteristics of the lesions were recorded. In addition, any other portal vein anomaly was recorded. CT images were retrospectively interpreted in an unblinded fashion by three radiologists (D.M.Y., M.H.Y., H.S.K.).

Results

A summary of our findings is presented in Table 1. Intrahepatic portal vein aneurysm was noted in seven patients, and extrahepatic portal vein aneurysm in one. Five cases of the former were located at the umbilical portion of the left portal vein (Figs. 1A, 1B), one case between the transverse and umbilical portion of the left portal vein (Fig. 2), and one at the bifurcation of the an-

terior and posterior branch of the right portal vein (Fig. 3). The extrahepatic portal vein aneurysm was located at the confluence of the superior mesenteric and splenic vein.

The portal vein aneurysm was cyst-shaped in seven cases and saccular in one (Fig. 2), and its diameter varied from 1.8x1.8cm to 4x3cm in the axial plane. The diameter of the intrahepatic and extrahepatic portal vein was normal, except at an aneurysmal site. Most portal veins and portal vein aneurysms were clearly visualized on portal vein-phase CT. Portal vein aneurysms were seen as well-circumscribed, markedly enhanced masses which communicates with the portal vein and/or gives off major branches.

Among the eight patients, portal vein anomaly, in

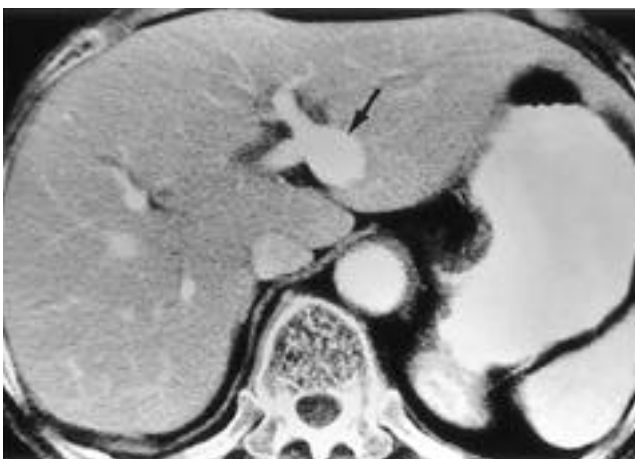


Fig. 2. 82-year-old woman with intrahepatic portal vein aneurysm. Portal-venous phase helical CT scan shows a saccular dilatation of portal vein at between the transverse and umbilical portion of the left portal vein (arrow).

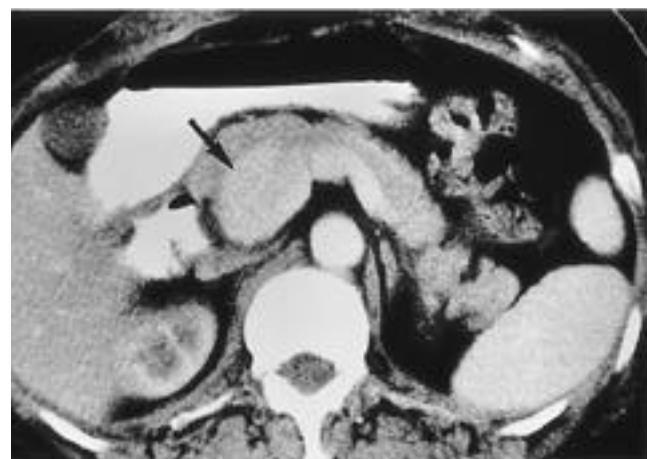

Fig. 3. 46-year-old woman with extrahepatic portal vein aneurysm. Portal-venous phase CT scan shows a cystic dilatation of the extrahepatic portal vein at the confluence of the superior mesenteric vein and splenic vein (arrow).

which the right anterior segmental portal vein originated not from the main portal vein but from the umbilical portion of the left portal vein, was seen in three patients (Figs. 1A, 1C). In all three, portal vein aneurysm was located at the umbilical portion of the left portal vein. In one of the three, the umbilical portion of the left portal vein was not in its usual position but was to the right of the Cantlie line. In the remaining two, the umbilical portion of the left portal vein was seen in its usual position between the medial and lateral segments of the liver.

Discussion

Portal vein aneurysm is a rare vascular anomaly, and may be extra- or intrahepatic. Up to 1995, to our knowledge, 46 cases of portal vein aneurysm had been described in the literature (2, 3). Extrahepatic portal vein aneurysm accounted for 30 cases, intrahepatic portal vein aneurysm for 16 cases.

The possible causes of this condition are congenital wall weakness, portal hypertension, or weakening of the vessel wall with concomitant dilatation by enzymatic digestion during pancreatitis (16). Before 1985, significant numbers of portal vein aneurysms were discovered in patients with portal hypertension or chronic liver disease. Since 1985, however, the expanded use of noninvasive imaging techniques has increased the number of patients with portal vein aneurysm without portal hypertension (2). Since no predisposing factors identified, it may be induced that in five of our eight cases, portal vein aneurysm was probably congenital, though to determine the precise causes of the condition, which have not yet been identified, further study and analysis of many more patients is required.

The potential complications of portal vein aneurysm include thrombosis, rupture, and the effects of local pressure (2), though only three cases of rupture and three of portal thrombus resulting from portal vein aneurysm have been reported (2). In our patients no complications were present.

Although surgical treatment should be considered when the size of the aneurysm increases or portal thrombus exists (2), or when prophylactic surgery is recommended for low-risk patients (17), excision of portal vein aneurysm is controversial. It has been claimed that follow-up observation by serial sonography, color Doppler sonography, or CT is sufficient when portal vein aneurysm is an incidental finding, asymptomatic and not associated with predisposing factors (2), and

close surveillance of portal vein aneurysm with CT and sonography has been recommended even when the aneurysm is associated with portal hypertension (4).

The majority of portal vein aneurysms are situated at the bifurcation or confluence (2), but in our patients, only two lesions (25%) were located at these sites. The others (75%) were located at the umbilical portion or between the transverse and umbilical portion of the left portal vein. Compared with the findings of earlier reports, these are unusual sites for portal vein aneurysms. Interestingly, portal vein anomaly, in which the right posterior segmental portal vein originated not from the portal trunk, but from the umbilical portion of the left portal vein, was seen in three patients. In one of these three, the umbilical portion of the left portal vein was located to the right of the Cantlie line. Maetani et al (18) reported four cases of portal vein anomaly in which the umbilical portion of the portal vein was abnormal, lying above the gallbladder bed and giving off major branches to the right anterior segment. However, portal vein aneurysm was not mentioned in their literature. The interrelationship between this portal vein anomaly and portal vein aneurysm is not known.

A characteristic CT finding of portal vein aneurysm is a well-circumscribed, oval, and enhanced mass resulting from focal dilatation of the portal vein (14). CT has been shown to effectively delineate the location, extent, and vascular nature of portal vein aneurysm, though conventional contrast enhanced dynamic incremental CT demonstrates vascular structure only to a limited extent. With the advent of helical technology, CT is potentially more likely to reveal vascular characteristics. By scanning during maximal portal vein opacification, visualization of portal vein aneurysm is improved. All our cases in which helical CT was used showed clear enhancement of the portal vein, and portal vein aneurysm was thus easily seen. Portal vein aneurysm can, furthermore, be easily differentiated from hypervascular tumors by the presence of portal vein communication and/or gives off portal vein branches.

In summary, portal vein aneurysm can be demonstrated by CT. Distinctive findings include the location, shape, size and characteristics of the lesion, as well as portal vein anomaly that has not been described in previous literature. CT can help reveal portal vein aneurysm by detecting hypervascular mass which communicates with the portal vein and/or gives off major branches.

References

1. Barzilai R, Kleckner MS. Hemocholecyst following ruptured aneurysm of portal vein. *Arch Surg* 1956;72:725-727
2. Ohnami Y, Ishida H, Konno K, et al. Portal vein aneurysm: report of six cases and review of the literature. *Abdom Imaging* 1997;22:281-286
3. Fulcher A, Turner M. Aneurysms of the portal vein and superior mesenteric vein. *Abdom Imaging* 1997;22:287-292
4. Itoh Y, Kawasaki T, Nishikawa H, Ochi J, Miura K, Moriyasu F. A case of extrahepatic portal vein aneurysm accompanying lupoid hepatitis. *J Clin Ultrasound* 1995;23:374-378
5. Boyez M, Fourcade Y, Sebag A, Valette M. Aneurysmal dilatation of the portal vein: a case diagnosed by real-time ultrasonography. *Gastrointest Radiol* 1986;11:319-321
6. Tanaka S, Kitamura T, Fujita M, et al. Intrahepatic venous and portal venous aneurysms examined by color doppler flow imaging. *J Clin Ultrasound* 1992;20:89-98
7. Hagiwara H, Kasahara A, Kono M, et al. Extrahepatic portal vein aneurysm associated with a tortuous portal vein. *Gastroenterology* 1991;100:818-821
8. Ohnishi K, Nakayama T, Saito M, et al. Aneurysm of the intrahepatic branch of the portal vein. Report of two cases. *Gastroenterology* 1984;86:169-173
9. Vine HS, Sequeira JC, Widrich WC, Sacks BA. Portal vein aneurysm. *AJR* 1979;132:557-560
10. Gallagher DM, Leiman S, Hux CH. In utero diagnosis of a portal vein aneurysm. *J Clin Ultrasound* 1993;21:147-151
11. Thomson PB, Oldham KT, Bedi DG, Guice KS, Davis M. Aneurysmal malformation of the extrahepatic portal vein. *Am J Gastroenterol* 1986;81:695-697
12. Dognini L, Carreri AL, Moscatelli G. Aneurysm of the portal vein: ultrasound and computed tomography identification. *J Clin Ultrasound* 1986;19:178-182
13. Fannery D, Castillo M, Monatalvo B, Casillas J. Sonographic diagnosis of aneurysm of the right portal vein. *J Ultrasound Med* 1987;6:605-607
14. Andoh, K, Tanohata K, Asakura K, Katsumata Y, Nagashima T, Kitoh F. CT demonstration of portal vein aneurysm. *J Comput Assist Tomogr* 1988;12:325-327
15. Ishikawa T, Tsukune Y, Ohyama Y, Fujikawa M, Sakuyama K, Fujii M. Venous abnormalities in portal hypertension demonstrated by CT. *AJR* 1980;134:271-276
16. Schild H, Schweden F, Braun B, Lang H. Aneurysm of the superior mesenteric vein. *Radiology* 1982;145:641-642
17. Calligaro KD, Ahmad S, Dandora R, et al. Venous aneurysms: surgical indications and review of the literature. *Surgery* 1995; 117:1-6
18. Maetani Y, Itoh K, Kojima N, et al. Portal vein anomaly associated with deviation of the ligamentum teres to the right and malposition of the gallbladder. *Radiology* 1998;207:723-728

1999;40: 901- 905

