

## Metastatic Brain Tumor from Cardiac Chondrosarcoma : A Case Report<sup>1</sup>

Han Bok Kim, MD, Seung Eun Jung, MD, Hak Hee Kim, MD,  
Kyu Ho Choi, MD, Youn Soo Lee, MD<sup>2</sup>, and Seog Jin Kang, MD<sup>2</sup>

Primary chondrosarcoma of the heart and its metastasis to the brain is extremely rare. We describe the case of a patient who underwent resection of cardiac chondrosarcoma only to relapse with brain metastasis two years later. MR images showed that these metastatic tumors were slightly hypointense relative to the brain on T1-weighted images and hyperintense on T2-weighted images. The masses were highly enhanced. Peritumoral edema appeared less extensive and the focal cystic portion was seen within the mass, corresponding to myxoid degeneration.

**Index words:** Brain neoplasms, secondary  
Brain neoplasms, MR  
Heart, neoplasms

Chondrosarcoma is a malignant tumor of chondroblasts and can arise from bone and soft tissue. Primary chondrosarcoma of the heart and its metastasis to the brain is extremely rare (1, 2), to our knowledge, there is no report concerning MR findings of metastatic brain tumor originating from cardiac chondrosarcoma. Because of the few reported cases of cardiac sarcoma and the relatively poor prognosis of primary cardiac sarcomas, the metastatic potential and behavior of these tumors are not fully understood. Our case is that of a patient with chondrosarcoma of the heart without evidence of metastatic disease. Two years after resection of the primary tumor, she presented with brain metastasis.

### Case Report

A 39-year-old woman was admitted to the hospital for seizure with loss of consciousness. Two years earlier

she had undergone resection of a cardiac mass in the left atrium and conventional chondrosarcoma was pathologically confirmed (Fig. 1). The patient underwent radiation and chemotherapy for 16 months.

Noncontrast-enhanced CT of the brain after this admission showed two hypodense masses in the right frontal lobe, and the larger tumor located in the mid portion of this lobe contained the cystic portion. The smaller one was located in the base of the right frontal lobe. No definite intratumoral calcification was seen and the masses were slightly enhanced after intravenous contrast infusion. MR images disclosed a 5 × 4.5 cm sized, slightly inhomogeneous lobulated mass with high signal intensity on T2-weighted images and heterogeneous low signal intensity on T1-weighted images in the mid portion of the right frontal lobe (Fig. 2A and B). A second 4.5 × 2.5 cm sized lobulated mass with the same signal intensity was seen in the right frontal basal region (Fig. 2C). There was associated mild peritumoral edema. Contrast enhanced axial T1-weighted MR images demonstrated inhomogeneous enhancement of the mass containing the cystic portion (Fig. 2D). Contrast enhanced coronal T1-weighted images depicted tumor extension to the right ethmoid sinus in the right frontal basal region (Fig. 2E).

<sup>1</sup>Departments of Radiology, College of Medicine, The Catholic University of Korea

<sup>2</sup>Clinical Pathology, College of Medicine, The Catholic University of Korea  
Received September 18, 1998 ; Accepted January 4, 1999

Address reprint requests to : Seung Eun Jung, M.D. Department of Radiology, St. Mary's Hospital, College of Medicine, The Catholic University of Korea.

#62, Youido-Dong, Youngdungpo-Gu, Seoul 150-010, Korea.

Tel. 822-3779-1277, Fax. 822-783-5288, e-mail: sejung@cmc.cuk.ac.kr

Surgery revealed relatively well demarcated, yellowish intra-axial masses of hard consistency and scanty vascularity in the right frontal lobe. Two dumbbell-shaped surgical specimens were obtained. Both consisted of lobulated masses with firm and myxoid tissue, and an area of hemorrhage was seen within the larger mass (Fig. 3). Microscopically both revealed a tumor composed of undifferentiated spindle cells with myxoid foci and no distinct cartilagenous differentiation. The cystic portion seen within the mass on MR images corresponded to myxoid degeneration with hemorrhage.

### Discussion

Primary tumors that commonly metastasize to the brain are carcinomas of the lung and breast, malignant melanoma, and gastrointestinal or genitourinary tumors (3). Cardiac tumors rarely metastasize to the brain.

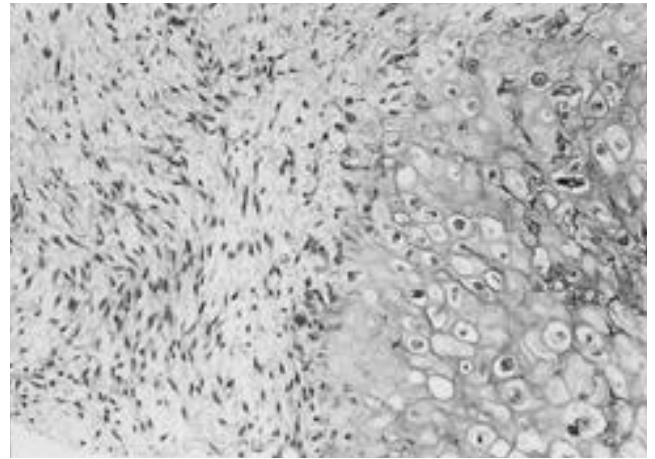


Fig. 1. Microscopic examination of the specimen taken from Lt. atrium reveals a spindle cell sarcoma composed of areas of cartilage, chondrocytic cells in mesenchyme, and myxoid foci, consistent with extraskeletal chondrosarcoma (H&E, x100).

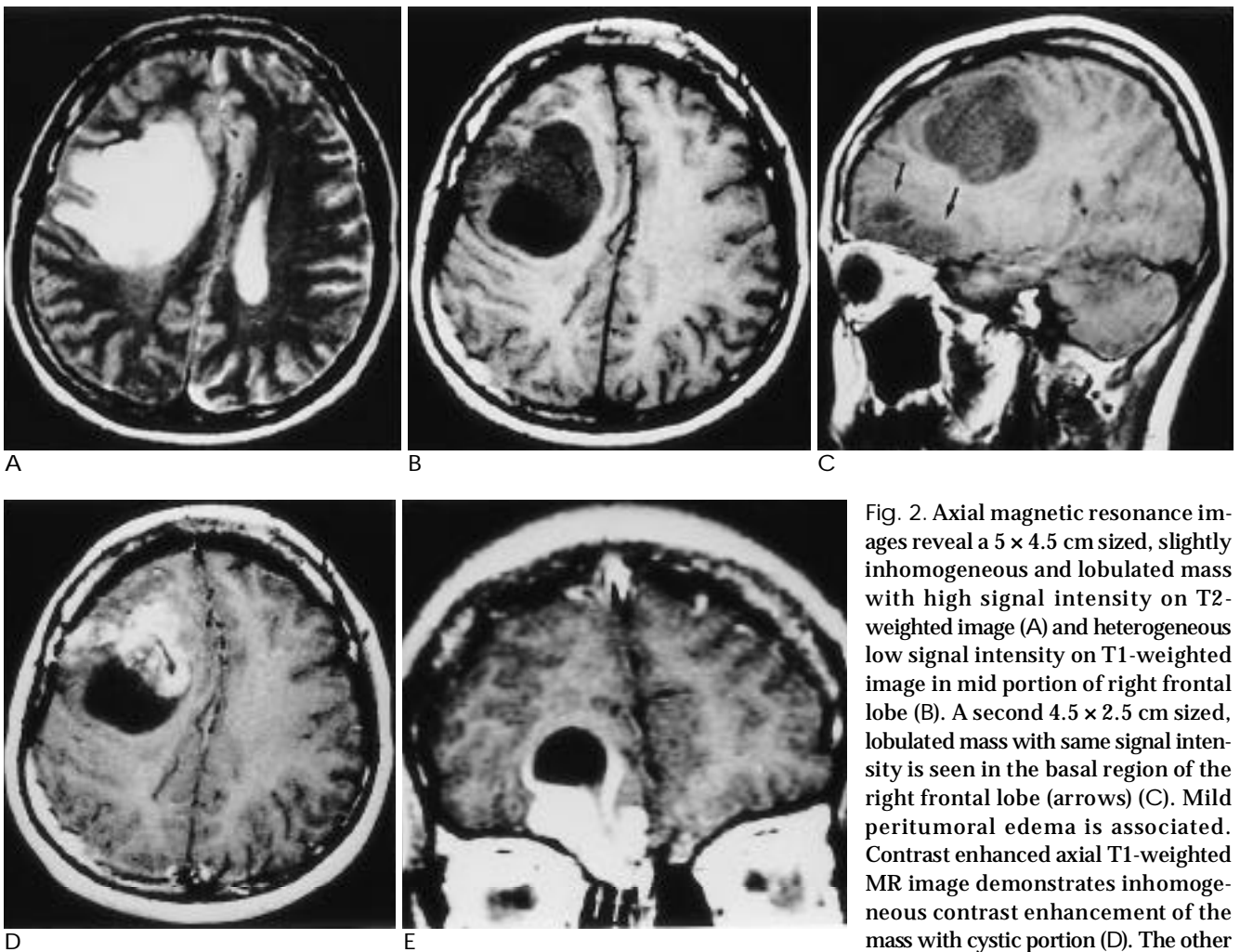


Fig. 2. Axial magnetic resonance images reveal a 5 x 4.5 cm sized, slightly inhomogeneous and lobulated mass with high signal intensity on T2-weighted image (A) and heterogeneous low signal intensity on T1-weighted image in mid portion of right frontal lobe (B). A second 4.5 x 2.5 cm sized, lobulated mass with same signal intensity is seen in the basal region of the right frontal lobe (arrows) (C). Mild peritumoral edema is associated. Contrast enhanced axial T1-weighted MR image demonstrates inhomogeneous contrast enhancement of the mass with cystic portion (D). The other smaller mass shows extension to the right ethmoid sinus (arrows) (E).

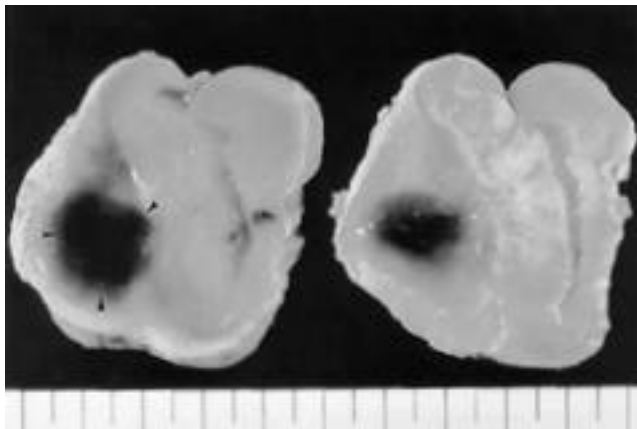


Fig. 3. Surgical specimen of larger tumor obtained from the right frontal lobe show a dumbbell shaped mass with firm and myxoid tissue. Area of hemorrhage (arrow heads) is seen within the specimen.

Myxomas are the most common cardiac neoplasms and can also metastasize to the brain (4). Primary sarcomas of the heart are rare and constitute less than 25% of primary cardiac tumors (5). There are various primary cardiac sarcomas, including angiosarcoma, malignant fibrous histiocytoma, leiomyosarcoma, myxosarcoma, fibrosarcoma, rhabdomyosarcoma, and undifferentiated sarcoma. According to Bruke et al. (1), angiosarcomas are the most common type of sarcomas which can metastasize to the brain. However, chondrosarcoma of the heart is not included, and metastasis of cardiac chondrosarcoma to the brain has not been reported.

A similar case in which a primary cardiac fibrosarcoma metastasized to the brain represented the solitary metastatic recurrence of the sarcoma after resection of the primary tumor through cardiac transplantation (6). Our case and that case differ both with regard to the histologic type of the sarcoma and the absence of intracerebral hemorrhage. Initial radiologic evaluation of our patient failed to reveal evidence of either local thoracic recurrence or remote metastasis. No remnant mass in the left atrium was seen on postoperative CT scans. Two years after cardiac surgery, metastasis to the frontal lobe had occurred.

The long-term prognosis of primary cardiac sarcoma is generally poor, with recurrence being the rule. Systemic metastasis is present in 80% of cases at first diagnosis (5). The mean survival rate of cardiac sarcoma patients is usually no longer than 20 months. Our patient has been alive for more than 20 months after cardiac surgery and initial diagnosis revealed no evidence of distant metastasis. Because of the rarity of cardiac sarcomas, their metastatic potential and behavior have not been widely

described in the literature. Although the number of reported cases of cardiac tumor metastatic to the brain is too few to suggest a mechanism of tumor spread, it is possible that hematogeneous spread with intracerebral invasion is a common route of dissemination for both cardiac myxomas and sarcomas (6).

Histologically, the chondrosarcoma may be classified into three types: differentiated (conventional), mesenchymal, and dedifferentiated. Conventional chondrosarcoma is the most common type. Intraosseous chondrosarcoma has a lobulated appearance with intermediate signal intensity on T1-weighted images and high signal intensity on T2-weighted images, regardless of pathologic type (7). In osseous and soft tissue tumors originating from hyaline cartilage, MRI has shown homogeneous high signal intensity on T2-weighted images. Chhem et al. (8) reported primary mesenchymal chondrosarcoma of the brain presenting as a solid tumor, in addition to evidence of hemorrhage. The tumor showed inhomogeneous high signal intensity on T2-weighted images, representing hemorrhagic foci. Although the tumor in our cases is metastatic, its signal intensity is similar to that of a chondrosarcoma.

As seen on MRI, the signal intensity of brain metastasis varies. Most nonhemorrhagic intracerebral metastases are slightly hypointense relative to brain on T1-weighted image and hyperintense on T2-weighted images (3). Some nonhemorrhagic metastatic tumors such as malignant melanoma are hyperintense on T1-weighted images (9) and adenocarcinoma of the gastrointestinal tract which metastasizes to the brain commonly shows decreased signal intensity on T2-weighted images (3). The metastatic masses seen in our case also show a signal intensity similar to that shown by brain metastasis, with similar enhancement and location. The peritumoral edema, however, appears less extensive than that seen in other typical metastatic tumors and the focal cystic portion seen within the mass corresponds to myxoid degeneration.

Cardiac chondrosarcomas are rare. However, when they do arise, and surgical resection is undertaken, follow-up brain MR should form part of the postoperative care, regime, along with dedicated follow-up thoracic imaging to evaluate local recurrence.

## References

1. Burke AP, Cowan D, Virmani R. Primary sarcomas of the heart. *Cancer* 1992; 69: 387-395
2. Bashi VV, Walter A, John S. Primary chondrosarcoma of

- heart. *Indian J Chest Dis & All Sci* 1989; 31: 203-206
3. Egelhoff JC, Ross JS, Modic MT, Masaryk TJ, Estes M. MR imaging of metastatic GI adenocarcinoma in brain. *AJNR* 1992; 13: 1221-1224
  4. Ng HK, Poon WS. Cardiac myxoma metastasing to the brain: case report. *J Neurosurgery* 1990; 72: 295-298
  5. Siverman NA. Primary cardiac tumors. *Ann Sur* 1980; 191: 127-138
  6. Colon G, Quint DJ, Blaivas M, McGillicuddy J. Cardiac sarcoma metastatic to the brain. *AJNR* 1995; 16: 1739-1741
  7. Varma DG, Ayala AG, Carrasco CH, Guo SQ, Kumar R, Edeiken J. Chondrosarcoma: MR imaging with pathologic correlation. *Radiographics* 1992; 12: 687-704
  8. Chhem RK, Bui BT, Calderon-Villar H, Fontaine S. Case report: primary mesenchymal chondrosarcoma of the brain. *Clin Radiol* 1992; 45: 422-423
  9. Atlas SW, Braffman BH, LoBrutto R, Elder ED, Herlyn D. Human malignant melanomas with varying degrees of melanin content in nude mice: MR imaging, histopathology, and electron paramagnetic resonance. *J Comput Assist Tomogr* 1990; 14: 547-554

1999;40: 657- 660

