

Achromobacter xylosoxidans Infection Following Total Knee Arthroplasty

Su Chan Lee, M.D., Chang Hyun Nam, M.D.[✉], Il Seok Park, M.D.,
Ji Yeol Yoon, M.D.*, Kwang Am Jung, M.D., and Seung Hyun Hwang, M.D.

Departments of Orthopaedic Surgery and *Internal Medicine, Joint & Arthritis Research, Himchan Hospital, Seoul, Korea

Achromobacter xylosoxidans is an opportunistic organism, mainly causing infection in immune compromised hosts, such as patients on dialysis. However, review of the medical literature showed that few cases of *A. xylosoxidans* infections following total knee arthroplasty have been reported. This organism has not been reported in prosthetic joint infections of patients who are not immune compromised. Here, a case of periprosthetic infection with *A. xylosoxidans* following total knee arthroplasty in a man with no medical history of immune suppression is reported.

Key words: total knee arthroplasty, deep infection, *Achromobacter xylosoxidans*

Achromobacter xylosoxidans was first described and named by Yabuuchi and Oyama¹⁾ in 1971 after it was isolated from human ear discharge. *A. xylosoxidans* was recognized as a distinct aerobic, nonfermenting gram-negative bacteria.²⁾ The organism is ubiquitous and often encountered in aqueous environments, such as swimming pools, dialysis baths, and tap water.^{1,3)} *A. xylosoxidans* is an opportunistic bacteria, mainly causing infections in immune compromised hosts. Only one case of periprosthetic infection by *A. xylosoxidans* has been reported.⁴⁾ The patient in this case was receiving high dose prednisone for rheumatoid arthritis.⁴⁾ Here, a case of periprosthetic infection with *A. xylosoxidans* following a total knee arthroplasty is reported in a man with no medical history of immune suppression.

CASE REPORT

A 52-year-old man underwent right primary total knee arthroplasty for osteoarthritis at our hospital in March 2008. The patient's medical history included pulmonary tuberculosis treated and cured with medication 18 years ago, and hypertension being treated with medi-

cation. The patient had no medical history of immune suppression. On preoperative physical examination, soft tissue of the proximal and anterolateral compartments of the right lower leg showed atrophy with scar change compared to contralateral leg, which was related to the history of car accident injury requiring skin graft at the age of seven. Patella baja and osteoarthritic changes were seen on radiology evaluation. No abnormal findings were recorded at the time of the surgical procedure; the skin incision was performed on the medial side to maintain a distance from the skin scar site. However, four weeks after the total knee arthroplasty, the patient complained of pain with redness and local heat on the distal portion of the incision line in his right knee. The patient was admitted to the hospital for suspicious surgical wound infection. We regarded it as a superficial infection and did not aspirate the joint fluid at that time for fear of spreading infective microorganism into the knee joint. C-reactive protein (CRP) level was 0.54 mg/dl (normal: below 0.3). He was treated with intravenous antibiotic therapy with cefazolin 2 g three times a day and then ciprofloxacin was added as 400 mg intravenous every 12 hours after observing inadequate improvement in skin color and tenderness to initial cefazolin treatment. Blood culture result, which was the only possible microbiologic laboratory workup, showed no identifiable microorganism. After the 15 days course of antibiotic treatment, symptoms improved and the patient was discharged switching to oral antibiotic therapy with ciprofloxacin.

Received December 30, 2013 Revised April 18, 2014 Accepted June 10, 2014

✉Correspondence to: Chang Hyun Nam, M.D.

Department of Orthopedic Surgery, Mokdong Himchan Hospital, 120 Sinmok-ro, Yangcheon-gu, Seoul 158-806, Korea

TEL: +82-2-3219-9114 FAX: +82-2-3219-9126 E-mail: changcape@naver.com

cin 1,000 mg/d and fusidate Na 1,000 mg/d with an intent to prevent any further deep site infection focusing on gram positive biofilm making microorganism. Total of 3 months course of oral antibiotic therapy was completed and the infection seemed to be cured.

A year after discharge the patient presented with aggravation of symptoms showing fluctuation of laboratory findings such as elevated CRP levels of 0.67 to 4.86 mg/dl. Joint fluid aspiration was done and synovial leukocyte count was $1,125/\text{mm}^3$, with differential count of 91% neutrophils. During follow-up period after the first arthrocentesis, joint fluid was aspirated on four occasions repeatedly for a microbiologic culture study. But the culture studies including bacterial, fungal and *Mycobacteria tuberculosis* were all negative and the polymerase chain reaction (PCR) for *M. tuberculosis* showed negative results. Antibiotics were prescribed intermittently (levofloxacin 200 mg/d), and his signs were closely monitored.

After 18 months from the total knee arthroplasty, despite the early attempt of eradication of probable superficial surgical infection with antibiotics, the patient developed a sinus tract in the right knee with purulent discharge. Repeated joint fluid analysis showed a synovial leukocyte count of $14,004/\text{mm}^3$ with 92% neutrophils. Culture studies showed negative results again. Under the impression of deep prosthesis infection, a two-stage reimplantation operation was recommended but the patient absolutely refused. Debridement and irrigation with soft tissue repair was planned as the patient hardly accepted the recommendation of medical staffs. The patient was hospitalized and underwent only surgical debridement of the sinus tract and empirical treatment with antibiotic therapy. Tissue and sy-

novial fluid specimens on the operation were sent for cultures at the time of debridement. Both tissue and synovial fluid cultures from the operative specimen revealed *A. xylosoxidans* as the causative organism. The patient then received intravenous antibiotics (imipenem 500 mg every eight hours) according to the results of the antibiotic sensitivity testing. After treatment with imipenem, pain and wound discharge seemed to improve. However, three weeks later the symptoms were again aggravated; there was purulent discharge from the right knee joint. An X-ray showed loosening of the femoral component (Fig. 1). The patient was then scheduled for a two-stage revision of the infected total knee arthroplasty. Aspiration of the knee joint was performed before implant removal surgery and culture identified repeatedly the growth of *A. xylosoxidans*.

At the first-stage revision surgery for removal of implant, there was pus within the joint space and loosening of both the femoral and tibial prosthetic components. A thorough washout, debridement, and complete synovectomy were performed.

A temporary articulating knee spacer with antibiotic (vancomycin 1 g per batch) mixed cement was used in attempt to prevent further gram positive microorganism co-infection. After this, a five-week course of intravenous imipenem was started. The second-stage of the revision was performed seven weeks after the first stage with two weeks of observation without imipenem to confirm eradication of previous infectious microorganism. Clinically, the knee was cool, non-tender, and showed no external signs of infection. The CRP was decreasing and was 0.36 mg/dl (normal: below 0.3) before the second stage procedure. The microbiology and histology samples from the second-stage revision for new implant insertion demonstrated no growth on tissue and synovial fluid cultures including the bacterial, fungal and *M. tuberculosis* cultures; in addition, the *M. tuberculosis* PCR was negative. Twelve months after the second-stage surgery, the patient was clinically well and reported no pain in the knee. Physical examination revealed no signs of infection or instability during routine follow-up.

DISCUSSION

A. xylosoxidans is an aerobic, oxidase- and catalase-positive, non-lactose fermenting, gram-negative bacillus widely distributed in the natural environment.³ It is an opportunistic human pathogen capable of causing a variety of infections, including bacteremia, meningitis, pneumonia, peritonitis, endocarditis, and pyelonephritis. Those who are immune suppressed or have underlying diseases related to immune compromised status are especially vulnerable.⁵ Despite the

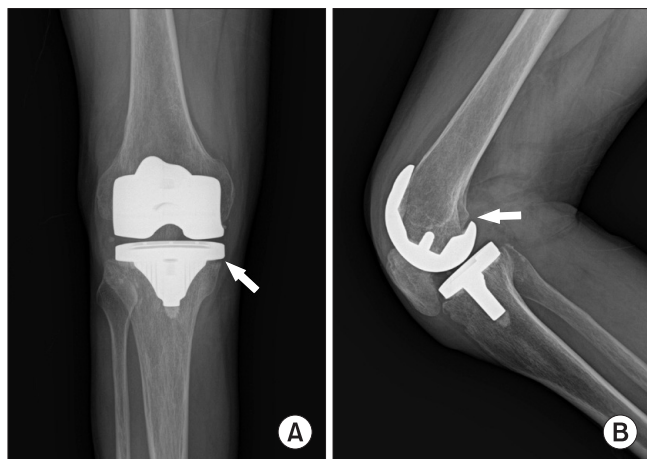


Figure 1. Radiograph of the right knee shows loosening of the tibial and femoral components before removal of the prosthesis. (A) The anterior-posterior view illustrates lucency (arrow) around the medial aspect of the tibial component. (B) The lateral view also shows a radiolucent area (arrow) surrounding the femoral and tibial components.

high volume of arthroplasty procedures, periprosthetic joint infection due to *A. xylosoxidans* has rarely been reported. Review of the literature showed only one case report of septic arthritis caused by this organism after a total knee arthroplasty. The patient in that case had rheumatoid arthritis and was receiving high doses of prednisone, in which both conditions contributed to immune compromise.⁴⁾ There have been no previously reported cases of infection with *A. xylosoxidans* following total knee arthroplasty in patients without underlying immune compromised status or immune suppression.

In this case, four weeks after initial total knee arthroplasty, signs of infection developed in the right knee and antibiotic therapy was started under the impression of superficial wound infection. It is not evident yet that the joint fluid aspiration should be always performed under the suspicious superficial infection after prosthesis surgery, which is usually indistinguishable from a hidden deep seated infection. The physician should make a balance between the benefit and the risk of arthrocentesis under that condition. When the pain and redness reappeared after substantial period, 6 months from the initial response to the empirical antibiotic treatment, four repeated joint fluid aspiration procedures with cultures workup were performed but reported as negative results. In this case, because antibiotics were used prior to the joint aspiration, the synovial fluid culture might have been falsely negative. In addition, the value of microbiological cultures for the diagnosis of late periprosthetic infections is limited; standard methods may fail to detect biofilm-forming sessile or other fastidious slow growing bacteria.⁶⁾

A. strains are frequently resistant to aminoglycosides, ampicillin, first- and second-generation cephalosporins, and chloramphenicol. However, they typically respond to anti-*Pseudomonas* third-generation cephalosporins, carbapenems, and trimethoprim-sulfamethoxazole. Carbapenems are the most active antimicrobial drugs, especially meropenem (MIC₅₀, 0.25 µg/ml; 88% susceptible), which is four-times more potent than imipenem (MIC₅₀, 2 µg/ml; 84% susceptible).⁷⁾ In this case, various empirical antibiotic therapy for the most common causative microorganism of prosthesis infection, gram positive cocci, were tried as a single therapy or in combination, including cefazolin, ciprofloxacin, fusidate Na, and rifampicin until the definite causative microorganism, *A. xylosoxidans* was identified. The eradication of infection was impossible at an early stage because of the lack of information about causative organism and antibiotic susceptibility test. However, the prosthetic joint infection could not be cured despite the appropriate antibiotic therapy, imipenem. In chronic infections of a prosthetic joint, biofilms are likely to develop

and implant retention is hardly successful because the resistance of biofilm to antibiotics which is even recommended in vitro sensitivity test. A complete cure usually requires both implant removal and appropriate antibiotics treatment.⁸⁾ In this case, revision of the total knee arthroplasty was successful after removal of the joint prosthesis and imipenem treatment after initial failure of imipenem treatment alone.

This case demonstrates that *A. xylosoxidans* is a pathogen capable of causing prosthetic joint infection even in immunocompetent patients and implies that to cure the infection of late stage, removal of implant, thorough debridement & appropriate antibiotic treatment is essential for the success of revision surgery.

REFERENCES

1. Yabuuchi E, Oyama A. *Achromobacter xylosoxidans* n. sp. from human ear discharge. *Jpn J Microbiol.* 1971;15:477-81.
2. Coenye T, Vancanneyt M, Falsen E, Swings J, Vandamme P. *Achromobacter insolitus* sp. nov. and *Achromobacter spanius* sp. nov., from human clinical samples. *Int J Syst Evol Microbiol.* 2003;53:1819-24.
3. Reverdy ME, Freney J, Fleurette J, et al. Nosocomial colonization and infection by *Achromobacter xylosoxidans*. *J Clin Microbiol.* 1984;19:140-3.
4. Taylor P, Fischbein L. Prosthetic knee infection due to *Achromobacter xylosoxidans*. *J Rheumatol.* 1992;19:992-3.
5. Ramos JM, Domine M, Ponte MC, Soriano F. Bacteremia caused by *Alcaligenes* (*Achromobacter*) *xylosoxidans*. Description of 3 cases and review of the literature. *Enferm Infecc Microbiol Clin.* 1996;14:436-40.
6. Schäfer P, Fink B, Sandow D, Margull A, Berger I, Frommelt L. Prolonged bacterial culture to identify late periprosthetic joint infection: a promising strategy. *Clin Infect Dis.* 2008;47:1403-9.
7. Gales AC, Jones RN, Andrade SS, Sader HS. Antimicrobial susceptibility patterns of unusual nonfermentative gram-negative bacilli isolated from Latin America: report from the SENTRY Antimicrobial Surveillance Program (1997-2002). *Mem Inst Oswaldo Cruz.* 2005;100:571-7.
8. Frommelt L. Principles of systemic antimicrobial therapy in foreign material associated infection in bone tissue, with special focus on periprosthetic infection. *Injury.* 2006;37 Suppl 2:S87-94.

슬관절 전치환술 환자에서 발생한 *Achromobacter xylosoxidans*에 의한 감염

이수찬 • 남창현[✉] • 박일석 • 윤지열* • 정광암 • 황승현

힘찬병원 관절염연구소 정형외과, *내과

*Achromobacter xylosoxidans*는 기회 균주로 주로 투석 환자 등의 면역저하 환자에서 감염을 일으킨다. 그러나 슬관절 전치환술 후, *A. xylosoxidans* 감염에 관한 보고는 매우 드물며, 정상 면역 환자에서 이 균주의 슬관절 전치환술 감염의 관한 보고는 없었다. 이에 우리는 면역저하 병력이 없는 슬관절 전치환술 환자의 *A. xylosoxidans*에 의한 감염 증례를 보고하고자 한다.

색인단어: 슬관절 전치환술, 심부감염, *Achromobacter xylosoxidans*

접수일 2013년 12월 30일 수정일 2014년 4월 18일 게재확정일 2014년 6월 10일

[✉]책임저자 남창현

서울시 양천구 신목로 120, 목동 힘찬병원 정형외과

TEL 02-3219-9114, FAX 02-3219-9126, E-mail changcape@naver.com