

The Atlanto-Axial Rotatory Fixation in Adult Treated by Non-Surgical Approach

Chae Hong Lim, MD, Mou Seop Lee, MD, PhD, Byeong Cheol Rim, MD, PhD,
Kyung Su Min, MD, PhD, Young Gyu Kim, MD, PhD and Dong Ho Kim, MD, PhD

Department of Neurosurgery, Chungbuk National University School of Medicine & Medical Research Institute, Cheongju, Korea

The atlanto-axial rotatory fixation (AARF) is a rare clinical condition that occurs more commonly in children than in adults. It is easy to misdiagnose AARF because of peculiar feature of atlanto-axial articulation. The authors reported a case of AARF in an adult who was treated by im-mobilization without surgery. Due to a traffic accident, the patient's head was forcefully rotated to the right side and flexed to the left side. The patient had no neurological deficit, but the patient's head was fixed in a position rotated to the right and tilted to the left. In open mouth view and three dimensional CT reconstruction images the atlas was rotated to the right side and the anterior lip of left superior facet and left transverse process of axis were fractured. The patient underwent intermittent Halter-traction for seven days. After the Halter-traction, we gained successful reduction and posterior neck pain was subsided. After the reduction, Halo-vest was applied for three months and the patient recovered well without any neurological deficits. In some case of adult traumatic AARF patient, closed reduction and Halo-vest external fixation may be successful instead of open reduction and fixation. And if it is successful, we can avoid operative procedure. (J Kor Neurotraumatol Soc 2010;6:70-73)

KEY WORDS: Atlantoaxial subluxation · Rotatory fixation · Conservative management.

Introduction

Rotatory deformity of the atlanto-axial joint was termed by Wortzman and Dewar in 1968.¹⁷⁾ In 1977, Fielding and Hawkins²⁾ described atlanto-axial rotatory fixation (AARF) as a persistent rotatory deformity of the atlanto-axial joint caused by subluxation or dislocation of the articular surfaces.

The condition is usually associated with an infection or a traumatic event, but it may also arise spontaneously or in association with other conditions. It occurs much more frequently in children than in adult, because of the unique biomechanical features of the atlanto-axial articulation. In children, the joint surface of the lateral mass is shallower and more horizontally oriented.⁵⁾ In addition, the relative elas-

ticity of the ligaments, the not yet fully developed neck muscles, and the relatively large head might be predisposing factors for AARF.⁵⁾ We report a rare case of post-traumatic AARF in an adult that was treated by Halter-traction and Halo-vest.

Case Report

A 50-year-old male patient was transferred to the emergency room after a traffic accident that had occurred the day before. He complained of severe neck pain. Neurological examination was normal but his head was fixed in a position rotated to the right side and tilted to the left side. Initially, the patient underwent intermittent Halter-traction with seven pounds for twenty-four hours at another hospital. Unfortunately, the reduction failed, and the patient was transferred to our unit for further treatment. Cervical spine open mouth radiography showed the left C1 lateral mass to be closer to the odontoid process than the right one (Figure 1). Three-dimensional surface re-constructions of the CT images showed that the atlas was rotated to the right side and the anterior lip of the left superior facet of the C2 vertebra and the left transverse process of the C2 vertebra were

Received: April 12, 2010/ **Revised:** April 19, 2010

Accepted: June 9, 2010

Address for correspondence: Mou Seop Lee, MD, PhD
Department of Neurosurgery, Chungbuk National University School of Medicine & Medical Research Institute, 410 Seongbong-ro, Heungdeok-gu, Cheongju 361-763, Korea
Tel: +82-43-269-6378, Fax: +82-43-273-1614
E-mail: mslee@chungbuk.ac.kr

This work was supported by the research grant of the Chungbuk National University in 2008.

FIGURE 1. Cervical spine radiography (A) and the diagram (B) showing a abnormal position of the dens axis. A: Cervical spine open mouth radiography showed the left C1 lateral mass which is closer to the odontoid process than right one. B: Diagram of the atlas was rotated to the right compared to the axis.

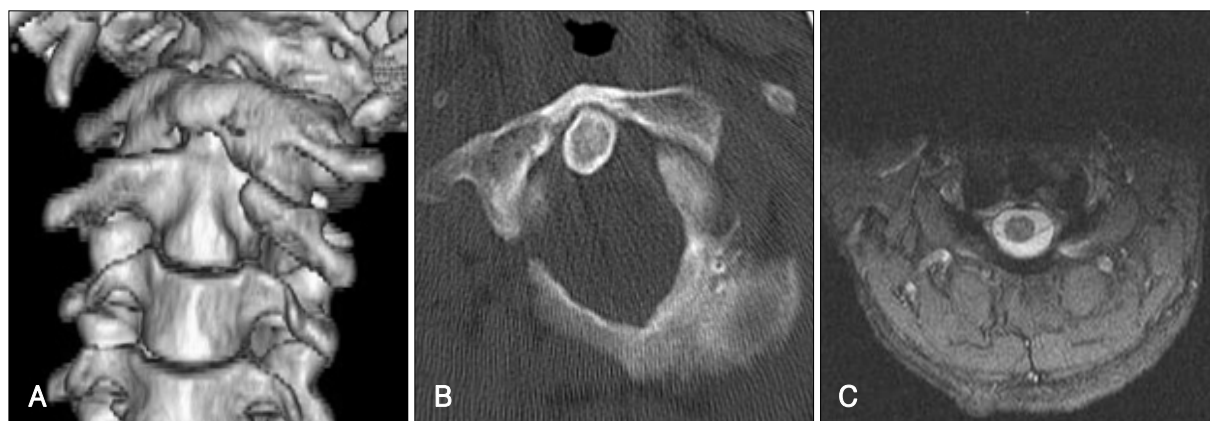
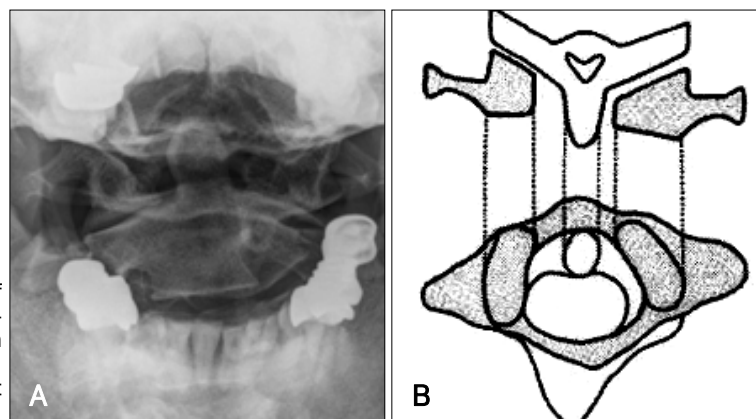


FIGURE 2. Pre-reduction radiologic examination. A: Three-dimensional surface reconstructions of CT showed the atlas was rotated to right side and the anterior lip of left superior facet of C2 vertebra and left transverse process of C2 vertebra was fractured. B: Cervical spine CT revealed the atlas was rotated to the right compared to the axis. C: Cervical spine MRI revealed no evidence of cord injury.

fractured. Fortunately, cervical spine MRI revealed no evidence of cord injury (Figure 2). After applying the halter-traction for seven days, successful reduction was gained and neck pain was diminished. After that, neck pain was resolved rapidly. After successful closed reduction, the patient was advised to wear a halo-brace for three months. After three months, follow-up radiograph images confirmed that the atlas and axis has been completely corrected and the patient was relieved of the neck pain without any neurological deficits (Figure 3). Then the patient wore a Philadelphia brace for three months and received rehabilitation therapy care for a year. The patient did not show any range of motion limitations and the neurological examination and the follow-up radiographic examination were normal.

Discussion

The atlanto-axial joint is unique and complex.¹³⁾ The primary function of the atlanto-axial joints is rotation rather than flexion or extension.³⁾ The transverse ligament is the primary stabilizer of the atlanto-axial joint, and prevents

forward subluxation of the atlas on the axis during head flexion.¹²⁾ The alar ligaments also prevent excessive rotation at the atlanto-axial joints.⁵⁾ Rotatory fixation may be associated with anterior or, rarely, posterior displacement of the atlas on the axis.³⁾ The common cause of AARF is usually an infection or a traumatic event,³⁾ but other conditions such as ankylosing spondylitis,⁷⁾ metastatic tumor,¹⁶⁾ generalized ligamentous laxity,⁹⁾ eosinophilic granuloma,⁹⁾ and following a suboccipital craniotomy and C1-3 laminectomy¹⁵⁾ have also been reported.

The pathophysiology of these lesions are not well defined.⁴⁾ Wortzman and Dewar¹⁷⁾ concluded that the rotational fixation is not due to a fracture or ligamentous rupture but to damage of an unknown nature at the atlanto-axial joint itself. At the same time, they noted that the most believable theory is a tear and invagination of capsular ligaments the atlanto-axial synovial joints. Fielding and Hawkins²⁾ concluded that swollen capsular and synovial tissues and muscle spasm prevent reduction in the early stages and that ligament and capsular contractures develop later, causing fixation. The patient suffering from AARF present with

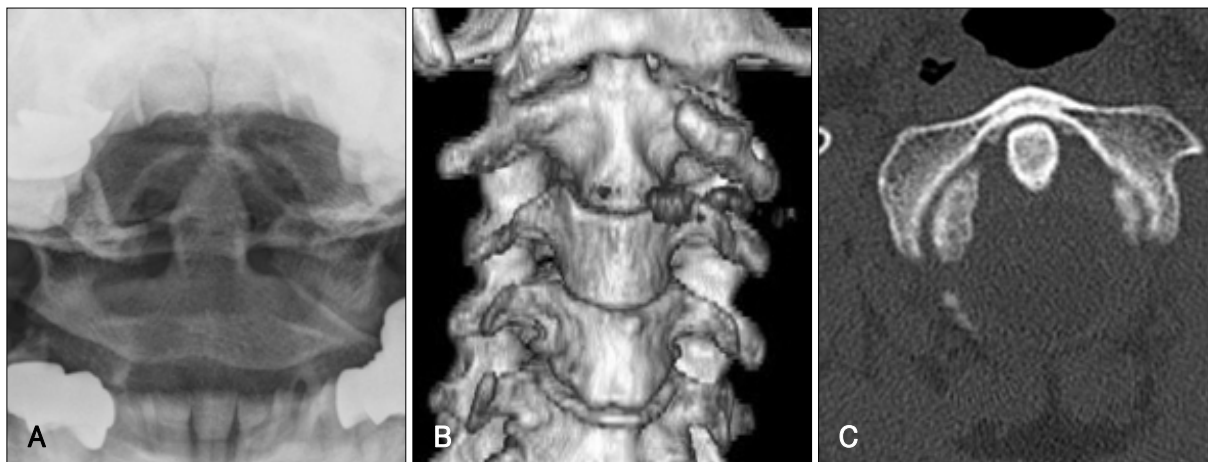


FIGURE 3. Post-reduction radiologic examination. A: Post-reduction cervical spine open mouth radiography shows successful reduction of cervical spine. B: Follow up three-dimensional surface reconstructions of CT shows successful reduction of cervical spine (three month later). C: Follow up cervical spine CT revealed the atlas and axis has been completely corrected (three month later).

persistent torticollis and ‘cock robin position’, where the head is tilted to one side and rotated to the other side. These are important clinical manifestations of this condition.^{2,3,14)}

Diagnosis is often delayed in this condition. CT scanning is the best method to detect this abnormality, and three dimensional CT reconstruction can demonstrate subluxation.^{2,3)} A CT scan that reveals an atlantoaxial injury would justify performing further imaging with MR studies.¹¹⁾

Fielding and Hawkins²⁾ described four types of AARF based on the extent of the shift of C1 on C2 and the integrity of transverse ligament, which have been widely accepted. Type I is the most common pattern and the transverse ligament is intact. The fixed atlanto-axial rotation is symmetrical and within the normal range of rotation for atlanto-axial joints. Type II deformity is associated with mild deficiency of the transverse ligament with an atlanto-dental interval (ADI) of 3 to 5 mm. The intact joint acts as the pivot point for unilateral anterior displacement of the opposite side. Type III deformity is greater than 5 mm ADI, with deficiency of both transverse ligament and alar ligament. Type IV lesion is described as a posterior shift of one or both lateral masses of the atlas. This classification provides some guidance as to prognosis and treatment. In 1994, Li and Pang⁸⁾ attempted to more clearly define this disorder, to establish criteria for its diagnosis, and to provide guidelines for its management.

The usual physiotherapeutic measures (immobilization, traction) will usually help in the early stage of the clinical presentation.¹²⁾ Generally, early stage of AARF closed reduction can be achieved easily. Optimal management of AARF depends on early diagnosis. Roche et al.¹³⁾ concluded that if the abnormality is detected within 1 month of onset, then traction in combination with muscle relaxants and an-

algesia is recommended and prognosis for recovery is good. Moreover, if the diagnosis is delayed more than three months, most of the patients need surgical fusion. The delayed diagnosis led to elevated rates of recurrence and failure of non-surgical reduction.¹⁰⁾ Therefore, if the diagnosis could be made as soon as possible, good results may be achieved by non-surgical approach. But, in spite of the adequate time interval for diagnosis, the surgical approach-fusion-is needed for cases of AARF with neural involvement and spinal instability, and in cases of failure to maintain reduction by conservative measures.^{2,13)}

Fortunately, the diagnosis was made within a month and the Halter-traction was applied instantly, successfully achieving reduction. Afterwards, although controversial, we judged that a Philadelphia brace would not give enough fixation support, therefore in order to achieve a stronger fixation effect we applied a Halo-vest, external immobilization. The patient was followed up for 6 months and he presented a good outcome.

Conclusion

Misdiagnosis of AARF is more common in adults than in children, because the incidence of AARF in adults is lower than that in children.¹³⁾ Patients may be treated with non-surgical approach due to early diagnosis. Therefore, when ‘cock robin’, the typical posture and neck motion limitation, is found in adults with head trauma, the immediate and accurate diagnosis is essential to prevent surgery.

We reported a case of post traumatic AARF in adults which recovered completely without surgery. Precise diagnosis and an early treatment are the keys to prevent operative treatment.

REFERENCES

- 1) Crossman JE, Thompson D, Hayward RD, Ransford AO, Crockard HA. Recurrent atlantoaxial rotatory fixation in children: a rare complication of a rare condition. Report of four cases. **Neurosurg** 100: 307-311, 2004
- 2) Fielding JW, Hawkins RJ. Atlanto-axial rotatory fixation. (Fixed rotatory subluxation of the atlanto-axial joint). **J Bone Joint Surg Am** 59:37-44, 1977
- 3) Goddard NJ, Stabler J, Albert JS. Atlanto-axial rotatory fixation and fracture of the clavicle. An association and a classification. **J Bone Joint Surg Br** 72:72-75, 1990
- 4) Jeon SW, Jeong JH, Moon SM, Choi SK. Atlantoaxial rotatory fixation in adults patient. **J Korean Neurosurg Soc** 45:246-248, 2009
- 5) Kim YS, Lee JK, Kim JH, Kim SH. Post-traumatic atlantoaxial rotatory dislocation in an adult treated by open reduction and C1-C2 transpedicular screw fixation. **J Korean Neurosurg Soc** 41: 248-251, 2007
- 6) Kombogiorgas D, Hussain I, Sgouros S. Atlanto-axial rotatory fixation caused by spontaneous intracerebral haemorrhage in a child. **Childs Nerv Syst** 22:1182-1186, 2006
- 7) Leventhal MR, Maguire JK Jr, Christian CA. Atlantoaxial rotary subluxation in ankylosing spondylitis. A case report. **Spine (Phila Pa 1976)** 15:1374-1376, 1990
- 8) Li V, Pang D. Atlanto-axial rotatory fixation, in Pang D (ed): Disorders of the pediatric spine. New York: Raven Press, pp531-553, 1995
- 9) Marar BC, Balachandran N. Non-traumatic atlanto-axial dislocation in children. **Clin Orthop Relat Res**:220-226, 1973
- 10) Munch C, Linhart W, Storck A, Papavero L, Windolf J, Rueger JM, et al. [Treatment of traumatic rotatory atlanto-axial subluxation in childhood. Case report and literature review.] **Unfallchirurg** 108: 987-990, 2005
- 11) Rahimi SY, Stevens EA, Yeh DJ, Flannery AM, Choudhri HF, Lee MR. Treatment of atlantoaxial instability in pediatric patients. **Neurosurg Focus** 15:ECP1, 2003
- 12) Rinaldi I, Mullins WJ Jr, Delaney WF, Fitzer PM, Tornberg DN. Computerized tomographic monstration of rotational atlanto-axial fixation. **J Neurosurg** 50:115-119, 1979
- 13) Roche CJ, O'Malley M, Dorgan JC, Carty HM. A pictorial review of atlanto-axial rotatory fixation: key points for the radiologist. **Clin Radiol** 56:947-958, 2001
- 14) Sohn MJ, Rhim SC, Roh SW, Park HC. Atlantoaxial rotatory fixation: report of 3 cases. **J Korean Neurosurg Soc** 29:580-585, 2000
- 15) Taddonio RF Jr, King AG. Atlantoaxial rotatory fixation after decompressive laminectomy. A case report. **Spine (Phila Pa 1976)** 7: 540-544, 1982
- 16) White GM, Healy WL. Tumor-associated atlanto-axial rotatory fixation. A case report. **Spine (Phila Pa 1976)** 12: 406-408, 1987
- 17) Wortzman G, Dewar FP. Rotatory fixation of the atlantoaxial joint: rotational atlantoaxial subluxation. **Radiology** 90:479-487, 1968