

Orthostatic Headache Diagnosed by Computed Tomography Myelography

Hyun Hee Ye, MD, Chang Won Cho, MD, PhD, Yoon Suk Kim, MD, Jae Hun Cha, MD, Jae Sung Park, MD and Dae Jo Kim, MD, PhD

Department of Neurosurgery, Maryknoll Hospital, Busan, Korea

Intracranial hypotension seems to be caused by cerebrospinal fluid (CSF) leakage from a spinal meningeal diverticulum or dura tear. It is characterized by orthostatic headache and diffuse meningeal enhancement on gadolinium-enhanced brain magnetic resonance imaging. Site of CSF leakage could be disclosed with radioisotope cisternography, and computed tomography myelography is useful when cisternography failed to unravel anatomical information. Epidural blood patch is very effective to stop the leakage. We report a case of orthostatic headache caused by intracranial hypotension in a 32-year-old woman. Computed tomography myelography confirmed a CSF leakage in the area of left L2 nerve root. The patient was successfully treated by epidural blood patch. (J Kor Neurotraumatol Soc 2007;3:116-118)

KEY WORDS: Computed tomography myelography · Epidural blood patch · Intracranial hypotension · Orthostatic headache.

Introduction

Intracranial hypotension is a syndrome of low cerebrospinal fluid (CSF) pressure characterized by orthostatic headache.^{10,15} This diminished intracranial pressure is attributed to a CSF leakage. The concept of a headache by the leak of CSF from a dural defect following a lumbar puncture was first suggested by Bier in 1889. Schaltenbrand first described the entity of intracranial hypotension syndrome (IHS) in the German literature in 1938, when he recognized spontaneously occurring low CSF pressure and thus, called it 'spontaneous or essential aliquorrhea'.

Precise determination of the spinal level of a CSF leak is important in diagnosis and treatment of the IHS.

Case Report

A previously healthy 32-year-old woman was transferred to our hospital with a severe postural headache, aggravated by sitting or standing and relieved by lying flat. She com-

plained of tinnitus in both ears, radicular tingling sense of both arms, nausea, vomiting, and mild neck stiffness. She had past medical history of unremarkable delivery for baby under an epidural anesthesia 10 months ago. Routine laboratory studies, including erythrocyte sedimentation rate, were normal. Lumbar puncture, performed with a 24-gauge needle at the L4-L5 interspace, revealed an opening pressure of 0 mmH₂O, and the "dry" tap made the CSF laboratory test impossible.

Gadolinium-enhanced brain magnetic resonance imaging (MRI) showed diffuse meningeal enhancement (Figure 1). Radioisotope (RI) cisternography revealed normal CSF flow pattern and no evidence of focal leakage of radioisotope.

IHS was strongly suspected, and it seemed to be caused by previous epidural anesthesia. Conservative treatment was instituted accordingly. Bed rest, hydration, caffeine and analgesics medications were provided for 4 weeks. However, the patient noted a persistent orthostatic headache. Follow up brain MRI still showed diffuse meningeal enhancement and slit ventricle.

In order to identify specific location of CSF leakage, computed tomography (CT) myelography was performed in the range from skull base to the sacrum level. A focal CSF leakage was found along the left L2 nerve root (Figure 2).

Address for correspondence: Chang Won Cho, MD, PhD
Department of Neurosurgery, Maryknoll Hospital, 12 Daecheong-dong 4-ga, Jung-gu, Busan 600-730, Korea
Tel: +82-51-461-2458, Fax: +82-51-466-6164
E-mail: braincwc@hotmail.com

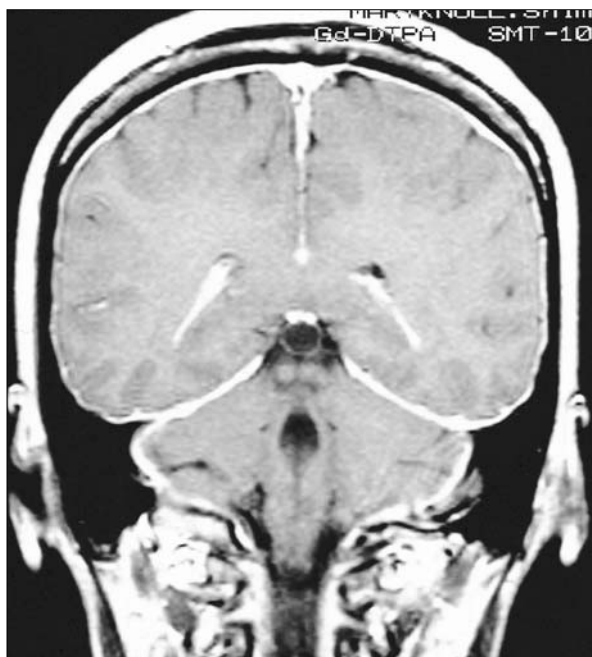


FIGURE 1. Coronal gadolinium-enhanced T1-weighted magnetic resonance image shows slit ventricle and intense enhancement of the dura including the tentorium.

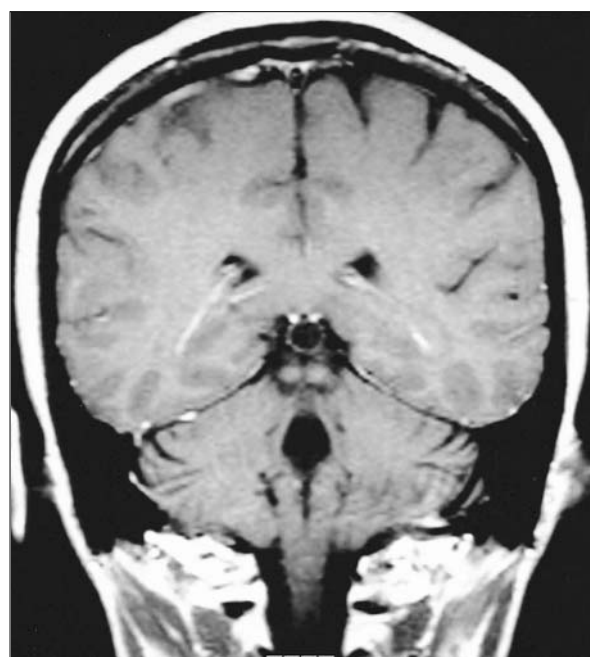


FIGURE 3. Follow up coronal gadolinium-enhanced T1-weighted magnetic resonance image shows normal ventricle size and no dural enhancement.

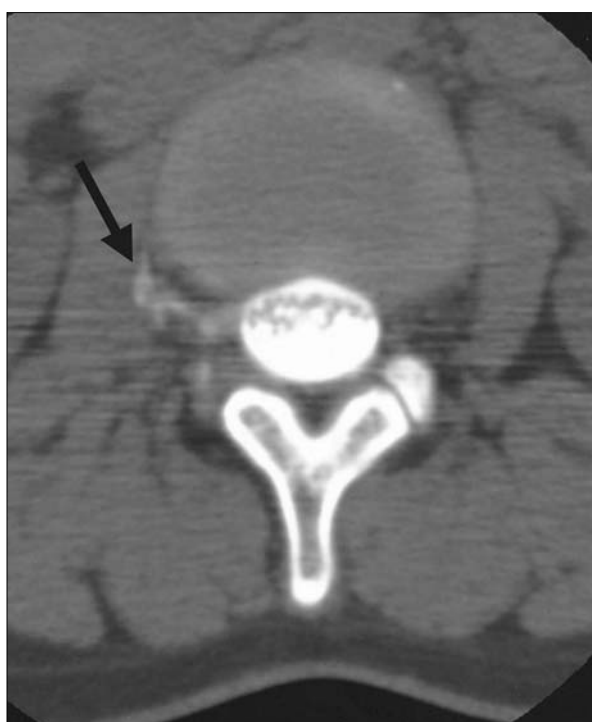


FIGURE 2. Axial computed tomography myelography demonstrates leakage of contrast material along the right L2 root sleeve (black arrow).

Ten ml of autologous blood was injected into the epidural space from the L2/3 level. Next day the postural headache and the other symptom resolved and she was discharged home two days following the procedure. Two weeks later,

a gadolinium-enhanced brain MRI scan showed recovered ventricle size without dural enhancement (Figure 3).

Discussion

Orthostatic headache represents the most characteristic symptom of IHS. Although the exact pathogenic mechanisms remain unclear, orthostatic headache is thought to result from continuous CSF loss through the dural defect. CSF loss interferes with the normal cushioning of the intracranial contents. As a result, intracranial contents may descend when the patient is standing upright, leading to traction on pain-sensitive structures in the dura mater. Other clinical manifestations in patients with IHS include nausea, vomiting, diplopia, dizziness, neck stiffness, tinnitus, visual blurring, radicular upper limb symptoms, mental impairment, in addition to symptoms and signs related to subdural hematomas.^{1,16)}

The diagnosis of IHS is usually made in conjunction with radiologic and serologic evidence in a patient with a probable past history. CSF findings include decreased opening pressure (0–30 mmHg),⁵⁾ elevated protein, and mild pleocytosis, whereas normal glucose, cytology, and Gram's stain. Inflammation due to traction on the bridging veins may have some role in the elevated protein and pleocytosis in the CSF.⁶⁾

A characteristic findings on gadolinium-enhanced MRI are diffuse meningeal enhancement and dural venous dila-

tation. Diffuse meningeal thickening and enhancement are probably related to engorgement of the meningeal blood vessels.³⁾ According to the Monro-Kellie rule, intracranial blood and CSF volume fluctuate reciprocally. And thus, reduced CSF volume results in venous engorgement, which causes a greater concentration of gadolinium-diethylene triamine pentaacetic acid (Gd-DTPA) in the meningeal vasculature.⁸⁾ But, these MRI findings usually disappear once the symptoms improve.⁷⁾

RI cisternography is useful to identify CSF leaks.¹³⁾ A CSF leak can be detected either directly by accumulation of radioactivity outside the subarachnoid space or indirectly by a limited ascent of the tracer to the cerebral convexities and its early accumulation in the kidneys, urinary bladder, and soft tissues.¹¹⁾ The sensitivity of RI cisternography was 60% with regard to diagnostic accuracy, Benamor.²⁾ Schievink¹⁵⁾ demonstrated the false negative rate was 30%.

CT myelography also has been used to demonstrate CSF leaks.^{13,15)} CT slices are obtained from the skull base to the sacrum through the entire spinal axis at each spinal level, after intrathecal injection of an iodinated contrast agent. Underlying anatomical defects responsible for the leak, including meningeal diverticula, can be further delineated with CT scan.¹⁵⁾

The headache of IHS typically resolves with conservative management including bed rest.¹²⁾ Non steroid anti-inflammatory drugs, intravenous or oral caffeine, theophylline, increasing CSF volume by hydration, increased salt intake, carbon dioxide inhalation, and steroid therapy have all been reported to be effective.^{9,13)} If the conservative management fails, epidural blood patches introduced by Gormley¹⁴⁾ are generally considered to be safe and effective alternatives. The first patch is effective in 85 to 90% of cases,⁹⁾ while the efficacy is heightened up to 98% by repeated patches.³⁾ The procedure is most effective if it is performed at or within one interspace of the leak.⁴⁾ If the level of the leak is unknown, however, the blood can be injected into the lumbar epidural space and the patient's head tilted downward. The blood slowly ascends to, and seals leaks in the thoracic and cervical meninges.³⁾ Surgical correction may be required when all the above treatment methods have failed, especially if a dural tear or other meningeal defect has been demonstrated.^{1,11)}

Conclusion

In intracranial hypotension, we must check up sites of

CSF leakage by radiologic study. In cases of negative RI cisternography with false negative rate of 30%, we recommend to conduct CT myelography to search CSF leakage site. An autologous epidural blood patch is an effective strategy for managing an orthostatic headache that is persisting or is aggravated despite conservative treatments.

REFERENCES

- 1) Akkawi N, Locatelli P, Borroni B, Agosti C, Pezzini A, Stefani R, et al. A complicated case of intracranial hypotension: diagnostic and management strategies. *Neurol Sci* 27:63-66, 2006
- 2) Benamor M, Tainturier C, Gravelleau P, Pierot L. Radionuclide cisternography in spontaneous intracranial hypotension. *Clin Nucl Med* 23:150-151, 1998
- 3) Brightbill TC, Goodwin RS, Ford RG. Magnetic resonance imaging of intracranial hypotension syndrome with pathophysiological correlation. *Headache* 40:292-299, 2000
- 4) Davenport RJ, Chataway SJ, Warlow CP. Spontaneous intracranial hypotension from a CSF leak in a patient with Marfan's syndrome. *J Neurol Neurosurg Psychiatry* 59:516-519, 1995
- 5) Evan RW, Mokri B. Spontaneous intracranial hypotension resulting in coma. *Headache* 42:159-160, 2002
- 6) Ferrante E, Riva M, Gatti A, Brioschi AM, Guccione A, Colombo N, et al. Intracranial hypotension syndrome: neuroimaging in five spontaneous cases and etiopathogenetic correlations. *Clin Neurol Neurosurg* 100:33-39, 1998
- 7) Frank LR, Paxson A, Brake J. Spontaneous intracranial hypotension-a case report. *J Emerg Med* 28:427-430, 2005
- 8) Good DC, Ghobrial M. Pathologic changes associated with intracranial hypotension and meningeal enhancement on MRI. *Neurology* 43:2698-2700, 1993
- 9) Leibold RA, Yealy DM, Coppola M, Cantees KK. Post-dural-puncture headache: characteristics, management, and prevention. *Ann Emerg Med* 22:1863-1870, 1993
- 10) Marcelis J, Silberstein SD. Spontaneous low cerebrospinal fluid pressure headache. *Headache* 30:192-196, 1990
- 11) Mokri B, Piepgras DG, Miller GM. Syndrome of orthostatic headaches and diffuse pachymeningeal gadolinium enhancement. *Mayo Clin Proc* 72:400-413, 1997
- 12) Nosik WA. Intracranial hypotension secondary to lumbar nerve sleeve tear. *J Am Med Assoc* 157:1110-1111, 1955
- 13) Paldino M, Mogilner AY, Tenner MS. Intracranial hypotension syndrome: a comprehensive review. *Neurosurg Focus* 15:ECP2, 2003
- 14) Raskin NH. Lumbar puncture headache: a review. *Headache* 30:197-200, 1990
- 15) Schievink WI, Meyer FB, Atkinson JL, Mokri B. Spontaneous spinal cerebrospinal fluid leaks and intracranial hypotension. *J Neurosurg* 84:598-605, 1996
- 16) Vos PE, de Boer WA, Wurzer JA, van Gijn J. Subdural hematoma after lumbar puncture: two case reports and review of the literature. *Clin Neurol Neurosurg* 93:127-132, 1991