

Technical Note

Usefulness of an Additional Mattress Suture for the Extracranial Drainage Catheter

Dong Woong Eom, M.D., Jung Soo Kim, M.D., Kyoung Dong Jeon, M.D., Hoon Kim, M.D., Byeong Sam Choi, M.D.

Department of Neurosurgery, Haeundae Paik Hospital, Inje University College of Medicine, Busan, Korea

In most intracranial surgery cases, a drain catheter is inserted to prevent the collection of the wound hematoma or seroma. A drain catheter is also inserted to drain the hematoma or the cerebrospinal fluid. The drain catheter itself does not cause complications; but many complications occur during its removal, such as hematoma, seroma, air collection and pseudomeningocele formation. To prevent these complications, neurosurgeons perform a suture on the catheter to remove the site. In this study, an additional horizontal mattress suture and an anchoring suture to the drainage catheter are proposed. This method maintains negative pressure in the catheter insertion site during the catheter removal, compresses the catheter tunnel site and attaches the external wounds strongly. The technique is easy and safe to perform, and does not require an additional suture to remove the catheter.

Key Words : Mattress suture · Intracranial surgery · Catheters.

INTRODUCTION

In most intracranial surgery cases, a drain catheter is inserted to prevent the collection of the wound hematoma or seroma. Post-operative intracranial hematoma is a serious problem in the area of neurosurgery. Ideally, post-operative hematoma can be prevented by meticulous hemostasis during the procedure, but this is not always the case. The use of a post-operative drainage device in wounds before the closure of which hemostasis was difficult to achieve can reduce the incidence of post-operative hematoma.^{7,10)} A drainage catheter also sustains negative pressure on the wound and eliminates dead spaces that will help promote wound healing. It is also inserted to drain the hematoma or cerebrospinal fluid.

The drain catheter, itself does not cause complications. However, accidental traumatic removal of the drains bears very limited risk of subsequent intracranial hemorrhage. The other complications occur after removal and incomplete suture of the skin, such as cerebrospinal fluid leakage, air collection in the subdural space and ventricular space. To prevent these complications, neurosurgeons perform a suture on the catheter removal site.

In this study, an additional horizontal mattress suture was

performed, which can be used to anchor the catheter and fasten the catheter removal site.

MATERIALS

An additional mattress suture has been performed in nearly all patients who had undergone intracranial surgery with placement of a catheter since September 2011 to June 2012. Of these periods, poor initial mentality and severe trauma patients were excluded for that the patients can not feel pain. Routine elective surgery, some alert mentality trauma and subarachnoid patients were good candidate.

TECHNICAL METHOD

The first applied suture was the anchoring suture. The distal end of the catheter exited the skin at least 2 cm from the original incision. The exact tunneling distance was not controlled from patient to patient (Fig. 1A). The exiting distal catheter was anchored to the skin at its point of exit on the skin, with a 2-0 Mer-silk suture (Fig. 1B, C).

An additional mattress suture was performed for the skin su-

• Received : July 3, 2013 • Revised : September 17, 2013 • Accepted : September 30, 2013

• Address for reprints : Jung Soo Kim, M.D.

Department of Neurosurgery, Haeundae Paik Hospital, Inje University College of Medicine, 875 Haeun-daero, Haeundae-gu, Busan 612-862, Korea
Tel : +82-51-797-0628, Fax : +82-51-787-0841, E-mail : jheaj@hanmail.net

• This is an Open Access article distributed under the terms of the Creative Commons Attribution Non-Commercial License (<http://creativecommons.org/licenses/by-nc/3.0>) which permits unrestricted non-commercial use, distribution, and reproduction in any medium, provided the original work is properly cited.

ture during the removal of the catheter, using a 30 cm-long or longer 2-0 Mer-silk. The second stitch was sutured along the catheter approximately 0.5 cm away from proximal side to the distal side, perpendicular to the first suture and horizontal to the drainage catheter (Fig. 2A). The stitch was again sutured 0.5 cm away from the other side, but now from the distal side to the proximal side (Fig. 2B). The second suture was completed with two sutures that were vertical to the drainage catheter and horizontal to the first suture (Fig. 2C). The remaining silk was wrapped around the drainage catheter outside the skin and fixed using mosquito forceps. Finally, a clean dressing was applied to the incision site and the catheter exit site. The patient was not administered additional antibiotics except routine post-operative doses. The stitch with the drainage catheter was dressed everyday from the second post-operative day and was maintained

for 2-14 days.

When the drainage catheter had to be removed, the second stitch, which was wrapped around the drainage catheter, was untied, the first anchoring suture on the skin was cut (Fig. 3A, B). Then the assistant drew the drainage catheter that was connected to the first stitch, At the same time, the operator tied the second suture (Fig. 3D, E). Then, the drainage tube was removed, and simultaneously, the suture was done. The second mattress suture was removed one week after the drainage catheter was removed.

RESULTS

Additional mattress suture has been performed in nearly all patients who had undergone intracranial surgery with place-

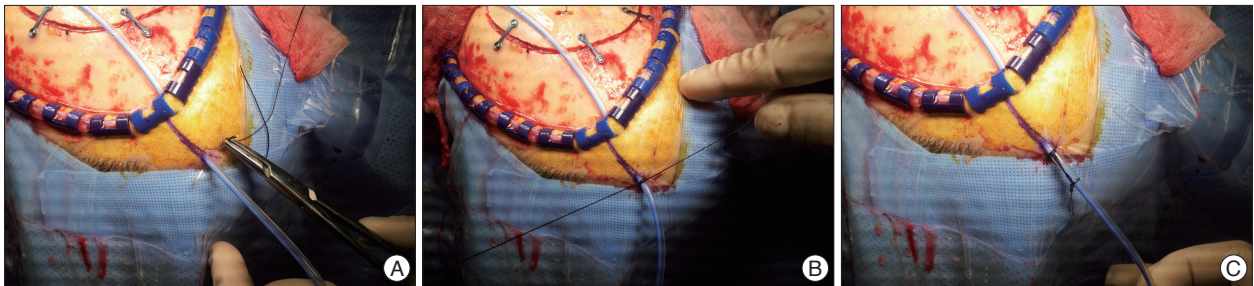


Fig. 1. First suture for the anchoring suture. A : The distal end of the catheter exited the skin at least 2 cm from the original incision. B and C : The exiting distal catheter is anchored to the skin at its point of exit on the skin with a 2-0 Mer-silk suture.

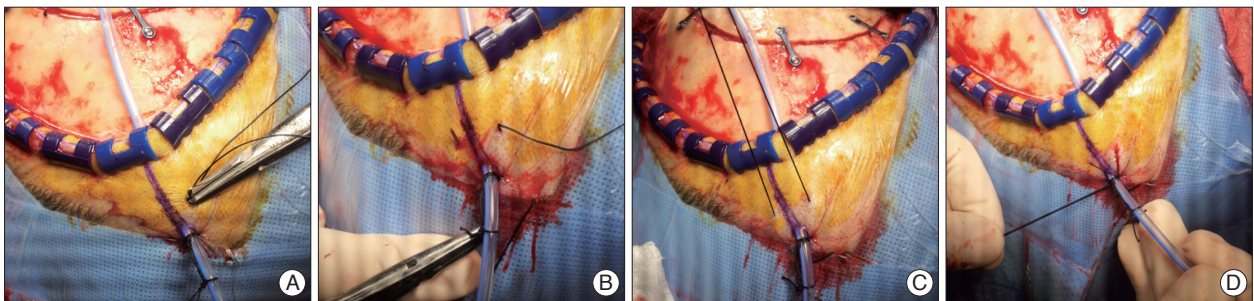


Fig. 2. Additional mattress suture using a 30 cm-long or longer 2-0 Mer-silk. A : The second stitch is sutured along the catheter, approximately 0.5 cm away from the proximal side to the distal side, perpendicular to the first suture and horizontal to the drainage catheter. B : The stitch is again sutured 0.5 cm away from the other side, but now from the distal side to the proximal side. C : The second suture is completed with two sutures that were vertical to the drainage catheter and horizontal to the first suture. D : The remaining silk is wrapped around the drainage catheter outside the skin and fixed using mosquito forceps.

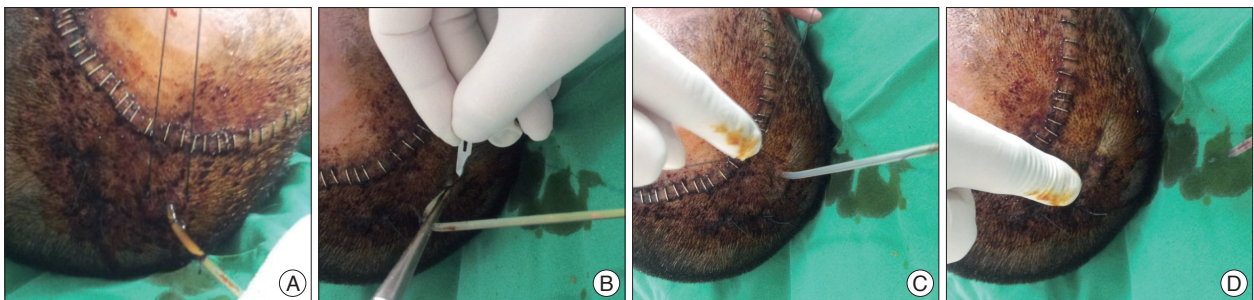


Fig. 3. Tie for the removal of the drainage catheter. A and B : The second stitch, which is wrapped around the drainage catheter, was untied, and the first anchoring suture on the skin was cut. C and D : Then the assistant drew the drainage catheter that is connected to the first stitch, at the same time, the operator tied the second suture.

Table 1. Characteristics of the additional mattress suture group (September 2011 to June 2012)

	Chronic SDH	Traumatic SDH, EDH	Skull defect	SAH	ICH	Tumor	EVD
Number of patients	18	14	4	41	9	37	10
Age (years)*	70.3±10.13 (50-83)	36.35±24.70 (1-84)	45.5±21.06 (14-58)	54.5±13.51 (30-72)	57.77±13.90 (36-76)	53.64±13.18 (17-81)	50.2±15.49 (25-72)
Durations (days)*	2.6±0.57 (1-3)	2.42±0.51 (2-3)	2.25±0.5 (2-3)	2.58±0.63 (0-3)	4±1.87 (3-7)	2.62±0.36 (2-4)	8.3±3.12 (5-14)
Sex ratio (M : F)	14 : 4	9 : 5	4 : 0	20 : 21	4 : 5	19 : 18	6 : 4

*Values are reported as the mean±standard deviation(range). SDH : subdural hematoma, EDH : epidural hematoma, SAH : subarachnoid hemorrhage, ICH : intracerebral hemorrhage, EVD : extraventricular drainage

ment of a catheter since September 2011 to June 2012 (Table 1). The suture's maintenance period was 2-15 days, 2-5 days for the epidural and subgaleal catheter; 2-7 days for the subdural catheter in the chronic subdural hemorrhage with burr hole drainage; 3-7 days for the intracerebral catheter in the hypertensive intracerebral hemorrhage with stereotaxic and craniotomy hematoma evacuation; 7-15 days for the extraventricular drainage in the subarachnoid hemorrhage. Complications such as infection and skin necrosis were not reported after the additional sutures during that period. The patient felt pain when his skin was drawn while the mattress suture was being tied. The stitch itself did not induce pain.

DISCUSSION

Post-operative intracranial hematoma is a serious problem in the area of neurosurgery. It can be prevented by meticulous hemostasis during the procedure, but this is not always the case. The development of hemostasis methods such as bone waxing, bipolar electrocautery, the use of surgical glue and hemostatic materials, and dural tenting sutures have reduced hemorrhagic complications after intracranial operations. Still, post-operative epidural hemorrhagic complications have been reported in about 0.26-2.3% of cases^{1,2,9)}. To reduce these complications, drainage catheters have been used in many neurological surgeries. The catheter is commonly placed in the subgaleal, epidural or subdural spaces to prevent the collection of post-operative hematoma or seroma.

In the case of intracerebral hemorrhage (ICH), the aim of operative treatment should be the removal of as much of the clot as possible, with minimal disruption of the surrounding brain tissue, to reduce the intracranial pressure (ICP) and to preserve the cerebrospinal fluid (CSF) flow. The drainage catheter is inserted in the intracranial hematoma not only to drain the remaining blood but also to administer the fibrinolysis agent⁵⁾. The drainage catheter is inserted in the subdural space to drain the chronic subdural hemorrhage and the post-operative air^{4,11)}.

The placement of an extraventricular drainage (EVD) for various conditions, such as traumatic brain injury (TBI), subarachnoid hemorrhage (SAH) and acute hydrocephalus, has been increasing in the last decade⁸⁾.

The drain catheter itself does not cause complications. It is known to have a relatively high risk of infection. The longer it is used, the greater is the risk of infection. There has been little research on subgaleal and epidural drainage that cites the infection rate, but the infection rate of EVD catheters has been cited in literature as ranging from 0% to 45%⁶⁾ and to have increased with the duration of the EVD maintenance and the number of EVD manipulations. This issue remains controversial.

Many complications such as subsequent intracranial hemorrhage occurs accidental traumatic removal of the drains. It can be prevented using meticulous drain remove. Other complications occur after removal and incomplete suture of the skin, such as cerebrospinal fluid leakage. The air collection in the subdural space and ventricular space is occurred by the pressure difference between in the cranial space and external cranial catheter's hydrostatic gravity. That pressure difference is caused by movement of cerebrospinal fluid generated by patient's position change³⁾. To prevent these complications, neurosurgeons perform suture on the catheter removal site. Many thoracic surgeons insert a chest tube and fix it with an anchoring suture and an additional mattress suture to close the skin. An additional mattress suture prevents pneumothorax, which may occur during chest tube removal. In this study, an additional mattress suture was performed in a case of brain surgery. The authors believe that an additional horizontal mattress suture has the following advantages in anchoring the drainage catheter. 1) It maintains negative pressure in the catheter insertion site during the catheter removal, compresses the catheter tunnel site and attaches the external wounds strongly. 2) It reduces the patient's pain and does not require an additional suture during the catheter removal and the suture of an external scalp wound.

CONCLUSION

If there is need for suture for the catheter removal site, intra-operative additional mattress suture to anchor the drain catheter is recommended.

Acknowledgements

This work was supported by the 2013 Inje University research grant.

References

1. Cabantog AM, Bernstein M : Complications of first craniotomy for intra-axial brain tumour. *Can J Neurol Sci* 21 : 213-218, 1994
2. Fukamachi A, Koizumi H, Nagaseki Y, Nukui H : Postoperative extradural hematomas : computed tomographic survey of 1105 intracranial operations. *Neurosurgery* 19 : 589-593, 1986
3. Kadowaki C, Hara M, Numoto M, Takeuchi K, Saito I : CSF shunt physics : factors influencing inshunt CSF flow. *Childs Nerv Syst* 11 : 203-206, 1995
4. Lavano A, Benvenuti D, Volpentesta G, Donato G, Marotta R, Zappia M, et al. : Symptomatic tension pneumocephalus after evacuation of chronic subdural haematoma : report of seven cases. *Clin Neurol Neurosurg* 92 : 35-41, 1990
5. Liu L, Shen H, Zhang F, Wang JH, Sun T, Lin ZG : Stereotactic aspiration and thrombolysis of spontaneous intracerebellar hemorrhage. *Chin Med J (Engl)* 124 : 1610-1615, 2011
6. Lozier AP, Sciacca RR, Romagnoli MF, Connolly ES Jr : Ventriculostomy-related infections : a critical review of the literature. *Neurosurgery* 51 : 170-181; discussion 181-182, 2002
7. Meguro T, Terada K, Hirotsune N, Nishino S, Asano T : Postoperative extradural hematoma after removal of a subgaleal drainage catheter--case report. *Neurol Med Chir (Tokyo)* 47 : 314-316, 2007
8. Park YG, Woo HJ, Kim E, Park J : Accuracy and safety of bedside external ventricular drain placement at two different cranial sites : Kocher's Point versus Forehead. *J Korean Neurosurg Soc* 50 : 317-321, 2011
9. Winston KR : Dural tenting sutures in pediatric neurosurgery. *Pediatr Neurosurg* 28 : 230-235, 1998
10. Winston KR : Efficacy of dural tenting sutures. *J Neurosurg* 91 : 180-184, 1999
11. Yu GJ, Han CZ, Zhang M, Zhuang HT, Jiang YG : Prolonged drainage reduces the recurrence of chronic subdural hematoma. *Br J Neurosurg* 23 : 606-611, 2009