

Clinical Article

Comparison between Lateral Supraorbital Approach and Pterional Approach in the Surgical Treatment of Unruptured Intracranial Aneurysms

Ki-Chul Cha, M.D., Seung-Chyul Hong, M.D., Ph.D., Jong-Soo Kim, M.D., Ph.D.

Department of Neurosurgery, Samsung Medical Center, Sungkyunkwan University School of Medicine, Seoul, Korea

Objective : The lateral supraorbital (LSO) approach is a modified method of the classic pterional approach and it has advantages of short skin incision and small craniotomy compared with the pterional approach. This study was designed to compare the two approaches in the surgical treatment of unruptured intracranial aneurysms.

Methods : We retrospectively reviewed 122 patients with 137 unruptured intracranial aneurysms treated by clipping, from July 2009 to April 2011. Between August 2010 and April 2011, 61 patients were treated by clipping via the lateral supraorbital approach and the same number of patients treated by clipping via the pterional approach were retrospectively enrolled. We analyzed the two groups and compared demographic, radiologic and clinical variables.

Results : The mean age of patients in the two groups was 54.6 years (LSO group) and 55.7 years (Pterion group). The mean duration of hospitalization was shorter in the LSO group than in the Pterion group (7.9 days vs. 9.0 days, $p=0.125$) and the mean operation time was also significantly shorter in the LSO group (117.1 minutes vs. 164.3 minutes, $p<0.001$). Furthermore, the mean craniotomy area was much smaller in the LSO group (1275.4 mm² vs. 2858.9 mm², $p<0.001$). The two groups showed similar distributions of aneurysm location and postoperative complications.

Conclusion : The lateral supraorbital approach for the clipping of unruptured intracranial aneurysm could be a good alternative to the classic pterional approach.

Key Words : Supraorbital approach · Pterional approach · Aneurysm · Clipping.

INTRODUCTION

Since it has been introduced by Yasargil in the 1970s¹⁾, the pterional or the fronto-temporo-sphenoidal approach has been widely used to approach lesions of the sellar or suprasellar region, Circle of Willis and Sylvian fissure.

Although the standard pterional approach has been accepted as a safe and appropriate method for various intracranial lesions, several modified approaches, such as the supraorbital eyebrow incision approach⁹⁾, the mini-pterial approach¹⁾, the mini-supraorbital approach²⁾, and the lateral supraorbital approach³⁾, have been recently introduced and used as an alternative for the purpose of reduction in brain exposure to the non-physiological surroundings, such as room air, irrigation media, and accidental surgical trauma.

The lateral supraorbital approach was proposed for operation on intracranial lesions located not only in the sellar and suprasellar regions, but also in the Sylvian fissure and retro-sellar regions³⁾. This modified approach requires much shorter skin incision and much smaller craniotomy than the standard pterional approach. Furthermore, it causes less trauma to the temporalis muscle and no injury to the upper branch of the facial nerve.

This study aimed to compare the lateral supraorbital approach with the pterional approach in the surgical treatment of unruptured aneurysms in the anterior circulation.

MATERIALS AND METHODS

Enrolled patients

Between August 2010 and April 2011, we clipped 86 intracra-

• Received : September 26, 2011 • Revised : November 21, 2011 • Accepted : January 25, 2012

• Address for reprints : Ki-Chul Cha, M.D.

Department of Neurosurgery, Samsung Medical Center, Sungkyunkwan University School of Medicine, 50 Irwon-dong, Gangnam-gu, Seoul 135-710, Korea
Tel : +82-2-3410-0243, Fax : +82-2-3410-0048, E-mail : nsdrckc@naver.com

• This is an Open Access article distributed under the terms of the Creative Commons Attribution Non-Commercial License (<http://creativecommons.org/licenses/by-nc/3.0>) which permits unrestricted non-commercial use, distribution, and reproduction in any medium, provided the original work is properly cited.

nial aneurysms of the anterior circulation. Among them, 68 aneurysms in 61 patients were clipped via the lateral supraorbital (LSO) approach were enrolled as the LSO group. Then, we enrolled the same number of patients ($n=61$) with 69 aneurysms clipped via the pterional approach between July 2009 and May 2010 as the Pterional group. In both groups, all operations with two different approach methods were performed by a single surgeon, at a single institute, over 2-year period. All distal ICA aneurysms were clipped without removal of the anterior clinoid process. Patients with ruptured aneurysms or multiple aneurysms of more than 3 were excluded from this study. Aneurysms treated by wrapping with cotton were also excluded. All data in the present study were based on the medical records and radiologic findings of the patients. We analyzed the two groups and compared demographic, radiologic and clinical variables, including age, sex, duration of hospitalization, operation time, craniotomy size, aneurysm location, and postoperative complications. The statistical significance of observed differences between the variables was assessed by the Student's *t*-test and the chi-square test.

Operative technique

The lateral supraorbital approach conducted in the present study was described in detail by Hernesniemi et al.³⁾ The patient was placed in the supine position, with the head slightly elevated above the cardiac level. The head is fixed with three pins in the Mayfield head frame and was rotated about 30 degrees towards the opposite side and tilted slightly depending on the precise location of the aneurysm. Hair shaving was minimal

but still allowing a large enough curvilinear frontotemporal skin incision. The skin incision was usually behind the hair line and did not descend in front of the ear to the level of the zygomatic arch (Fig. 1A). The one layer skin-galea-muscle flap was dislocated after detachment from the bone by periosteal elevator and diathermy, thus avoiding any injury of the branches of the facial nerve, and the flap was retracted anteriorly with spring hooks, until the superior orbital rim and the anterior zygomatic arch were exposed. The temporalis muscle was split only in its superior and anterior part (Fig. 1B). Only one burr hole was made posteriorly, just below the insertion line of the temporalis muscle. The bone flap was detached mainly by side-cutting craniotome, but the basal part was drilled off before lifting the flap (Fig. 1C). The bone flap size was about 3×4 cm (Fig. 1D). The dura mater was opened in a curvilinear incision pointing anterolaterally and elevated with stitches (Fig. 1E). The microscope was brought in place. After minimally opening the Sylvian fissure, the dissection was made toward the aneurysm site. Only one spatula was used on the frontal lobe for brain dislocation. After aneurysm clipping, the bone flap was secured using one skull fixator and two plate and screw systems (Fig. 1F).

RESULTS

Thirteen of the 122 patients (6 from the LSO group and 7 from the Pterional group) had two aneurysms simultaneously at different locations, and they were treated via a single surgical approach. Therefore, they were counted as a single case. Two of the 122 patients (one from the LSO group and the other from

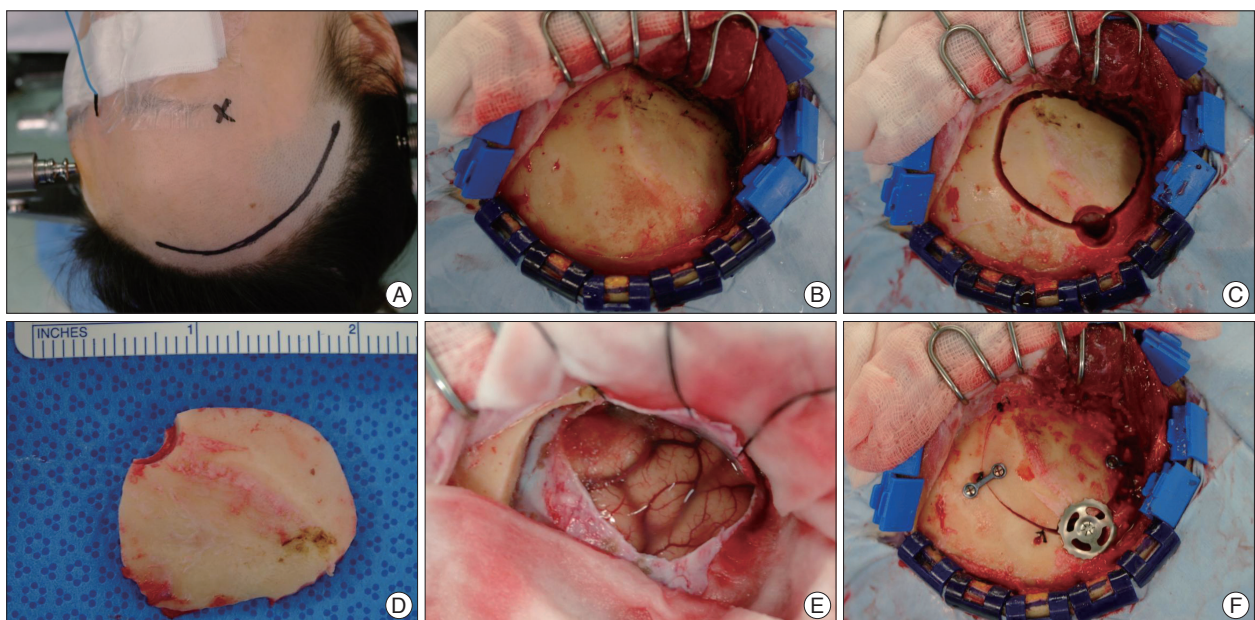


Fig. 1. The skin incision is usually behind the hair line and did not even go down in front of the ear to the level of zygomatic arch (A). The one layer skin-galea-muscle flap is dislocated after detachment from the bone by periosteal elevator and diathermy, and the flap is retracted anteriorly with spring hooks (B). Only one burr hole is made posteriorly and the bone flap is detached mainly by side-cutting craniotome with the basal part drilled off before lifting the flap (C). The bone flap size is about 3×4 cm (D). The dura mater is opened in a curvilinear incision pointing anterolaterally and elevated with stitches (E). After aneurysm clipping, the bone flap is secured using one skull fixator and two plate and screw systems (F).

the Pterional group) had mirror aneurysms at both MCA bifurcations, and they were clipped consecutively under a single general anesthesia. They were counted as two different cases because they had craniotomies on both sides. One of 61 patients of the LSO group had re-operation after surgical treatment for the anterior communicating artery (ACA) aneurysm, because a residual sac was detected at the postoperative radiologic evaluation. All aneurysms, except this one, were clipped successfully.

Seventy-one patients were female. The mean age was 55.3 years. Clinical data were presented in Table 1. Operation time was estimated from the moment of skin incision to that of skin closure. Craniotomy size was calculated by the equation, $\{(long\ axis\ diameter + short\ axis\ diameter) / 2\}^2 \times 3.14$, and the axis diameters were obtained from postoperative computed tomography (CT) images. The two groups showed similar distributions of aneurysm location and the anterior communicating artery and MCA bifurcation were the major aneurysm locations found in both groups (60.3% in the LSO group and, 73.9% in the Pterional group).

The number of patients with gyrus rectus partially removed in each group was 11 out of 16 in the LSO group and 14 out of 20 in the Pterional group. In the LSO group, the mean operation time of the patients with gyrus rectus removed was 116.2 minutes, which was shorter than (129.0 minutes) in the patients with gy-

rus rectus preserved. In contrast, in the Pterional group, the mean operation time of the patients with gyrus rectus removed (194.5 minutes) was longer than in patients with gyrus rectus preserved.

Several complications were noted postoperatively (Table 2), with low incidence of postoperative complications in both groups and no significant difference between the groups.

DISCUSSION

Not only the improvement of operating microscopes and refined instrumentation but also the development of diagnostic imaging tools focusing on certain intracranial lesions currently allows minimal invasive surgery for the treatment of intracranial aneurysms, instead of the conventional pterional approach, which requires relatively extensive skin, bone, and brain exposure⁶. Most keyhole approaches, such as the frontolateral, frontolateralobasal, supraorbital and transorbital keyholes, can provide access to various pathologies in the suprasellar and parasellar regions; however, they have limited working angle, which makes it difficult for the surgeon to manipulate and observe the lesions^{4,8}.

The lateral supraorbital approach was introduced by Hernesniemi and is a modified version of the classic pterional approach. When compared with the pterional approach, the lateral supra-

orbital approach provides more anterior trajectory, and consequently offers lesser exposure of the origin of the posterior communicating artery and the anterior choroidal artery. Because the origin of posterior communicating artery arises from the posteromedial surface of internal carotid artery and the anterior choroidal artery makes a medial curve initially, the pterional approach with more lateral trajectory has advantage in surgical clipping of these distal internal carotid artery aneurysms. In this study, these aneurysms were successfully clipped via lateral supraorbital approach with no additional difficulties, comparing with clipping via pterional approach. When the origins of these arteries were not identified, the patency of these arteries after clipping was confirmed by both intraoperative Doppler sonography and indocyanine green fluorescence angiography, and motor function of the patient was checked using motor evoked potential (MEP) monitoring device during operation. When specific surgical approach is selected, the decision-making process must be considered various factors such as surgeon's

Table 1. Clinical data of patients

Variables	LSO group (No. of patients)	Pterional group (No. of patients)	p value
Sex (F/M)	33/28	37/24	
Age (mean years)	54.6	55.7	0.576
Duration of hosp. (mean days)	7.9	9.0	0.125
Operation time (mean minutes)	117.1	164.3	<0.001
Craniotomy size (mean mm ²)	1275.4	2858.9	<0.001
Location			
Acom	16 (*11)	20 (*14)	
MCA bif.	25	31	
Pcom	8	7	
AChA	8	4	
ICA bif.	3	2	
Oph. Seg.	1	0	
M1	4	3	
A1	3	2	

*The number of patients whose gyrus rectus were partially removed. LSO : lateral supraorbital, hosp. : hospitalization, Acom : anterior communicating artery, bif. : bifurcation, Pcom : posterior communicating artery, Oph. Seg. : ophthalmic segment of internal carotid artery, M1 : the first segment of MCA, A1 : the first segment of ACA

Table 2. Postoperative complications

Complication	LSO group (No. of patients)	Pterional group (No. of patients)
Epidural hematoma	2	2
Intracerebral hematoma	1	0
Subdural hematoma	1	0
Infarction	0	1

LSO : lateral supraorbital

experience, anatomic consideration of the aneurysm, and the status of the aneurysm (ruptured or unruptured). Low-lying, broad-neck, and ruptured distal internal carotid artery aneurysm may be obliterated more safely by pterional approach.

The lateral supraorbital approach provides a longer route to the basilar tip and a lesser exposure volume, and consequently needs more frontal lobe retraction before reaching the chiasmatic and carotid cisterns⁷⁾. However, in the lateral supraorbital approach, the temporal muscle splitting is limited to its superior and anterior part, because the small skin incision never descends in front of the ear to the level of the zygomatic arch; thus, any injury of the upper branches of the facial nerve can be avoided by detaching the one layer skin-galea-muscle flap from the bone. Temporalis muscle atrophy caused by denervation, loss of blood supply or inappropriate muscle tension, may be serious cosmetic and functional complications⁹⁾. Furthermore, the small craniotomy made with only one burr hole in the LSO approach can shorten the overall operation time and reduce craniotomy-related complications, such as CSF leak, postoperative epidural hematoma and infection; the size of craniotomy, of course, is sufficient to reach the whole anterior part of the Circle of Willis, sellar, and suprasellar region³⁾.

In this study, the operation time in the LSO approach was significantly shorter than that of the pterional approach. For the pterional approach, the long and downward extending skin incision, more splitting of the temporalis muscle, large craniotomy with several burr holes and drilling of the sphenoid ridge could increase both operation time and surgical morbidity^{3,10)}.

The limitation of this study is that we did not focus on the postoperative cosmetic and functional results, such as chewing discomfort, temporal muscle atrophy and hyposmia, which may influence the quality of life of our patients.

CONCLUSION

In our experience, the lateral supraorbital approach provides adequate exposure of the lesion and allows safe neurosurgical

manipulation, with much shorter operation time and much smaller craniotomy, thereby decreasing surgical morbidity. Thus, the lateral supraorbital approach for clipping of unruptured intracranial aneurysm could be a good alternative to the classic pterional approach.

References

1. Figueiredo EG, Deshmukh P, Nakaji P, Crusius MU, Crawford N, Spetzler RF, et al. : The minipterional craniotomy : technical description and anatomic assessment. *Neurosurgery* 61 : 256-264; discussion 264-265, 2007
2. Figueiredo EG, Deshmukh V, Nakaji P, Deshmukh P, Crusius MU, Crawford N, et al. : An anatomical evaluation of the mini-supraorbital approach and comparison with standard craniotomies. *Neurosurgery* 59 : ONS212- ONS220; discussion ONS220, 2006
3. Hernesniemi J, Ishii K, Niemelä M, Smrcka M, Kivipelto L, Fujiki M, et al. : Lateral supraorbital approach as an alternative to the classical pterional approach. *Acta Neurochir Suppl* 94 : 17-21, 2005
4. Mori K, Yamamoto T, Nakao Y, Oyama K, Esaki T, Watanabe M, et al. : Lateral supraorbital keyhole approach to clip unruptured anterior communicating artery aneurysms. *Minim Invasive Neurosurg* 51 : 292-297, 2008
5. Oikawa S, Mizuno M, Muraoka S, Kobayashi S : Retrograde dissection of the temporalis muscle preventing muscle atrophy for pterional craniotomy. Technical note. *J Neurosurg* 84 : 297-299, 1996
6. Park JC, Hamm IS : Cortical osteotomy technique for mobilizing the temporal muscle in pterional craniotomies. Technical note. *J Neurosurg* 102 : 174-178, 2005
7. Salma A, Alkandari A, Sammet S, Ammirati M : Lateral supraorbital approach versus pterional approach : an anatomical qualitative and quantitative evaluation. *Neurosurgery* 68 : ONS364- ONS372, 2011
8. Steiger HJ, Schmid-Elsaesser R, Stummer W, Uhl E : Transorbital keyhole approach to anterior communicating artery aneurysms. *Neurosurgery* 48 : 347-351; discussion 351-352, 2001
9. van Lindert E, Perneczky A, Fries G, Pierangeli E : The supraorbital keyhole approach to supratentorial aneurysms : concept and technique. *Surg Neurol* 49 : 481-489; discussion 489-490, 1998
10. Wen HT, de Oliveira E, Tedeschi H, Andrade FC, Rhoton AL : The pterional approach : surgical anatomy, operative technique, and rationale. *Oper Tech Neurosurg* 4 : 60-72, 2001
11. Yasargil MG, Fox JL : The microsurgical approach to intracranial aneurysms. *Surg Neurol* 3 : 7-14, 1975