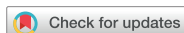

## Editorial



# Dupuytren's Disease: the Vikings Disease in Koreans

Hyun Sik Gong

Department of Orthopedic Surgery, Seoul National University Bundang Hospital, Seongnam, Korea

## OPEN ACCESS

**Received:** Jun 4, 2018

**Accepted:** Jun 4, 2018

### Address for Correspondence:

Hyun Sik Gong, MD

Department of Orthopedic Surgery, Seoul National University Bundang Hospital, 82 Gumi-ro 173-beon-gil, Bundang-gu, Seongnam 13620, Republic of Korea.  
E-mail: hsgong@snu.ac.kr

© 2018 The Korean Academy of Medical Sciences.

This is an Open Access article distributed under the terms of the Creative Commons Attribution Non-Commercial License (<https://creativecommons.org/licenses/by-nc/4.0/>) which permits unrestricted non-commercial use, distribution, and reproduction in any medium, provided the original work is properly cited.

### ORCID iDs

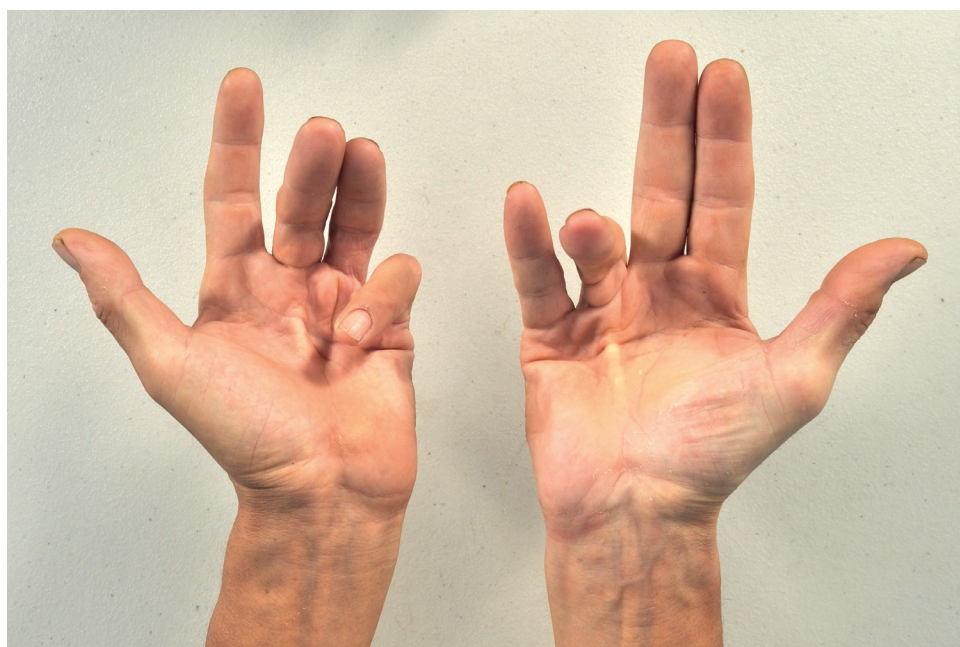
Hyun Sik Gong   
<https://orcid.org/0000-0003-4028-1559>

### Disclosure

The author has no potential conflicts of interest to disclose.

► See the article "The Epidemiology of Dupuytren's Disease in Korea: a Nationwide Population-based Study" in volume 33, e204.

Dupuytren's disease (DD, or Dupuytren's contracture) is a condition in which one or more fingers (usually ring or small fingers) become progressively bent in a flexed position due to a thick, abnormal fibrous nodule or cord formation in the palmar fascia of the hand (**Fig. 1**). The metacarpophalangeal joint is usually involved first and later the proximal interphalangeal joint. DD is usually painless and progresses insidiously. Patients with DD usually tolerate the contracture well and present for treatment when they start to poke themselves in the eye when washing their face. Sometimes patients are thankful to be reassured that they did not have cancer. While surgery can improve the contracture, recurrence of some degrees is quite often, about 30%–50% after 5 years.



**Fig. 1.** Dupuytren's disease in the long and small fingers of left right hand and in the ring finger of the right hand. The patient consented that his hand photograph would be published in a scientific article.

In 1831, Guillaume Dupuytren, a French surgeon, described the condition and thereafter it is identified by his name. His major contribution was the exact description of its anatomic etiology. At that time the disease was believed to be an inflammatory joint disease or even a cancer of the skin or the tendon sheath. Dupuytren had a chance of postmortem dissection on one of his patients with DD and he found what caused the deformity. He cut the tense, contracted palmar fascia and obtained full finger extension. He published his finding in *the Lancet* in 1834.<sup>1</sup> Dupuytren was an ambitious man who came from a poor family. He was granted the title of Baron by Louis XVIII. Due to his perfectionist character, some of his colleagues called him “the best of surgeons, the worst of men.”<sup>2</sup>

The disease existed long before the name was applied to it. It is said that DD originated with the Vikings, who spread it throughout Northern Europe as they traveled and intermarried.<sup>3</sup> The Vikings landed on the east coast of England in the 9th century and dominated the land for about 300 years. In 15th century Scotland, male bagpipers who could not play the pipes because of their finger contractures were said to have “the curse of the MacCrimmons (one of piping families).” In fact, about 30% of Norwegian men over 60 years old have DD. DD is often inherited as an autosomal dominant trait with varying degrees of expression. Although DD is much more common in those of northern European descent, it can occur in any race or heritage.

In the current issue of *Journal of Korean Medical Science*, Lee et al.<sup>4</sup> indeed showed that DD is no longer the disease confined to the Vikings' descendants. They investigated the epidemiology of DD in Korea using the big data provided by the Korean Health Insurance Review and Assessment Service. The mean annual prevalence was 32.2 per 100,000 population. Although the prevalence of DD in Korea was 100–1,000 times lower than in western countries, it was slightly higher than that in Taiwan. Considering that patients with mild DD usually do not present to physicians, the prevalence could have been underestimated in this study.

DD compromises the patients' hand function and quality of life. In 2010, an injectable enzyme, collagenase clostridium histolyticum that dissolves the collagen-rich cord was approved by the US Food and Drug Administration and is now available in many countries. Despite the similar recurrence rate, this injection treatment has demonstrated reliable outcomes with few complications and early recovery. In Korea, however, the enzyme is not available because of its high cost compared to the fee for open surgery, and because of the low marketability. The introduction of new medical technology requires us to consider its economic impact in the given health-care system.<sup>5</sup> The study by Lee et al.<sup>4</sup> has provided important epidemiologic data on DD in Koreans. Hopefully this study could be the basis for further research to evaluate the efficacy and the cost-effectiveness of various treatments for DD, ultimately benefiting the Korean patients for whom the disease is not common but not so rare.

## REFERENCES

1. Dupuytren G. Permanent retraction of the fingers produced by an affection of the palmar fascia. *Lancet* 1834;2:222-5.
2. Holzer LA, de Parades V, Holzer G. Guillaume Dupuytren: his life and surgical contributions. *J Hand Surg Am* 2013;38(10):1994-8.  
[PUBMED](#) | [CROSSREF](#)
3. Flatt AE. The Vikings and Baron Dupuytren's disease. *Proc Bayl Univ Med Cent* 2001;14(4):378-84.  
[PUBMED](#) | [CROSSREF](#)

4. Lee KH, Kim JH, Lee CH, Kim SJ, Jo YH, Lee M, et al. The epidemiology of Dupuytren's disease in Korea: a nationwide population-based study. *J Korean Med Sci* 2018;33(31):e204.  
[CROSSREF](#)
5. Baltzer H, Binhammer PA. Cost-effectiveness in the management of Dupuytren's contracture. A Canadian cost-utility analysis of current and future management strategies. *Bone Joint J* 2013;95-B(8):1094-100.  
[PUBMED](#) | [CROSSREF](#)