

# The Experience of Ligation of Transverse or Sigmoid Sinus in Surgery of Large Petroclival Meningiomas

The authors present the experience of ligation of transverse or sigmoid sinus in the surgical removal of petroclival meningiomas. We reviewed the medical records and venograms of 14 patients with petroclival meningiomas, in whom the intraoperative ligation of transverse or sigmoid sinus had been done at our hospital between 1986 and 1999. All patients passed the intraoperative test clamping of the sinus. The drainage pattern of confluence of Herophili was classified into four types: type A, confluence and equal drainage on both transverse sinuses; type B, confluence and non-dominant transverse sinus on the tumor side; type C, confluence and dominant transverse sinus on the tumor side; and type D, unilateral transverse sinus only. Among the 14 cases, four cases were in type A, five cases in type B, and two were type C. There was no evidence of brain swelling after intraoperative test clamping of the sinus for more than 30 min. None of the patients experienced postoperative complications related with sinus ligation. Our observation suggests that the transverse or sigmoid sinus ligation is tolerable to patients who show the drainage patterns of type A, type B, and type C, if the test clamping proves to be safe.

**Key Words :** *Meningioma; Transverse Sinus; Sigmoid Sinus*

**Sung-Kyun Hwang, Ho-Shin Gwak,  
Sun-Ha Paek, Dong Gyu Kim,  
Hee-Won Jung**

Department of Neurosurgery, College of Medicine  
Seoul National University and Clinical Research  
Institute, Seoul National University Hospital, Seoul,  
Korea

Received : 18 October 2001  
Accepted : 23 April 2002

## Address for correspondence

Hee-Won Jung, M.D.  
Department of Neurosurgery, College of Medicine,  
Seoul National University, 28 Yongon-dong,  
Chongno-gu, Seoul 110-744, Korea  
Tel : +82.2-760-2355, Fax : +82.2-744-8459  
E-mail : hwnjung@plaza.snu.ac.kr

## INTRODUCTION

During the past decades, marked advances have been made in the development of petrosal approach to petroclival meningiomas. Intimate to the application of the petrosal approach to petroclival meningiomas are the manipulation, management, and sacrifice of the transverse or sigmoid sinus. Petroclival meningioma often becomes very large before diagnosis due to its infrequency and insidious growth. Total resection of these large tumors sometimes needs ligation and resection of sinus for wide exposure of tumors. Some authors have stated that the transverse or sigmoid sinus should not be ligated due to venous complication (1). The technical difficulty of using the petrosal approach and the likelihood of encountering venous complications depend on the particular individual venous anatomy and its variations. In this study, we demonstrate the guideline for a safe ligation and resection of the sinus.

## MATERIALS AND METHODS

### Patients

We retrospectively recruited 14 patients whose transverse or sigmoid sinus had been ligated during operation from 60

cases diagnosed with petroclival meningiomas at Department of Neurosurgery, Seoul National University Hospital from 1986 to 1999. The mean age of the patients was 43 yr (range, 15-61), and the male-to-female ratio was 3:11. The mean tumor size was 48 mm in diameter (range 25-90), relatively large sized.

### Indication of sinus ligation

The size of tumors for sinus ligation was relatively large (>4 cm) extending infratentorial and supratentorial region. And, even if size of tumor was not large, tumors with hard consistency and high vascularity through preoperative a diagnosis, were also included. The exposure of these tumors was not enough for petrosal approach only with superior petrosal sinus. The approach by trans-transverse-sinus approach was performed by "Malis approach" in early 1980. However, this approach was not usually performed in recent days. In addition, the findings such as collateral vessel, type of vein of Labbé, and adjacent venous structure in venogram were also evaluated in all cases for risk of vascular catastrophe after ligation of sinus.

### Operative approach

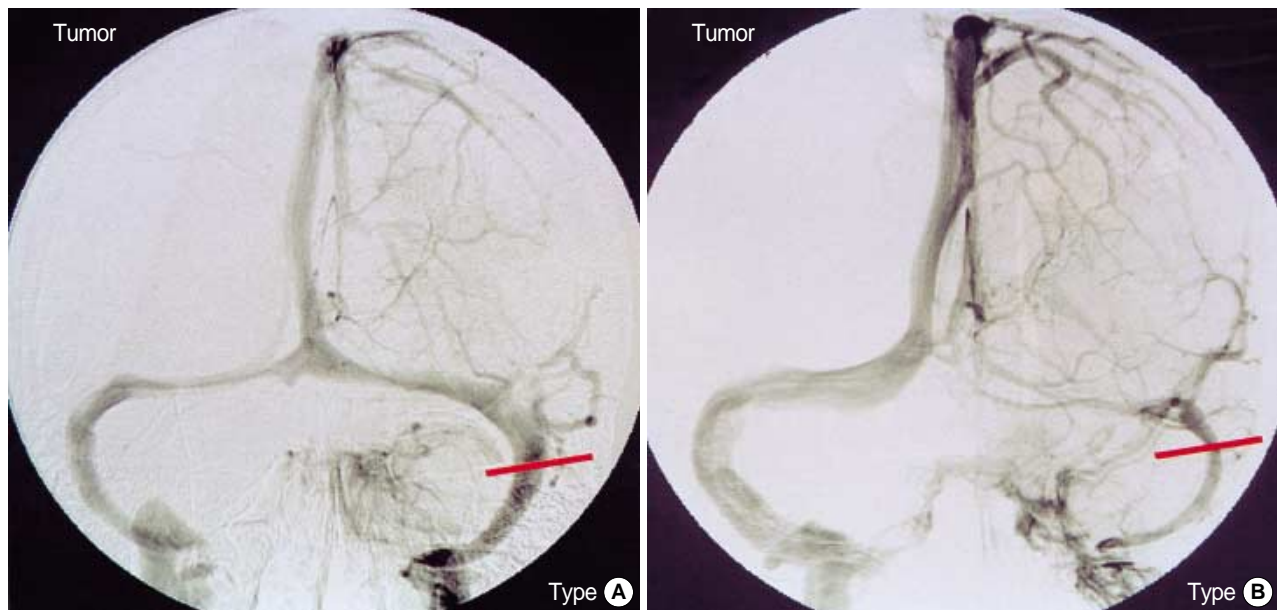Ligation of transverse or sigmoid sinus was done in 14 pa-

tients with the petroclival meningiomas, who underwent surgery from 1986 to 1999 (Table 1). Among them, reoperation was performed in one case due to recurrence of the tumor. Trans-sigmoid-sinus approach was done in three cases, and trans-transverse-sinus approach was done in eight cases. The sinus was ligated and resected during operation in all cases. Transpetrosal approaches were done by an otologist according to the extent of the mastoidectomy and petrosectomy. Three types of approach were used: retrolabyrinthine approach in three

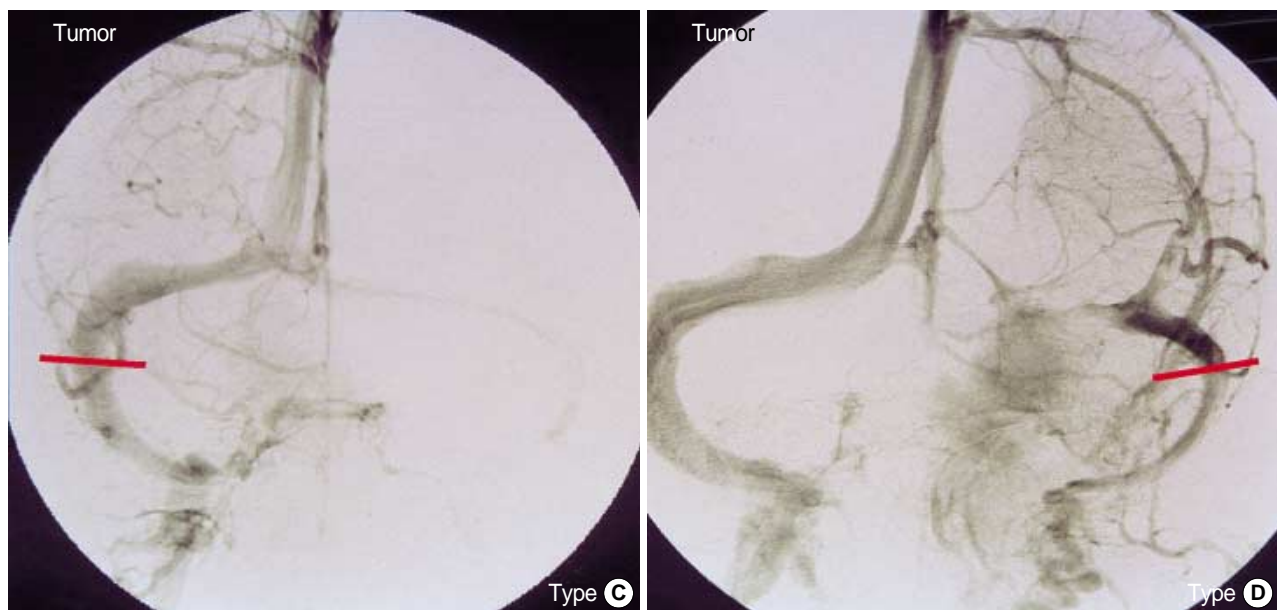
cases, translabyrinthine approach in nine, and transcochlear approach in two cases. Combined supratentorial-infratentorial approach was done in five cases and combined presigmoid and retrosigmoid approaches was done in nine cases.

#### Preoperative venogram findings

We analyzed the venogram of the 11 patients, and reviewed the location of the tumor and the drainage pattern of the con-



**Fig. 1.** Venograms demonstrating the types of confluents of Herophili. **Type A:** confluence on both transverse sinuses. **Type B:** confluence and non-dominant transverse sinus. Bar indicates the ligation of sinus.



**Fig. 2.** Venograms demonstrating the types of confluents of Herophili. **Type C:** confluence and dominant transverse sinus on the tumor side. **Type D:** unilateral transverse sinus only. Bar indicates the ligation of sinus.

fluens of Herophili. The drainage pattern of the confluens of Herophili is classified into four types: type A, confluence and equal drainage on both transverse sinuses; type B, confluence and non-dominant transverse sinus on the tumor side (Fig. 1); type C, confluence and dominant transverse sinus on the tumor side; and type D, unilateral transverse sinus only (Fig. 2). Type A represented with equal drainage pattern of transverse sinus at the confluens of Herophili, irrespective of the location of the tumor. Type B is the non-dominant drainage pattern of transverse sinus on the tumor side. Type C is the dominant drainage pattern of transverse sinus on the tumor side. And, type D is unilateral drainage only at the confluens of Herophili, that is, transverse sinus agenesis or hypogenesis. In addition, we reviewed the relationship between the type of variation and the safety of ligation and resection of sinus.

### Intraoperative test clamping

When we ligated sinus during operation, the transverse

**Table 1.** Summary of patients (N=14, 1986-1999)

Patients No.	Sex	Age (yr)	Approach	Sinus <sup>†</sup>	TCT (min)	Confluence Type
1*	F	50	ST-IT,TC	S	30	B
2	F	52	PS-RS,TL	S	45	A
3	F	36	PS-RS,RR	S	80	B
4	M	50	PS-RS,RR	S	60	B
5	F	15	PS-RS,RR	S	- <sup>§</sup>	B
6	M	38	PS-RS,TC	S	60	A
7	F	47	ST-IT,TL	T	30	B
8	F	61	PS-RS,TL	T	- <sup>§</sup>	C
9	F	44	ST-IT,TL	T	- <sup>§</sup>	B
10	F	49	PS-RS,TL	T	30	A
11	F	38	PS-RS,TL	T	- <sup>§</sup>	C
12 <sup>†</sup>	M	36	ST-IT,TL	T	- <sup>§</sup>	-
13 <sup>†</sup>	F	41	ST-IT,TL	T	- <sup>§</sup>	-
14 <sup>†</sup>	F	51	PS-RS,TL	T	- <sup>§</sup>	-

\*Reoperation. <sup>†</sup>Venography is not available. <sup>‡</sup>Ligated sinus. <sup>§</sup>Intraoperative test clamping time for seven cases was not available in medical records.

Abbreviations: F, female; M, male; ST-IT, supratentorial-infratentorial; PS-RS, presigmoid-retrosigmoid; TL, translabyrinth; RR, retrolabyrinth; TC, transcochlear; S, sigmoid; T, transverse; TCT, temporary clipping time.

**Table 2.** Communication at confluens of Herophili (N=14)

The drainage pattern of confluence of Herophili	No. of patients
Type A confluence and equal drainage on both transverse sinuses	4
Type B confluence and non-dominant transverse sinus on the tumor side	5
Type C confluence and dominant transverse sinus on the tumor side	2
Type D unilateral transverse sinus only	0

\*Three cases without venography were excluded.

sinus was ligated and cut proximally to the superior petrosal sinus and distally to the vein of Labbé in all cases. We performed test clamping with Yasargil temporary clip, measured test clamping time for at least 30 min and up to 80 min during sinus ligation, and then checked the intraoperative brain swelling. However, among them, intraoperative test clamping time for seven cases was not available in medical records.

## RESULTS

Table 2 shows the distribution of the drainage pattern of confluens of Herophili in the 14 study subjects. Four patients were type A, five patients were type B, and two were type C. Venogram was not available in three cases. The sigmoid sinus ligation and resection was done in six cases, all of which except one underwent intraoperative test clamping (Table 1). The mean clamping time was a 55 min (range, 30-80), and there was no evidence of brain swelling (Table 1). None of the six patients experienced postoperative complication related to sigmoid sinus ligation and resection. The transverse sinus ligation and resection was done in eight cases, two of which underwent intraoperative test clamping. The clamping time was 30 min for both cases, and none of the eight patients experienced postoperative complication related to sinus ligation and resection.

## DISCUSSION

Petroclival meningiomas are not frequently encountered, accounting for only 10% of intracranial meningiomas (1, 2). However, the meningiomas in this region pose a formidable challenge to skull base surgeons due to the restricted surgical exposure, difficult anatomy, and risk of injury to vital neurovascular structure, especially venous structures (3-7). Another significant factor influencing surgical outcome is the size of the tumors, since the tumors in this region may become very large, invading into multiple compartments before diagnosis. However, they have somewhat innocuous presenting features (1, 8, 9).

In 1905, Brochardt reported their experience of the division of sigmoid sinus to expose the cerebellopontine tumors (10). In 1915, Quix described the ligation of sigmoid sinus to gain additional access to large posterior fossa tumors (10). Similar approach was made by Marx in 1913 (10). At autopsy, the thrombus in transverse sinus was noted to extend medially from the point of ligature to the confluens of the venous sinus. In 1928, Naffziger mentioned a modified approach in which the supratentorial occipital craniotomy could be incorporated into a previous suboccipital craniectomy, with transverse sinus ligation for wide exposure (10). In 1980, Malis reported on his combined suboccipital subtemporal or petrosal approach with emphasis on the ligation of the transverse

sinus with preservation of the vein of Labbé blood flow via the opposite side (1, 11). Indication of ligation and resection of the transverse or sigmoid sinus has been controversial. The anatomy of the sigmoid and transverse sinuses varied considerably, often larger than normal, or even located more anteriorly (8). Some authors reported immediate or delayed complication up to 24–48 hr after the sinus ligation and resection, such as infarction and hemorrhage, even with the intraoperative monitoring system (10, 12). So, they had a negative opinion on the transverse and sigmoid sinus ligation. However, on the contrary, many authors' reached consensus on the indication of the safe ligation of sinus in the following situation (8, 10, 11, 13, 14).

1) The contralateral sinus was patent (1, 8, 14–16).

2) Given the equally patent sinus, the relative size of sinus was assessed by venogram or enhanced computed tomography. The side of the smaller-sized sinus was often ligated and resected (10, 13, 17, 18).

3) Preoperative balloon occlusion test or jugular vein compression test in carotid and vertebrae angiography was performed (9).

All of transverse sinus was ligated and cut proximally to the superior petrosal sinus, distally to the vein of Labbé in these series (8, 10, 11, 13, 14). The first two situations deliver same concept with classification of type of the drainage pattern of confluents of Herophili.

Intraoperative monitoring methods to prevent postoperative deficits were used in a variety of neurosurgical operations. Intraoperative brain stem evoked response (BAEP) and somatosensory evoked potential (SSEP) was used for resection of petroclival meningiomas. Bejjani et al. reported their experience with the use of intraoperative SSEP during surgery of cranial base tumors (19). They showed intraoperative SSEP had a high predictive value, however, the absence of SSEP changes would not exclude the possibility of the deficits. In addition, the return of SSEP to baseline predicted neurological recovery in 90% of the cases. They did not detect every postoperative deficits (19). Another method of intraoperative monitoring, as shown by Spetzler et al. (14), was to measure sigmoid sinus pressure after test clamping of sinus in order to assess the contralateral venous drainage before cutting the sinus. Intravascular pressure had not increased by more than 7 mmHg after sigmoid sinus ligation when its patency was demonstrated angiographically. The pressure rise by more than 10 mmHg in the sigmoid sinus revealed by temporary occlusion test indicates the intactness of the sinus. In their report on transsigmoid approach in basal tip aneurysms, Day et al. insisted that intravascular pressure not more than 5 mmHg by test clamping was safe during operation (20). However, this method did not reflect end result of vascular dynamics after sinus ligation, and intraoperative monitoring changes would not exclude the possibility of the postoperative deficits. On the contrary, the method of intraoperative test clamping was more liable, because of reflection of simu-

lative situation of sinus ligation. In our series, test clamping was done in five cases out of six cases sigmoid sinus ligation. The maximum clamping time was 80 min, and there was no evidence of the brain swelling during ligation. There was no postoperative complication related to the sigmoid sinus ligation. And, the test clamping was done in two out of eight cases with transverse sinus ligation. The clamping time was 30 min for both of them, there was no postoperative complication related to the sinus ligation. From these results, we concluded that sinus ligation after test clamping for at least 30 min, with no evidence of intraoperative brain swelling, is a reliable method.

When we need a wide operative field for large petroclival meningiomas, transverse or sigmoid sinus is often ligated. We found out that the drainage patterns of the confluents of Herophili of Type A, Type B, and Type C were tolerable to the sinus ligation, if the test clamping proved to be safe. And, we believed the identification of the brain swelling after intraoperative test clamping of sigmoid or transverse sinus for more than 30 min to be a reliable indicator for sinus ligation and resection in petroclival meningioma surgery.

## ACKNOWLEDGMENT

This work was partially supported by Seoul National University Hospital Grant and Korea Brain and Spinal Cord Research Foundation Grant. The authors are grateful to Miss Mi Sun Park for her assistance with the preparation of this manuscript.

## REFERENCES

1. Al-Mefty O, Fox JL, Smith RR. *Petrosal approach for petroclival meningiomas. Neurosurgery* 1988; 22: 510-7.
2. Couldwell WT, Fukushima T, Giannotta SL, Weiss MH. *Petroclival meningiomas: surgical experience in 109 cases. J Neurosurg* 1996; 84: 20-8.
3. Canalis RF, Black K, Martin N, Becker D. *Extended retrolabyrinthine transtentorial approach to petroclival lesions. Laryngoscope* 1991; 101: 6-13.
4. Miller CG, van Loveren HR, Keller JT, Pensak M, El-Kalliny M, Tew JM Jr. *Transpetrosal approach: surgical anatomy and technique. Neurosurgery* 1993; 33: 461-9.
5. Sakata K, Al-Mefty O, Yamamoto I. *Venous consideration in petrosal approach: microsurgical anatomy of the temporal bridging vein. Neurosurgery* 2000; 47: 153-60.
6. Sanna M, Mazzoni A, Saleh EA, Taibah AK, Russo A. *Lateral approaches to the median skull base through the petrous bone: the system of the modified transcochlear approach. J Laryngol Otol* 1994; 108: 1036-44.
7. Sekhar LN, Wright DC, Richardson R, Monacci W. *Petroclival and foramen magnum meningiomas: surgical approaches and pitfalls. J*

- Neurooncol* 1996; 29: 249-59.
8. Cantore G, Delfini R, Ciappetta P. *Surgical treatment of petroclival meningiomas: experience with 16 cases. Surg Neurol* 1994; 42: 105-11.
  9. Cass SP, Sekhar LN, Pomeranz S, Hirsch BE, Snyderman CH. *Excision of petroclival tumors by a total petrosectomy approach. Am J Otol* 1994; 15: 474-84.
  10. Megerian CA, Chiocca EA, McKenna MJ, Harsh GF 4th, Ojemann RG. *The subtemporal-transpetrous approach for excision of petroclival tumors. Am J Otol* 1996; 17: 773-9.
  11. Samii M, Tatagiba M. *Experience with 36 surgical cases of petroclival meningiomas. Acta Neurochir (Wien)* 1992; 118: 27-32.
  12. Mayberg MR, Symon L. *Meningiomas of the clivus and apical petrous bone. Report of 35 cases. J Neurosurg* 1986; 65: 160-7.
  13. Samii M, Ammirati M, Mahran A, Bini W, Sepehria A. *Surgery of petroclival meningiomas: report of 24 cases. Neurosurgery* 1989; 24: 12-7.
  14. Spetzler RF, Dashtip CP, Pappas CT. *The combined supra- and infratentorial approach for lesions of the petrous and clival regions: experience with 46 cases. J Neurosurg* 1992; 76: 588-99.
  15. Sekhar LN, Pomeranz S, Janecka IP, Hirsch B, Ramasastry S. *Temporal bone neoplasms: a report on 20 surgically treated cases. J Neurosurg* 1992; 76: 578-87.
  16. Tedeschi H, Rhoton AL Jr. *Lateral approaches to the petroclival region. Surg Neurol* 1994; 41: 180-216.
  17. Giannotta SL, Maceri DR. *Retrolabyrinthine transsigmoid approach to basilar trunk and vertebrobasilar artery junction aneurysms. Technical note. J Neurosurg* 1988; 69: 461-6.
  18. Sekhar LN, Jannetta PJ, Burkhart LE, Janosky JE. *Meningiomas involving the clivus: a six-year experience with 41 patients. Neurosurgery* 1990; 27: 764-81.
  19. Bejjani GK, Nora PC, Vera PL, Broemling L, Sekhar LN. *The predictive value of intraoperative somatosensory evoked potential monitoring: review of 244 procedures. Neurosurgery* 1998; 43: 491-500.
  20. Day JD, Fukushima T, Giannotta SL. *Cranial base approaches to posterior circulation aneurysms. J Neurosurg* 1997; 87: 544-54.