

## Total Hip Arthroplasty for Osteonecrosis of the Femoral Head Following Cardiac Transplantation - A Case Report -

Hyung-Won Kim, MD, Taek-Rim Yoon, MD, Yong-Jin Cho, MD

*Center for Joint Disease, Chonnam National University Hwasun Hospital, Jeonnam, Korea*

Cardiac transplantation has become the treatment of choice for end stage heart disease, and the long-term survival rates of cardiac transplant patients continue to improve, due to the continued improvements made in operation methods and postoperative immunological therapies. However, the incidences of disabling orthopedic complications, such as, osteopenia, osteoporosis, fractures, and osteonecrosis, have been increased by the postoperative administrations of steroids and immunosuppressive agents. Accordingly, several orthopedic surgeons have evaluated treatments for these complications, and a number of reports have been issued on osteonecrosis after cardiac transplantation. However, all of these reports have been issued in the US and European countries, and in particular, no report has been published on osteonecrosis following cardiac transplantation in an Asian patient. In this report, the authors report the case of a patient who underwent total hip arthroplasty due to osteonecrosis of the femoral head after cardiac transplantation.

**Key Words:** Cardiac transplantation, Osteonecrosis of femoral head, Total hip arthroplasty

Cardiac transplantation is the only therapy available for terminal heart failure, and was pioneered by Christian Barnard in the 1970's, who also conducted the first heart transplant in 1976, although unfortunately this patient expired 18 days after surgery<sup>1)</sup>. However, subsequently, many immunosuppressive agents and operation techniques were developed. In particular, the increased survival rates being achieved today can be attributed to a number of factors, such as, the refinement of medical and surgical techniques, better patient selection criteria, improved myocardial preservation, and the judicious use of cyclosporine, a

selective T-cell immunosuppressant. Today more than 2000 heart transplants are performed annually, and in 2008 Roussel et al. reported survival rates after 5, 10, and 15 year postop of 75, 58, and 42%, respectively<sup>2)</sup>. In the Republic of Korea, the first cardiac transplantation was performed at 1992, and in the 2008 the summed total number of cases performed stood at 434; 20~30 cases were performed annually until 2006 but this increased to 50 cases in 2007 and to 84 cases in 2008.

On the other hand, orthopaedic complications, such as osteopenia, osteoporosis, fractures, and osteonecrosis are also increasing in parallel with survival rates and the use of immunosuppressants. In particular, the incidence of osteonecrosis of the femoral head has been reported to be 2~3%<sup>3)</sup>. This condition has been well documented after renal transplantation, but few reports have addressed osteonecrosis following cardiac transplantation, although it was first reported by Danzig, et al. as long ago as 1976<sup>4)</sup>.

*Submitted: November 4, 2009      1st revision: February 11, 2010  
2nd revision: February 24, 2010      3rd revision: June 14, 2010  
Final acceptance: June 14, 2010*

• Address reprint request to **Taek-Rim Yoon, MD**  
Center for Joint Disease, Chonnam National University Hwasun Hospital,  
160 Ilsim-ri, Hwasun-eup, Hwasun-gun, Jeonnam 519-809, Korea  
TEL: +82-61-379-7676 FAX: +82-61-379-7681  
E-mail: tryoon@chonnam.ac.kr

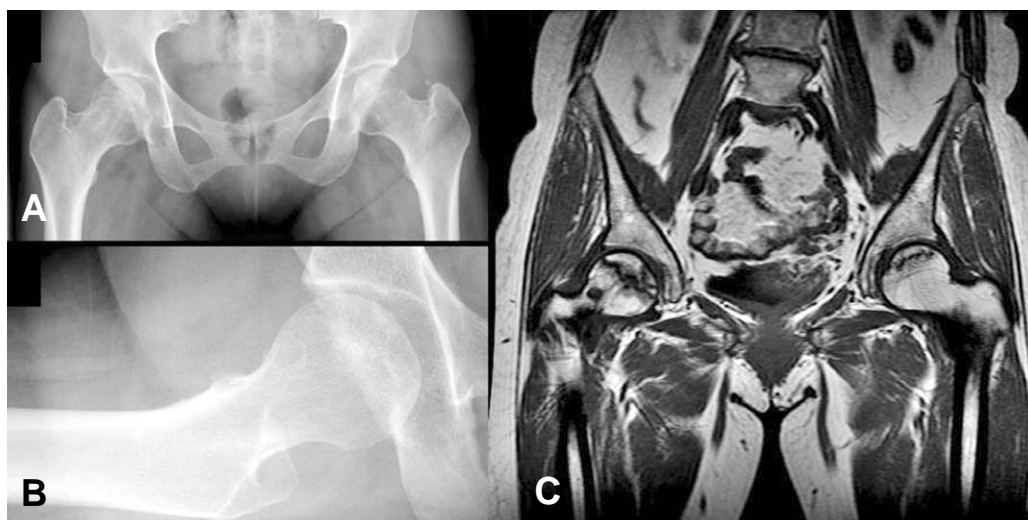
Because patients are invariably administered adrenocortical hormones and immunosuppressive agents after cardiac transplantation, they are at high risk of infection and often develop systemic complications, such as, an electrolyte imbalance. Furthermore, adrenal insufficiency, caused by suppression of the hypophysis-adrenocortical axis after adrenocortical hormone administration, increases the risk of surgery and anesthesia. In particular, anesthesia poses obvious risks for patients with a denervated heart. Authors report a satisfactory outcome for total hip arthroplasty for osteonecrosis of the femoral head after cardiac transplantation.

### Case Report

A 49-year-old woman visited our institution with pain in both hips with right side dominance of 3 weeks duration. She had undergone cardiac transplantation due to dilated cardiomyopathy six years previously and had administered 4 mg of methylprednisone, 250 mg mycophenolic acid, and 8 mg of tacrolimus per day for immunosuppressive purposes. She had a history of medical treatment for repeated pyogenic pneumonia and hyperkalemia. At this presentation, she had a severe limping gait, which apparently tended to aggravate. Furthermore, simple radiography revealed a large synovial pit at the right femoral neck, and MRI showed osteonecrosis of both femoral heads (Fig. 1). 2D-

echocardiography was performed preoperatively. The results were normal left ventricular chamber size, normal wall thickness, and moderate LV systolic function (ejection fraction = 55%) with anterior septal hypokinesia. Cardiovascular department doctor recommended us to monitor cardio-pulmonary status carefully.

Total hip arthroplasty with MIS-2-incision technique was performed on the right hip. Briefly, with the patient in a left lateral position, the joint capsule was exposed and the femoral head removed through an anterior incision placed between the tensor fascia lata and gluteus medius. An acetabular cup was inserted after reaming the acetabulum. The joint capsule was exposed by a posterior incision through gluteus maximus fibers and femoral stem was inserted after femoral reaming. The femoral neck was then turned to the anterior side, and the artificial femoral head was inserted and reduced. A Delta PF® (Lima) acetabular cup and an M/L Taper® (Zimmer, U.S.A.) femoral stem were used without cement fixation. The patient was admitted to aseptic room for 48 hours postoperatively, according to medical consult with careful cardio-pulmonary status monitoring. Prophylactic 1st generation cephalosporin antibiotic was administered (one dose of one gram preoperatively and three doses of one gram during the first day after operation) and immunosuppressors which was administered was continued. The patient started partial weight bearing ambulation with a



**Fig. 1.** (A, B) The anteroposterior and lateral radiographs of pelvis show a large synovial pit at the right femoral neck. (C) T1 weighted coronal MR image show an area of low and intermediate signal intensity lesion on both sides femoral head.

walker on the first day after surgery and crutch ambulation at 1 week. On POD 10, she was discharged without any particular complication.

At her 26-month follow-up, she was ambulated without support. Furthermore, she was able to perform all daily activities without difficulty, and her Harris Hip Score had improved from 46 points preop to 98 points at last follow-up(Fig. 2).

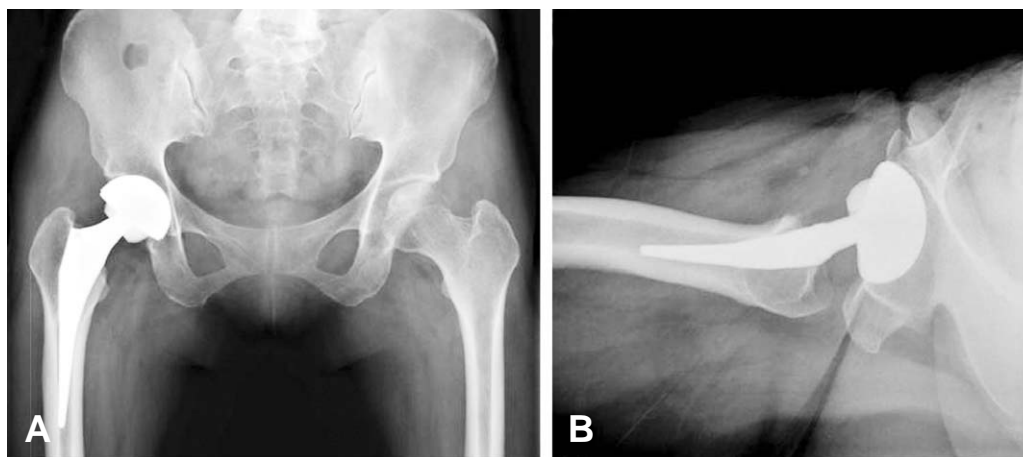
## Discussion

Avascular necrosis was reported to take place in 2~3% of cardiac transplant recipient<sup>3)</sup>. Pre-existing multifactorial metabolic bone disease, low body mass index and muscle mass, postoperative malnutrition and inactivity as well as the immunosuppressive therapy such as high doses of corticosteroids may all lead to poor bone quality and increased risk of osteoarticular disease in cardiac transplant recipients. Etiology of osteonecrosis after cardiac transplantation has still not been clearly elucidated, but the consensus of the studies performed to date shows that it is associated with adrenocortical hormones. A close relation between adrenocortical hormones and osteonecrosis is suggested by the observation that the incidence of osteonecrosis decreases from 17% to 1% when treatment regimen improvements justified minimizing the administration of adrenocortical hormones after renal transplantation, and by the high incidence of osteonecrosis in patients with systemic lupus erythematosus or Cushing's syndrome, who take adrenocortical hormones continuously. Fisher et al, reported that in experimental animals

hypercholesterolemia can occur after the administration of massive doses of adrenocortical hormones, and that this induces fat embolism in bones and subsequent avascular necrosis due to small artery occlusion<sup>5)</sup>. Li et al, showed that adrenocortical hormones cause stem cells in bone marrow to differentiate to fat cells and that this reduces vascularization<sup>6)</sup>. On the other hand Korompilias et al, concluded that adrenocortical hormones are trigger factors and that immune reactions play an important role in pathogenesis of avascular osteonecrosis<sup>7)</sup>. Bradbury et al, reported that osteonecrosis develops on average at 5 months (range 2~12 months) after cardiac transplantation<sup>3)</sup> and Leon et al, reported that the time interval from the heart transplantation to the presentation of avascular necrosis ranged between 7 and 15 months (average 11.3 months<sup>8)</sup>). Similar results have been reported after renal transplantation, which again supports the hypothesis that adrenocortical hormones induce immune reactions and that these cause avascular osteonecrosis.

Daily and maximum dose are known to be more important factors of osteonecrosis development than dose duration or accumulation. Bradbury et al, concluded that osteonecrosis is associated with maximum dose, rather than with accumulated dose in study on cardiac transplantation patients<sup>3)</sup>, and Fisher and Bickel reported that osteonecrosis shows a high association with daily dose, especially when doses exceed 20 mg per day in patients that have undergone renal transplantation<sup>9)</sup>.

Kanter and Samuels reported about the anesthesia for major operations on patients who have



**Fig. 2.** (A, B) Postoperative 26-month anteroposterior and lateral radiographs of pelvis show stable bony ingrowth without radiolucent lines or migration.

transplanted heart. These patients are certainly at increased risk for anesthesia, but with proper management and careful monitoring using the standard patient anesthesia protocol, the risk of anesthesia can be reduced to reasonable levels<sup>10</sup>. In 1977 Burton et al. reported bilateral THA in two patients followed for 14 and 6 months respectively<sup>11</sup>. In 1986 Isono and Woolson evaluated 10 cardiac transplant recipients who have had bilateral total hip arthroplasties (9 patients) and bilateral knee arthroplasties (1 patient). The follow-up of these patients revealed good range of motion of the operated joints without any report of complication<sup>12</sup>. Although the follow-up period was short in both studies, they conclude that the complication rate for THA in heart transplant recipients was similar to that in patients who did not have heart transplant.

Some have argued that cemented THA influences osteonecrosis of the femoral head in patients treated with adrenocortical hormones. In these patients, bone formation is suppressed and bone resorption is increased<sup>13</sup>. Accordingly, the authors advocated cemented THA based on concern that cementless THA could disturb endosteal new bone formation. After cementless THA, new endosteal bone formation on the porous coated surfaces of femoral stem is required for stability, although stable fibrous ingrowth also ensures satisfactory results. Thus, the most important factor is early stability. Furthermore, Engh et al. showed that reduced bone mass and quality per se do not influence new bone formation<sup>14</sup>. We performed cementless THA using the MIS-2-incision technique, which has the advantages of reducing bleeding during surgery and allowing an early return to normal activities and by minimizing injury to muscle<sup>15</sup>. In particular, in coronary transplant patients, which have a high risk of postoperative complications, this technique minimizes bed rest postoperatively and reduces systemic complications, such as, atelectasis and aspiration pneumonia.

Increased numbers of cardiac transplantations and improved patient survival rates are likely to cause a sustained increase in the number of cases of osteonecrosis of the femoral head.

## REFERENCES

1. Barnard CN. *The operation. A human cardiac transplant: an interim report of a successful operation performed at Groote Schuur Hospital, Cape town. S Afr Med J.* 1967;41:1271-4.
2. Roussel JC, Baron O, P?rigaud C, et al. *Outcome of heart transplants 15 to 20 years ago: graft survival, post-transplant morbidity, and risk factors for mortality. J Heart Lung Transplant.* 2008;27:486-93.
3. Bradbury G, Benjamin J, Thompson J, Klees E, Copeland J. *Avascular necrosis of bone after cardiac transplantation. Prevalence and relationship to administration and dosage of steroids. J Bone Joint Surg Am.* 1994;76:1385-8.
4. Danzig LA, Coutis RD, Resnick D. *Avascular necrosis of the femoral head following cardiac transplantation: report of a case. Clin Orthop Relat Res.* 1976;117:217-20.
5. Fisher DE, Bickel WH, Holley KE, Ellefson RD. *Corticosteroid-induced aseptic necrosis. II. Experimental study. Clin Orthop Relat Res.* 1972;84:200-6.
6. Li X, Jin L, Cui Q, Wang GJ, Balian G. *Steroid effects on osteogenesis through mesenchymal cell gene expression. Osteoporos Int.* 2005;16:101-8.
7. Korompilias AV, Gilkeson GS, Seaber AV, Urbaniak JR. *Hemorrhage and thrombus formation in early experimental osteonecrosis. Clin Orthop Relat Res.* 2001;386:11-8.
8. Leön JL, Resines C, Zafra A. *Total hip arthroplasty in heart transplant patients. Acta Orthop Belg.* 2007;73:720-8.
9. Fisher DE, Bickel WH. *Corticosteroid-induced avascular necrosis. A clinical study of seventy-seven patients. J Bone Joint Surg Am.* 1971;53:859-73.
10. Kanter SF, Samuel SI. *Anesthesia for major operations on patients who have transplanted hearts, a review of 29 cases. Anesthesiology.* 1977;46:65-8.
11. Burton DS, Mochizuki RM, Halpern AA. *Total hip arthroplasty in the cardiac transplant patient. Clin Orthop Relat Res.* 1978;130:186-90.
12. Isono SS, Woolson ST, Schurman DJ. *Total joint arthroplasty for steroid-induced osteonecrosis in cardiac transplant patients. Clin Orthop Relat Res.* 1987;217:201-8.
13. Bockman RS, Weinerman SA. *Steroid-induced osteoporosis. Orthop Clin North Am.* 1990;21:97-107.
14. Engh CA, Bobyn JD, Glassman AH. *Porous-coated hip replacement. The factors governing bone ingrowth, stress shielding, and clinical results. J Bone Joint Surg Br.* 1987; 69:45-55.
15. Yoon TR, Park KS, Song EK, Seon JK, Seo HY. *New two-incision minimally invasive total hip arthroplasty: comparison with the one-incision method. J Orthop Sci.* 2009;14:155-60.

국문초록

## 심장이식 환자에서 발생한 대퇴 골두의 무혈성 괴사 - 증례보고 -

김형원 · 윤택림 · 조용진

전남대학교 의과대학 정형외과학교실, 화순전남대병원 관절센터

심장 이식술은 말기 심장 질환에서 가장 좋은 치료 방침이며, 수술 술기의 발달과 술 후 면역요법의 발전으로 심장 이식술 후 생존 기간은 점차 늘어나고 있다. 하지만 면역 요법으로 이용되는 스테로이드나 면역억제제의 영향으로 골감소증, 골다공증, 골절, 골괴사와 같은 정형외과 영역에서의 합병증은 더욱 증가하고 있는 실정이다. 미국 또는 유럽에서 심장 이식술 후 발생한 골괴사에 대한 몇몇 보고가 있었지만, 지금까지 아시아인에 대한 대퇴 골두 무혈성 괴사 보고는 없었다. 이에 저자는 심장 이식술 이후에 발생한 대퇴 골두 무혈성 괴사에 대한 고관절 인공 관절 전치환술 증례를 문헌 고찰과 같이 보고하고자 한다.

**색인 단어:** 심장이식술, 대퇴골부 무혈성 괴사, 고관절 인공관절 전치환술