



# 불안정성 대퇴골 전자간 골절에서 골수강외 정복(Extramedullary Reduction)의 효과: 사체를 이용한 생역학적 연구

박영창 · 윤순필 · 양규현<sup>✉</sup>

연세대학교 의과대학 강남세브란스병원 정형외과학교실

## The Effects of Extramedullary Reduction in Unstable Intertrochanteric Fracture: A Biomechanical Study Using Cadaver Bone

Young Chang Park, M.D., Soon Phil Yoon, M.D., Kyu Hyun Yang, M.D., Ph.D.<sup>✉</sup>

Department of Orthopaedic Surgery, Gangnam Severance Hospital, Yonsei University College of Medicine, Seoul, Korea

Received January 17, 2018  
Revised February 14, 2018  
Accepted May 25, 2018

### ✉Correspondence to:

Kyu Hyun Yang, M.D., Ph.D.  
Department of Orthopaedic Surgery,  
Gangnam Severance Hospital, Yonsei  
University College of Medicine, 211  
Eonju-ro, Gangnam-gu, Seoul 06273,  
Korea  
Tel: +82-2-2019-3414  
Fax: +82-2-573-5393  
E-mail: [kyang@yumc.yonsei.ac.kr](mailto:kyang@yumc.yonsei.ac.kr)

Financial support: None.

Conflict of interests: None.

**Purpose:** To prevent excessive sliding and subsequent fixation failures in unstable intertrochanteric fractures with posteromedial comminution, extramedullary reduction through overlapping of the anteromedial cortices of both proximal and distal fragments as a buttress has been introduced. The purpose of this study was to compare the biomechanical properties between two reduction methods-intramedullary reduction and extramedullary reduction-in treating unstable intertrochanteric fractures with posteromedial comminution (AO/OTA classification 31-A2.2).

**Materials and Methods:** Eight pairs of frozen human cadaveric femora were used. The femora of each pair were randomly assigned to one of two groups: the intramedullary reduction group or the extramedullary reduction group. A single axial load-destruction test was conducted after cephalomedullary nailing. Axial stiffness, maximum load to failure, and energy absorbed to failure were compared between the two groups. Moreover, the pattern of mechanical failure was identified.

**Results:** The mean axial stiffness in the extramedullary reduction group was 27.3% higher than that in the intramedullary reduction group (422.7 N/mm vs. 332.0 N/mm,  $p=0.017$ ). Additionally, compared with the intramedullary reduction group, the mean maximum load to failure and mean energy absorbed to failure in the extramedullary group were 44.9% and 89.6% higher, respectively (2,848.7 N vs. 1,966.5 N,  $p=0.012$  and 27,969.9 N-mm vs. 14,751.0 N-mm,  $p=0.012$ , respectively). In the intramedullary reduction group, the mechanical failure patterns were all sliding and varus deformities. In the extramedullary reduction group, sliding and varus deformities after external rotation were noted in 3 specimens, sliding and varus deformities after internal rotation were noted in 3 specimens, and medial slippage was noted in 2 specimens.

**Conclusion:** In unstable intertrochanteric fractures with posteromedial comminution, the biomechanical properties of extramedullary reduction are superior to those of intramedullary reduction. Anteromedial cortex could be the proper buttress, despite a comminuted posteromedial cortex. It could help enhance the stability of the bone-nail construct.

**Key Words:** Unstable intertrochanteric fracture, Extramedullary reduction, Intramedullary reduction, Biomechanical study

## Introduction

Hip fractures mainly occur in elderly patients, and most of them are treated surgically to enable early ambulation and minimize complications. Recent studies emphasized the importance of neck length after osteosynthesis of intertrochanteric (IT) fracture as well as in femoral neck fracture to restore hip function after union.<sup>1-4)</sup> Several neck length-preserving techniques have been introduced with some success in femoral neck fracture but rarely in unstable IT fracture.<sup>5,6)</sup>

Compression hip screws and intramedullary (IM) nails are commonly used for the operative treatment of IT fractures. These devices are manufactured to allow sliding along the lag screw to achieve compression at the fracture site and to obtain better stability. IM nailing is preferred for unstable IT fractures owing to its mechanical advantages, especially among young surgeons.<sup>7,8)</sup> Despite advances in implants and nailing techniques, the treatment of unstable IT fractures is still challenging because the amount of sliding is difficult to control even after IM nailing. Excessive sliding results in an extremely short femoral neck and sometimes fixation failure due to limited contact on the anteromedial (AM) cortices of both proximal and distal fragments during sliding process. The reduction patterns of the AM cortices are divided into 3 types as follows: 1) IM reduction (all or part of the AM cortex of the proximal head-neck fragment is located within the medullary canal of the distal shaft fragment); 2) anatomical or neutral reduction (AM cortices of both fragments are in contact with the edges); and 3) extramedullary (EM) reduction (all or part of the AM cortex of the proximal head-neck fragment is located outside the medullary canal of the distal shaft fragment).

In order to avoid excessive sliding in unstable IT fractures with posteromedial (PM) comminution and in reverse obliquity fracture, EM reduction has been introduced to reduce the sliding distance and shortening of the lever arm.<sup>9-13)</sup> In EM reduction, the AM cortical bone of the proximal fragment has early bony contact with the distal fragment during sliding, and it theoretically plays a role as a buttress from the beginning and prevents excessive sliding and varus deformity

of the proximal fragment. From a functional point of view, Chang et al.<sup>12)</sup> defined EM reduction as 'positive medial cortical support'. Several clinical studies achieved favorable results with EM reduction. However, there is no biomechanical evidence to support its clinical advantage.

The purpose of this study was to compare biomechanical properties between IM reduction and EM reduction in unstable IT fractures with PM comminution (AO/OTA classification 31-A2.2) using fresh cadaver bone.

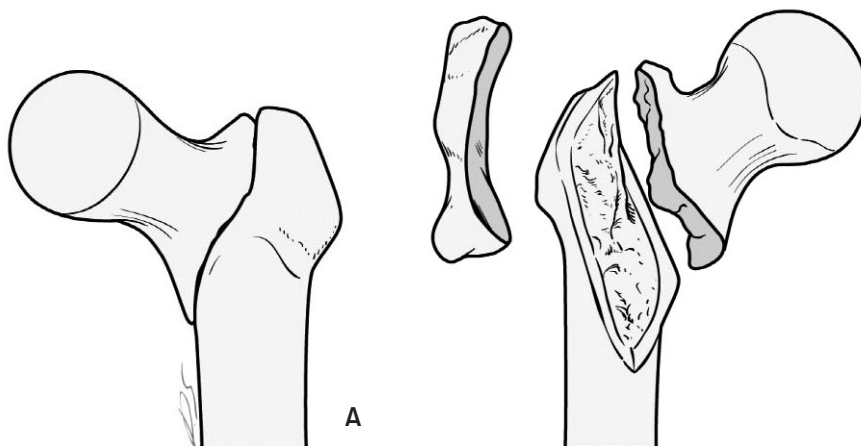
## Materials and Methods

### 1. Specimen preparation

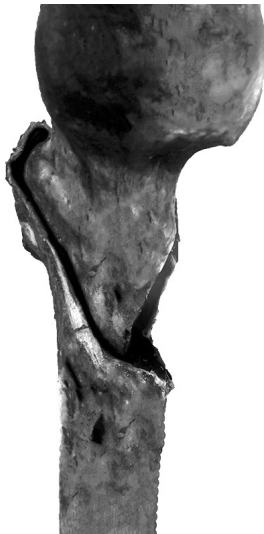Eight matched pairs of fresh frozen human cadaveric femora ( $76.8 \pm 10.1$  years), which were donated to our university, were used for this study. The donors were 3 male and 5 female cadavers. We excluded specimens with previous hip fracture, hip surgery, gross defect or abnormality of the femur, and radiological abnormality of the femur. Each cadaver was maintained at  $-20^{\circ}\text{C}$  before the experiment. The cadavers were thawed at room temperature for 12 hours. All surrounding soft tissues were removed, and the femora were extracted. None of the cadavers were excluded. The femora of each pair were randomly assigned to the IM reduction and EM reduction groups using Excel 2010 random number generator (Microsoft, Redmond, WA, USA).

### 2. Fracture pattern and reduction type

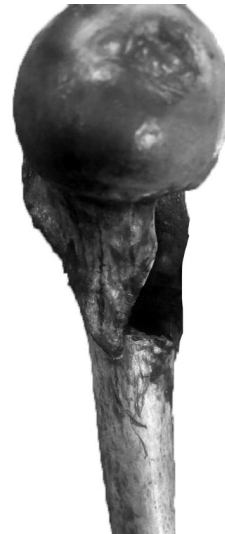Unstable IT fractures with PM defects including the lesser and greater trochanters (AO/OTA classification 31-A2.2) were created using an oscillating saw and osteotome (Fig. 1). Owing to loss of the lesser trochanter and trochanteric crest of the greater trochanter, the contact area between the proximal and distal fragments was limited and very unstable. The PM defect lesion was filled with soft clay<sup>14)</sup> that did not harden for several days to keep the fragments in position for further study. The soft clay held the fragments in position, but it did not interfere with the sliding because it was expelled through a large PM defect during mechani-



**Fig. 1.** Schematic drawing of fracture creation. Unstable intertrochanteric fracture with posteromedial defect including the lesser and greater trochanters (AO/OTA classification 31-A2.2); anterior (A) and posterior (B) views.



**Fig. 2.** Intramedullary reduction. The anteromedial cortex of the proximal fragment is positioned inside the distal shaft fragment (anteromedial aspect of femur).



**Fig. 3.** Extramedullary reduction. The anteromedial cortex of the proximal fragment is positioned outside the distal shaft fragment (anteromedial aspect of femur).

cal loading. IM reduction was made by placing the AM cortex of the proximal fragment in the medullary canal of the distal shaft fragment (Fig. 2). EM reduction was made by placing the AM cortex of the proximal fragment outside of the AM cortex of the distal fragment (Fig. 3). Three K-wires were used for temporary fixation to maintain the reduction status. The femora were resected 25 cm from the femoral head and were mounted onto the testing device.

### 3. Instrumentation

In all specimens, a 130-degree intertrochanteric/sub-

trochanteric (ITST) nail (Zimmer-Biomet, Warsaw, IN, USA), lag screw, sliding nail cap, and single distal interlocking screw were used. In each femur pair, the diameter of the nail and the length of the lag screw were identical. ITST nails were inserted according to the manufacturer's instructions. All procedures were performed under fluoroscopy. An entry point was created at the apex of the greater trochanter. The nail was introduced into the medullary canal after trochanteric reaming. The nail size increased until it fit snugly in the medullary canal. A lag-screw guidewire was then inserted in the infero-central part of the femoral head using a fluoroscope. After confirmation of the pin position, a lag screw

was inserted after reaming. The calcar-referenced tip-apex distance<sup>15)</sup> was less than 25 mm in all specimens. A distal interlocking screw and sliding cap were inserted and tightened.

#### 4. Mechanical testing

Instron 3366 (Instron, Norwood, MA, USA) was used for testing. Each specimen was embedded distally with 15 degrees of inclination in the coronal plane. The angle of 15 to 25 degrees in the varus position was similar to the angle at which the proximal femur was loaded in a single-legged stance phase and was used in several previous biomechanical studies.<sup>15-17)</sup> Assessments were conducted as a single axial load-destruction test with a constant speed of 10 mm/min. A preload of 10 N was applied before the test (Fig. 4).

Load-displacement curves until fixation failure were collected. The axial stiffness, maximum load to failure, and



**Fig. 4.** Setup of the mechanical test. The specimen is embedded at 15 degrees in the varus position.

energy absorbed to failure were calculated from the load-displacement curve. Additionally, the mechanical failure patterns were identified. Fixation failure was defined as lag screw cut-out, nail breakage, secondary fracture of the femur, or axial displacement over 20 mm.

#### 5. Statistical analysis

All statistical analyses were performed using IBM SPSS ver. 20 (IBM Co., Armonk, NY, USA). The Wilcoxon signed-rank test was used for comparing the 2 reduction groups. Statistical significance was set at  $p < 0.05$ .

### Results

#### 1. Biomechanical properties

The mean axial stiffness in the EM reduction group was 27.3% higher compared to that in the IM reduction group ( $p = 0.017$ ). Additionally, compared to the values in the IM reduction group, the mean maximum load to failure and mean energy absorbed to failure in the EM reduction group were 44.9% and 89.6% higher, respectively ( $p = 0.012$  and  $p = 0.012$ , respectively) (Table 1).

**Table 2.** Mechanical Failure Patterns for the Intramedullary Reduction and Extramedullary Reduction Groups

Mechanical failure pattern	Intramedullary reduction (n=8)	Extramedullary reduction (n=8)
Sliding and varus deformity	8 (100)	0 (0)
ER, sliding, and varus deformity	0 (0)	3 (37.5)
IR, sliding, and varus deformity	0 (0)	3 (37.5)
Medial slippage	0 (0)	2 (25.0)

Values are presented as number (%). ER: external rotation, IR: internal rotation.

**Table 1.** Axial Stiffness, Maximum Load to Failure, Energy Absorbed to Failure, and Axial Displacement for the Intramedullary Reduction and Extramedullary Reduction Groups

Variable	Intramedullary reduction	Extramedullary reduction	p-value
Stiffness (N/mm)	332.0±99.2 / 323.8 (260.8-379.1)	422.7±126.8 / 448.5 (305.4-508.3)	0.017
Failure load (N)	1,966.5±1,077.4 / 1,472.3 (1,178.1-2,926.9)	2,848.7±1,057.3 / 2,818.9 (1,966.4-3,797.1)	0.012
Energy (N·mm)	14,751.0±12,383.2 / 12,827.0 (6,794.8-15,969.8)	27,969.9±15,903.6 / 23,561.5 (18,234.5-40,487.5)	0.012
Displacement (mm)	12.6±4.4 / 11.2 (9.3-17.0)	15.8±3.9 / 15.4 (12.7-19.9)	0.018

Values are presented as mean±standard deviation / median (interquartile range).

## 2. Mechanical failure patterns

In the IM reduction group, all specimens showed sliding and varus deformities of the proximal fragment. Fixation failures included lag screw cutout in 7 specimens and axial displacement over 20 mm in 1 specimen.

In the EM reduction group, sliding and varus deformity was noted in 6 specimens after rotation of the proximal fragments (3 external rotation and 3 internal rotation), and medial slippage also occurred in 2 specimens (Table 2).

There was no breakage of the AM cortex of the proximal fragment before fixation failure in either group.

## Discussion

We proved through this study that EM reduction of the AM cortices had benefits on biomechanical factors, especially stiffness, compared to IM reduction. During the initial stage of sliding, medial support, which was achieved by contact between the AM cortices, provided a good medial buttress for the stability of bone–nail complex.

There are several reasons why we should take advantages of the AM cortex in unstable IT fractures. First, even in unstable 31–A2.2 or 2.3 type IT fractures, the anterior lesion

shows a simple fracture pattern while the posterior lesion shows a comminution–complex fracture pattern.<sup>9)</sup> The AM cortex is the keystone in both proximal and distal fragments that can be approximated during open reduction. Second, the AM cortex of the proximal femur is generally known to be the thickest and strongest. The weight load during walking is transmitted through the AM cortex of the proximal femur, so the cortical thickness and bone quality are retained even in elderly individuals.<sup>18)</sup> Third, restoration of the medial buttress is a fundamental factor in the tension band principle.<sup>19)</sup> The lever arm of IM devices is shorter than that of EM devices, such as the sliding hip screw. Although the IM nail has advantages with regard to mechanical properties, we cannot ignore the importance of medial cortical contact in osteoporotic bone.

The results of this study indicated superior biomechanical properties with EM reduction compared to that with IM reduction (Fig. 5, 6), and this was associated with early bony contact of the AM cortex during sliding of the proximal fragment. Aside from superior stiffness in the EM reduction group, maximum load to failure and energy absorbed to failure were also superior in the EM group because the AM cortex was preserved until fixation failure in all specimens.

In 6 of the 8 specimens that underwent EM reduction,

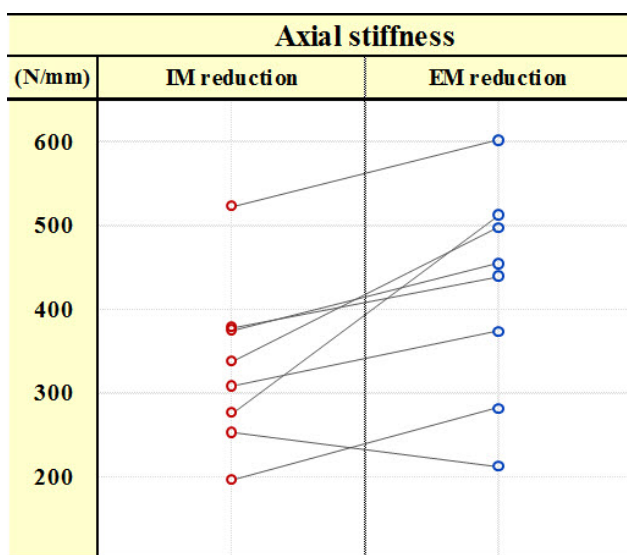


Fig. 5. Paired graph showing differences in axial stiffness between the intramedullary (IM) reduction and extramedullary (EM) reduction groups.

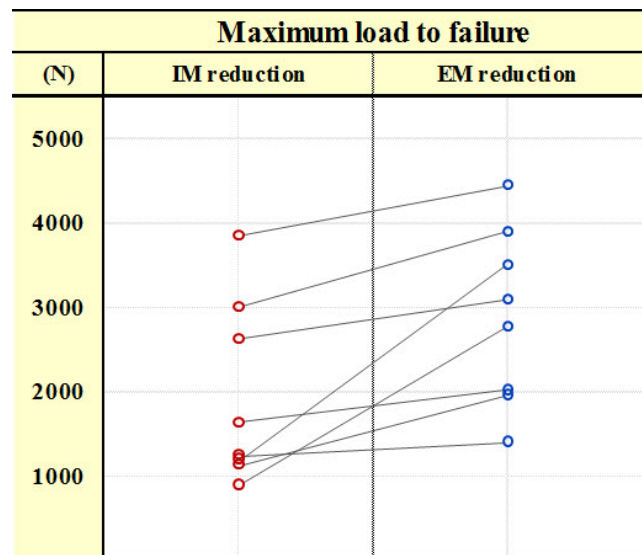


Fig. 6. Paired graph showing differences in maximum load to failure between the intramedullary (IM) reduction and extramedullary (EM) reduction groups.

the proximal fragment was rotated, and it lost the role of a buttress during advancement of axial compression. Three proximal fragments rotated internally and 3 externally. After internal or external rotation, these specimens resulted in varus deformity and fixation failure at the end of the loading test. In one pair of specimens from a 90-year-old female, axial stiffness in EM reduction was lower than that in IM reduction, probably due to early rotation of the proximal fragment in the initial stage of loading by loss of lag screw fixation in the osteoporotic femoral head. This caused early loss of effective contact between the two cortices in both fragments. This phenomenon was described well by Tera-moto et al.,<sup>20)</sup> who indicated that 26.4% of anatomical and EM reduction cases converted to the IM position during the rehabilitation period after cephalomedullary nailing. EM reduction could be vulnerable to rotation of the proximal fragment for various reasons. First, the contact area of the AM cortices is limited. Therefore, the proximal fragment may rotate externally or internally according to the contact point. Second, the initial AM displacement of the proximal fragment causes a corresponding increase in the posterior bone defect. These findings suggested that implants with better control of the proximal fragment with regard to rotation during weight bearing are recommended in an intended EM reduction procedure.

On comparing alignments after fixation between EM reduction and IM reduction, EM reduction showed a neutral or slightly valgus position, while IM reduction showed a slightly varus position in the coronal plane. It is known that a slightly valgus position in trochanteric fractures results in better postoperative outcomes.<sup>21,22)</sup> Even with consideration of the alignment, EM reduction appears to be better than IM reduction because of a sound medial buttress.

The present study had several limitations. First, among the 3 available reduction patterns, the anatomical reduction pattern was excluded from the comparison in this study. In fact, anatomical reduction in IT fractures with PM comminution is difficult to achieve in the patients after closed reduction, and most cases shown as anatomical reduction by fluoroscopy are regarded as a subtype of EM reduction or IM reduction. Consequently, we performed comparisons for

only 2 reduction patterns, excluding anatomical reduction. Second, in the EM reduction group, the proximal fragments moved in unpredictable directions: external rotation, internal rotation, and vertical displacement. Rotational direction might be influenced by the status of the contact point on the AM cortex, different anatomical features, or cadaveric bone quality. In order to check these movements accurately in the future, we should check three-dimensional measurements of the fracture fragments. A cyclic load test with accurate three-dimensional measurement would be helpful in better understanding the effects of the two reduction types.

Nevertheless, this is the first biomechanical study according to the reduction patterns of the AM cortex in IT fractures with PM comminution, and its findings of the superior biomechanical properties of EM reduction are meaningful and support published clinical results regarding EM reduction. The axial stiffness, maximum load to failure, and energy absorbed to failure are higher with EM reduction than with IM reduction. The AM cortex could be a proper buttress despite a comminuted PM cortex and could help enhance the stability of the bone-nail construct.

## Conclusion

In unstable IT fractures with PM comminution, the biomechanical properties of EM reduction are superior to those of IM reduction. The AM cortex could be a proper buttress despite a comminuted PM cortex and could help enhance the stability of the bone-nail construct.

## Acknowledgements

This study was supported by our university research grants (6-2015-0149) and university industry research grants (2015-31-0789). And the authors would like to thank Dong-Su Jang, MFA (Medical Illustrator), for his help with the illustrations.

## 요 약

**목적:** 본 연구는 후내측 피질골의 분쇄가 있는 불안정성 전자



간 골절(AO/OTA classification 31-A2.2)에서 골절 부위 정복 형태에 따른 생역학적 특성을 신선 냉동 사체를 사용하여 실험하였다.

**대상 및 방법:** 총 8쌍의 신선 냉동 사체의 대퇴골을 무작위로 각각 골수강내 정복과 골수강외 정복 형태로 금속정 고정을 시행한 후 축성 압박 일회성 파괴 실험을 시행하였다. 초기 축성 강성, 최대 실패 하중 및 고정실패까지 총 흡수 에너지를 비교하였으며 고정실패 패턴을 확인하였다.

**결과:** 골수강외 정복은 골수강내 정복과 비교하여 평균 초기 축성 강성(422.7 N/mm vs. 332.0 N/mm,  $p=0.017$ ), 최대 실패 하중(2,848.7 N vs. 1,966.5 N,  $p=0.012$ ) 및 고정실패까지 총 흡수 에너지(27,969.9 N·mm vs. 14,751.0 N·mm,  $p=0.012$ )가 각각 27.3%, 44.9%, 89.6% 높았다.

**결론:** 후내측 피질골 결손을 동반된 불안정성 전자간 골절에서 골수강외 정복은 골수강내 정복과 비교하여 생역학적으로 우수한 결과를 보였다. 전내측 피질골은 후내측 피질골 결손에도 불구하고 적절한 지지대가 될 수 있으며 골절 고정의 안정성을 높이는 데도 도움을 줄 수 있음을 확인하였다.

**색인 단어:** 불안정성 전자간 골절, 골수강외 정복, 골수강내 정복, 생역학적 실험

## ORCID

박영창, <https://orcid.org/0000-0003-3726-4707>

윤순필, <https://orcid.org/0000-0003-1101-6879>

양규현, <https://orcid.org/0000-0001-7183-588X>

## References

1. Zlowodzki M, Jönsson A, Paulke R, Kregor PJ, Bhandari M: Shortening after femoral neck fracture fixation: is there a solution? *Clin Orthop Relat Res*, 461: 213–218, 2007.
2. Zlowodzki M, Brink O, Switzer J, et al: The effect of shortening and varus collapse of the femoral neck on function after fixation of intracapsular fracture of the hip: a multi-centre cohort study. *J Bone Joint Surg Br*, 90: 1487–1494, 2008.
3. Song HK, Yoon HK, Yang KH: Presence of a nail in the medullary canal: is it enough to prevent femoral neck shortening in trochanteric fracture? *Yonsei Med J*, 55: 1400–1405, 2014.
4. Gilat R, Lubovsky O, Atoun E, et al: Proximal femoral shortening after cephalomedullary nail insertion for intertrochanteric fractures. *J Orthop Trauma*, 31: 311–315, 2017.
5. Filipov O: Biplane double-supported screw fixation (F-technique): a method of screw fixation at osteoporotic fractures of the femoral neck. *Eur J Orthop Surg Traumatol*, 21: 539–543, 2011.
6. Mir H, Collinge C: Application of a medial buttress plate may prevent many treatment failures seen after fixation of vertical femoral neck fractures in young adults. *Med Hypotheses*, 84: 429–433, 2015.
7. Haidukewych GJ: Intertrochanteric fractures: ten tips to improve results. *J Bone Joint Surg Am*, 91: 712–719, 2009.
8. Weiser L, Ruppel AA, Nüchtern JV, et al: Extra- vs. intramedullary treatment of pertrochanteric fractures: a biomechanical in vitro study comparing dynamic hip screw and intramedullary nail. *Arch Orthop Trauma Surg*, 135: 1101–1106, 2015.
9. Carr JB: The anterior and medial reduction of intertrochanteric fractures: a simple method to obtain a stable reduction. *J Orthop Trauma*, 21: 485–489, 2007.
10. Tsukada S, Okumura G, Matsueda M: Postoperative stability on lateral radiographs in the surgical treatment of pertrochanteric hip fractures. *Arch Orthop Trauma Surg*, 132: 839–846, 2012.
11. Kozono N, Ikemura S, Yamashita A, Harada T, Watanabe T, Shirasawa K: Direct reduction may need to be considered to avoid postoperative subtype P in patients with an unstable trochanteric fracture: a retrospective study using a multivariate analysis. *Arch Orthop Trauma Surg*, 134: 1649–1654, 2014.
12. Chang SM, Zhang YQ, Ma Z, Li Q, Dargel J, Eysel P: Fracture reduction with positive medial cortical support: a key element in stability reconstruction for the unstable pertrochanteric hip fractures. *Arch Orthop Trauma Surg*, 135: 811–818, 2015.
13. Ito J, Takakubo Y, Sasaki K, Sasaki J, Owashi K, Takagi M: Prevention of excessive postoperative sliding of the short femoral nail in femoral trochanteric fractures. *Arch Orthop Trauma Surg*, 135: 651–657, 2015.
14. Park SY, Park J, Rhee DJ, Yoon HK, Yang KH: Anterior or posterior obliquity of the lag screw in the lateral view—does it affect the sliding characteristics on unstable trochanteric fractures? *Injury*, 38: 785–791, 2007.
15. Kuzyk PR, Zdero R, Shah S, Olsen M, Waddell JP, Schemitsch EH: Femoral head lag screw position for cephalomedullary nails: a biomechanical analysis. *J Orthop Trauma*, 26: 414–421, 2012.
16. Rybicki EF, Simonen FA, Weis EB Jr: On the mathematical analysis of stress in the human femur. *J Biomech*, 5: 203–215, 1972.
17. Nicayenzi B, Shah S, Schemitsch EH, Bougherara H, Zdero R: The biomechanical effect of changes in cancellous bone density on synthetic femur behaviour. *Proc Inst Mech Eng H*, 25: 1050–1060, 2011.
18. Poole KE, Mayhew PM, Rose CM, et al: Changing structure of the femoral neck across the adult female lifespan. *J Bone Miner Res*, 25: 482–491, 2010.
19. Rüedi TP, Buckley RE, Moran CG: AO principles of fracture management, 2nd ed. New York, Thieme: 249–256, 2007.

20. Teramoto H, Uchida K, Kaneko S, Koshimune K, Ise M, Murakami T: The change of anatomical reposition cases in femoral trochanteric fracture with lateral view X ray. *Fracture*, 38: 650–652, 2016.
21. Parker MJ: Valgus reduction of trochanteric fractures. *Injury*, 24: 313–316, 1993.
22. Andruszkow H, Frink M, Frömke C, et al: Tip apex distance, hip screw placement, and neck shaft angle as potential risk factors for cut-out failure of hip screws after surgical treatment of intertrochanteric fractures. *Int Orthop*, 36: 2347–2354, 2012.