



분절성 쇄골 골절의 수술적 치료와 비수술적 치료 - 증례 보고 -

하성식 · 홍기도 · 심재천 · 서이락 · 남태석[✉]

삼육서울병원 정형외과

The Different Treatment Methods for Segmental Fractures of the Clavicle - Cases Report -

Sung-Sik Ha, M.D., Ki-Do Hong, M.D., Jae-Cheon Sim, M.D., Yi-Rak Seo, M.D., Tae-Seok Nam, M.D., Ph.D.[✉]

Department of Orthopedic Surgery, Sahmyook Medical Center, Seoul, Korea

Received January 16, 2017

Revised April 9, 2017

Accepted June 13, 2017

✉Correspondence to:

Tae-Seok Nam, M.D., Ph.D.
Department of Orthopedic Surgery,
Sahmyook Medical Center, 82 Mangu-
ro, Dongdaemun-gu, Seoul 02500,
Korea

Tel: +82-2-2210-3580

Fax: +82-2-2210-2673

E-mail: tsnam74@gmail.com

Financial support: None.

Conflict of interests: None.

Segmental fractures of the clavicle are very rare. Therefore, to date, there has not been a clear, standardized method of management of segmental clavicle fractures. Herein, two patients with a segmental fracture are described: One patient was treated conservatively, while another patient was treated operatively. Both patients showed excellent results. We discuss the various management options with a literature review.

Key Words: Clavicle, Conservative treatment, Treatment

Among clavicle fractures, 69% occur in the diaphysis, 28% in the distal and 3% in the proximal position.¹⁾ Segmental fractures involving the distal and the proximal ends of the clavicle are even rarer. The injury mechanism is often unclear and the management of these fractures remains controversial. We report two cases with a segmental fracture are described: One patient was treated conservatively and another patient was treated operatively and both of all,

excellent results were achieved. The management of segmental clavicle injuries is discussed.

Case Reports

1. Case 1

A 40-year-old man presented to the outpatient clinic

with pain over the right clavicle following a history of fall from height. There was no external wound. Physical examination revealed tenderness on proximal and distal portion of the clavicle. Movements of the shoulder joint were restricted due to referred pain in the clavicle. There was no evidence of neurovascular deficit and no other significant combined injuries.

Radiographs showed a segmental fracture clavicle with lateral and medial end of clavicle (Fig. 1). Computed tomography showed segmental proximal and distal fracture with displacement, especially proximal end (Fig. 2).

Initially, we planned operative treatment for the fracture.

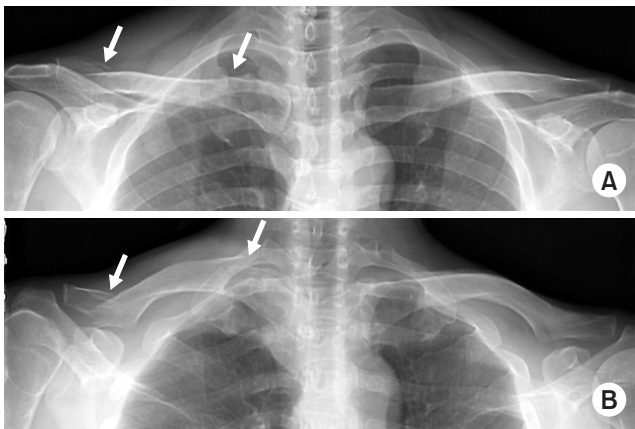


Fig. 1. Both clavicle anteroposterior (A) and lordotic view (B) radiographies showed segmental fracture of the clavicle (arrows).

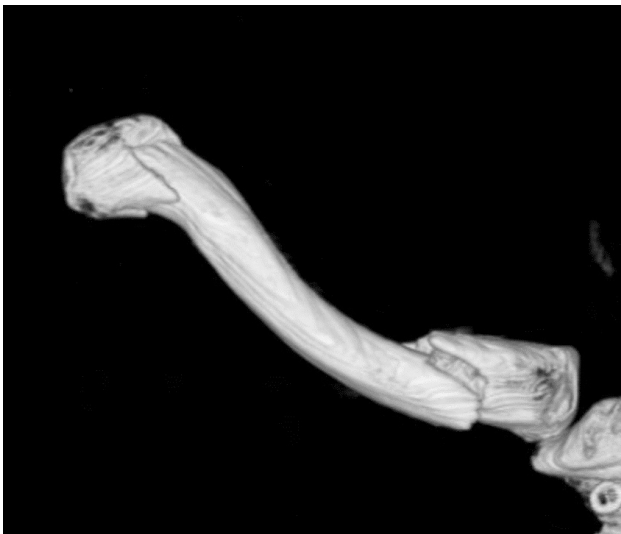

Fig. 2. Computed tomography showed three-dimensional reconstruction of the right clavicle.

But he refused operative treatment under anesthesia. So, we changed the initial plan. Within 2 weeks after trauma, if the degree of displacement is more progress than initial radiography, we plan to perform operative treatment. He was applied figure-eight-bandage to prevent shortening of clavicle for 8 weeks. We checked the radiography of the clavicle weekly. Fortunately, the degree of displacement was not more progress than initial radiography. He removed the brace at the time of 8 weeks after trauma. After 3 months later, he was able to move full range of motion. At the last follow-up (3 years after trauma), we checked the radiography (Fig. 3).

2. Case 2

A 62-year-old male, right hand dominant, presented to the emergency department with pain over the right clavicle following a history of bicycle accident. There was no external wound. The skin was not at risk.

Physical examination revealed tenderness on right mid shaft and distal portion of the clavicle. Movements of the shoulder joint were restricted due to pain. There was no evidence of neurovascular deficit and no other significant combined injuries.

Radiographs showed a segmental clavicle fracture with distal end and mid-shaft of clavicle (Fig. 4). Computed tomography showed mid-shaft and distal fracture with displacement, especially distal end (Fig. 5).

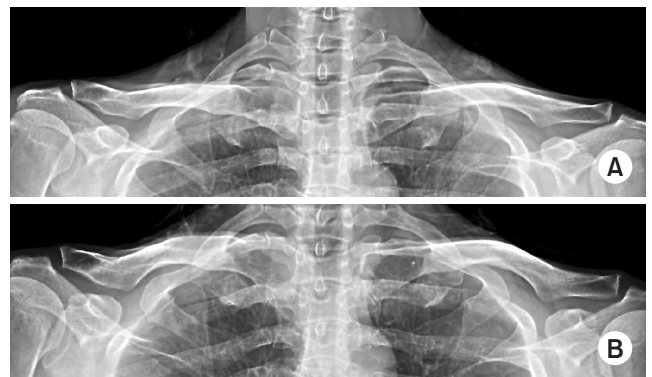

Fig. 3. At 3 years after trauma, both clavicle anteroposterior (A) and lordotic view (B) radiographies showed complete union of the right clavicle.

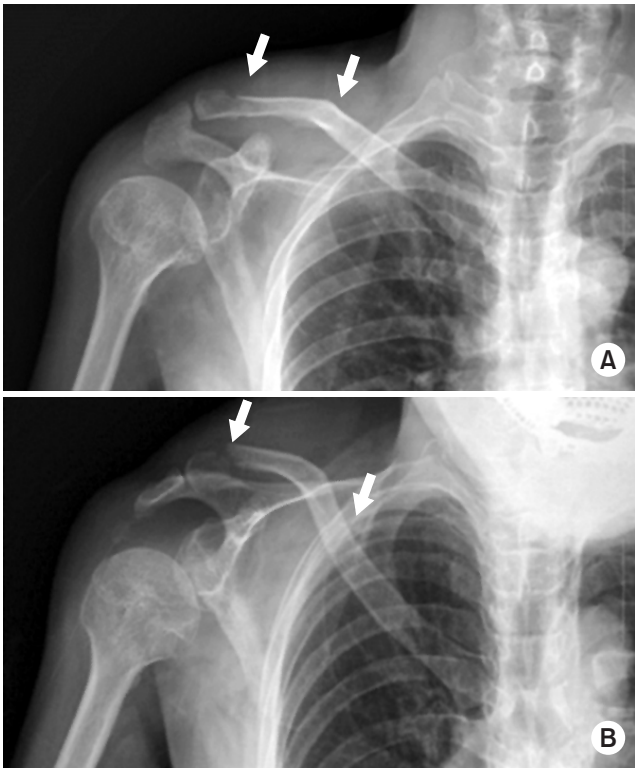


Fig. 4. Right clavicle anteroposterior (A) and lordotic view (B) radiographies showed a segmental fracture of the clavicle (arrows).

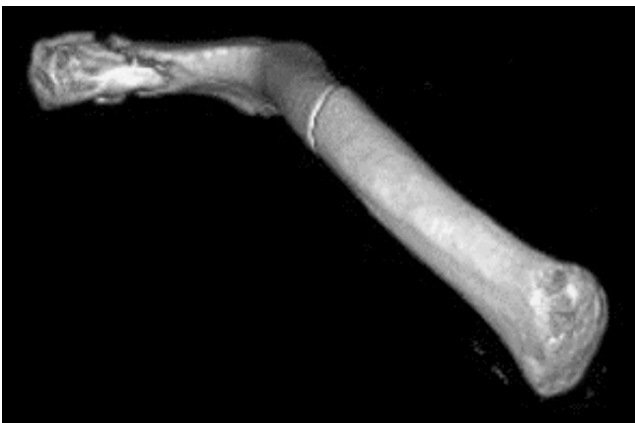

Fig. 5. Computed tomography showed a three-dimensional reconstruction image of the right clavicle.

We planned operative treatment for the fracture. Operation was performed under general anesthesia in a beach chair position. Closed reduction and percutaneous pinning with a Steinmann pin of mid-clavicle fracture was done. Open reduction with pinning and wiring of distal clavicle was done. Post-operative radiograph showed the final fixation achieved (Fig. 6).

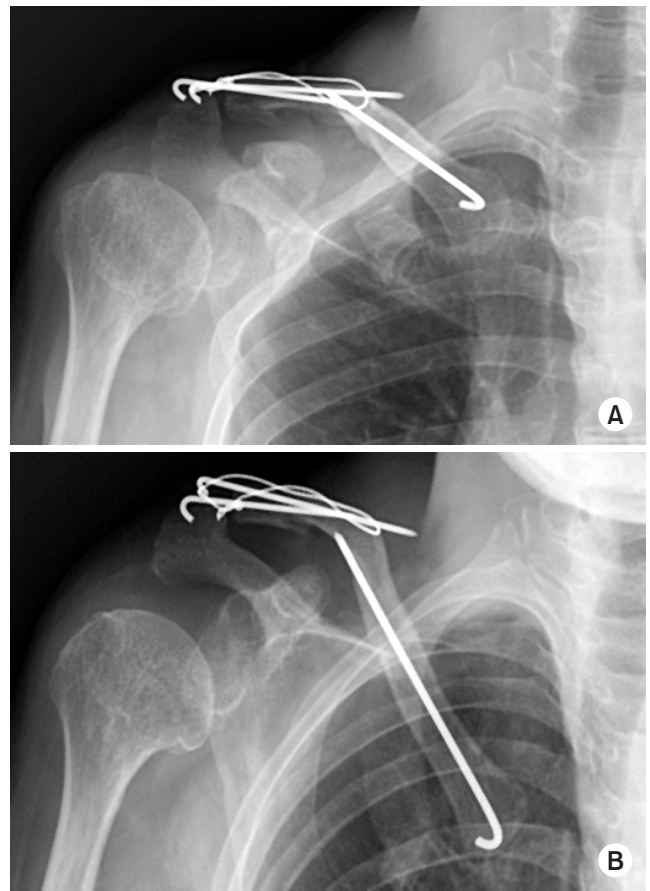


Fig. 6. At 7 months after trauma, Right clavicle anteroposterior (A) and lordotic view (B) radiographies were shown.

Postoperatively, the arm was supported in an arm-sling, with the patient instructed to perform regular hand grasping and elbow range of motion exercises, as well as gentle pendulum exercises of the shoulder. After then, passive stretching exercise and strengthening exercise were followed. The patient had pain-free full range of movement of shoulder joint after 12 weeks.

Discussion

Clavicle fractures are common, comprising 2.6% of all adult fractures. Midshaft clavicular fractures are the most common, ranging from 69% and 82%, distal fractures comprise 21% to 28%, and proximal fractures occur between 2% and 3%.¹⁾ The segmental clavicle fracture is an uncommon pattern. One study reported that 0.8% of clavicle fractures was segmental.²⁾

Clavicle fractures are usually caused by a direct trauma to the shoulder, but the mechanism of injury leading to a segmental clavicle fracture is not well understood. Some reports described that this type fracture occur due to two separate concurrent forces.³⁾ One is direct force on the point of the shoulder girdle due to fall. The other is an indirect force, which may give rise to clavicle fractures by the shear–ing force delivered from the humerus to the sternum.

Fractures of the proximal clavicle are difficult to visualize because overlying structures in the chest obscure the view of the proximal end. For rare proximal fractures, particularly those that extend into the sternoclavicular joint, a Hobb’s view or a serendipity view or computed tomography scan may be helpful to access the fractures and identify their relationship to the sternoclavicular joint. Recently, one re–ported a case of neglected segmental clavicle fracture.⁴⁾ Ac–cording to the report, initially operation was performed on distal end of clavicle using hook plate. After operation, pa–tient had ongoing pain over the medial clavicular region. He underwent operative treatment for medial clavicle fracture on 6 weeks later after initial injury. We recommend that physician examine carefully including tenderness on ipsilat–eral sternoclavicular joint for the patient of clavicle fracture. This simple step is very helpful for management of clavicular fracture and avoidance of misdiagnosis.

The management of segmental fractures has little stan–dard guidance in the literature, with some reports of suc–cessful operative^{3,5)} and non–operative management.⁶⁾ Miller et al.⁵⁾ presented a report of fracture of the medial and lateral extremity of the clavicle with the use of a reconstruction plate and another with locking T–plate. Authors emphasized that due to the rarity of the case, there is no routine surgical technique described for the treatment of this type of fracture. Recently reported cases were summarized (Table 1).^{4,6–10)} According to previous reports, operative treatment over–weighted than conservative treatment. Operative technique was plate and screw on proximal lesion in all cases and K–wire fixation on or hook plate on distal lesion.

In this report, we compared two possible methods, one operatively and one conservatively treatment, for the rare fracture pattern of clavicle. And the results showed excel–

Table 1. Summary of Treatment for Segmental Clavicle Fracture

Study (year)	Patient demogra– phy		Cause of injury	Treatment	Classification	Operative technique		Remarks
	Age (yr)	Sex				Proximal	Distal	
Pang et al.(2003) ⁶⁾	19	Male	Fell off a pull-up bar	Non-operation	Bipolar	-	-	-
	76	Male	Motorcycle accident	Non-operation	Bipolar	-	-	-
Sethi et al.(2012) ⁸⁾	70	Female	Fall down a flight of seven stairs	Non-operation	Bipolar	-	-	-
Grossi (2015) ⁷⁾	41	Male	Fell from a roof	Operation	Segmental	Plating	K-wire	-
Marjoram and Chakrabarti(2015) ⁹⁾	40	Male	Fell from a motorcycle	Operation	Segmental	Plating	Hook plate	-
Varelas et al.(2015) ¹⁰⁾	68	Female	Slipped on ice	Operation	Bipolar	Plate & screw	Plate & screw	-
Yalizi et al.(2016) ⁴⁾	38	Male	Fell from a bike	Operation	Bipolar	Plating	Hook plate	Late diagnosis for medial le–sion (2 stage operation)
This report	40	Male	Fell from a height	Non-operation	Bipolar	-	-	-
	62	Male	Bike accident	Operation	Segmental	K-wire	Tension band wiring	-

lent outcomes for both treatments. The treatment should be based on the individual fracture pattern and patient characteristics.

요 약

분절성 쇄골 골절은 매우 드물며, 그 치료 방법에 대해 명확히 정립되어 있지 않다. 분절성 쇄골 골절을 가진 환자에서 각각 보존적 치료를 시행한 예와 수술적 치료를 시행한 예를 통해 좋은 결과를 얻었던 2예를 보고자 한다. 또한 문헌 고찰을 통해 유사한 경우의 치료에 대해 논하고자 한다.

색인 단어: 쇄골, 보존적 치료, 치료

ORCID

하성식, <http://orcid.org/0000-0002-8138-9489>

홍기도, <http://orcid.org/0000-0002-0861-6868>

심재천, <http://orcid.org/0000-0002-3451-4961>

서이락, <http://orcid.org/0000-0002-8683-4844>

남태석, <http://orcid.org/0000-0003-0589-5790>

References

1. Robinson CM: Fractures of the clavicle in the adult. Epidemiology and classification. J Bone Joint Surg Br, 80: 476-484, 1998.
2. Jupiter JB, Leffert RD: Non-union of the clavicle. Associated complications and surgical management. J Bone Joint Surg Am, 69: 753-760, 1987.
3. Heywood R, Clasper J: An unusual case of segmental clavicle fracture. J R Army Med Corps, 151: 93-94, 2005.
4. Yalizi MA, Hoy GA, Ek ET: A rare case of bipolar clavicle fracture. Case Rep Orthop, 2016: 4309828, 2016.
5. Miller D, Smith KD, McClelland D: Bipolar segmental clavicle fracture. Eur J Orthop Surg Traumatol, 19: 337-339, 2009.
6. Pang KP, Yung SW, Lee TS, Pang CE: Bipolar clavicular injury. Med J Malaysia, 58: 621-624, 2003.
7. Grossi EA. Segmental clavicle fracture. Rev Bras Ortop, 46: 733-735, 2015.
8. Sethi K, Newman SD, Bhattacharya R. An unusual case of bipolar segmental clavicle fracture. Orthop Rev (Pavia), 4: e26, 2012.
9. Marjoram TP, Chakrabarti A. Segmental clavicle fracture and acromio-clavicular joint disruption: an unusual case report. Shoulder Elbow, 7: 187-9, 2015.
10. Varelas N, Joosse P, Zermatten P. Operative Treatment of an atypical segmental bipolar fracture of the clavicle. Arch Trauma Res, 4: e29923, 2015.