

Ilizarov

: , Ilizarov
 : 1993 11 2000 3 Ilizarov 14, 15 , , ,
 , , 가 , 가 , , ,
 .
 : 22 (13 53) . 45 . 14 13 (93%) 가
 , 11 (73%) . 8 (53%) , 3 9 (60%), 4 6 (40%)
 . 10 (67%) 가 , 15, 51 5 (9.8%)
 . 가 3 2 , 2 , 1 8.1
 , 5 (33%), 2 (13%), 1 (7%), 7 (47%)
 ,
 : Ilizarov ,
 : , Ilizarov

Treatment of the Segmental Fractures of Tibia with Ilizarov External Fixation

Kwang Soon Song, M.D., Chul Hyung Kang, M.D., Byung Woo Min, M.D., Si Hyun Jeon, M.D.,
Ki Chul Bae, M.D., In Kyu Kim, M.D.

Department of Orthopedic Surgery, School of Medicine, Keimyung University, Daegu, Korea

Purpose: To emphasize an effectiveness of the Ilizarov circular external fixator in treatment of the complicated segmental fractures of the tibia.

Materials and Methods: We had analyzed 15 cases in 14 persons, treated from November 1993 to March 2000. We analyzed several considering factors including age, etiology, type of fracture, number of the segmentation, associated injuries, open or closed fracture, healing time, additional bone graft, clinical results and complications.

Results: The mean period of follow up was 22 months. The mean age was 45 years. The etiology was traffic accident in 13 persons. Open fracture were 11 cases (73%). Associated injuries were noted in 8 persons (53%). The number of segmentation were three segments in 9 cases (60%) and four segments in 6 cases (40%). Additional manipulations after first application were needed in 10 cases (67%). Bone graft were performed in 5 fracture site (9.8%), proximal fracture site in two and distal in two, middle in one. Mean period of application of external fixator for healing was 8.1 Months. Procedures for soft tissue injuries performed in 3 cases including two split thickness skin graft and distant flap surgery. The results were graded as excellent in 5 cases, good in 2 cases, fair in 1 cases, poor in 7 cases. Limitation of motion in ankle joint was major cause of poor results.

Conclusion: We considered that ilizarov circular external fixator is one of effective treatment modality in treatment of the complicated segmental tibia fractures.

Key Words: Tibia, Segmental fracture, Ilizarov

:

194

Tel : 053-250-7250 · Fax : 053-250-7205
E-mail : skspos@dsmc.or.kr

Address reprint requests to : Kwang-Soon Song, M.D.

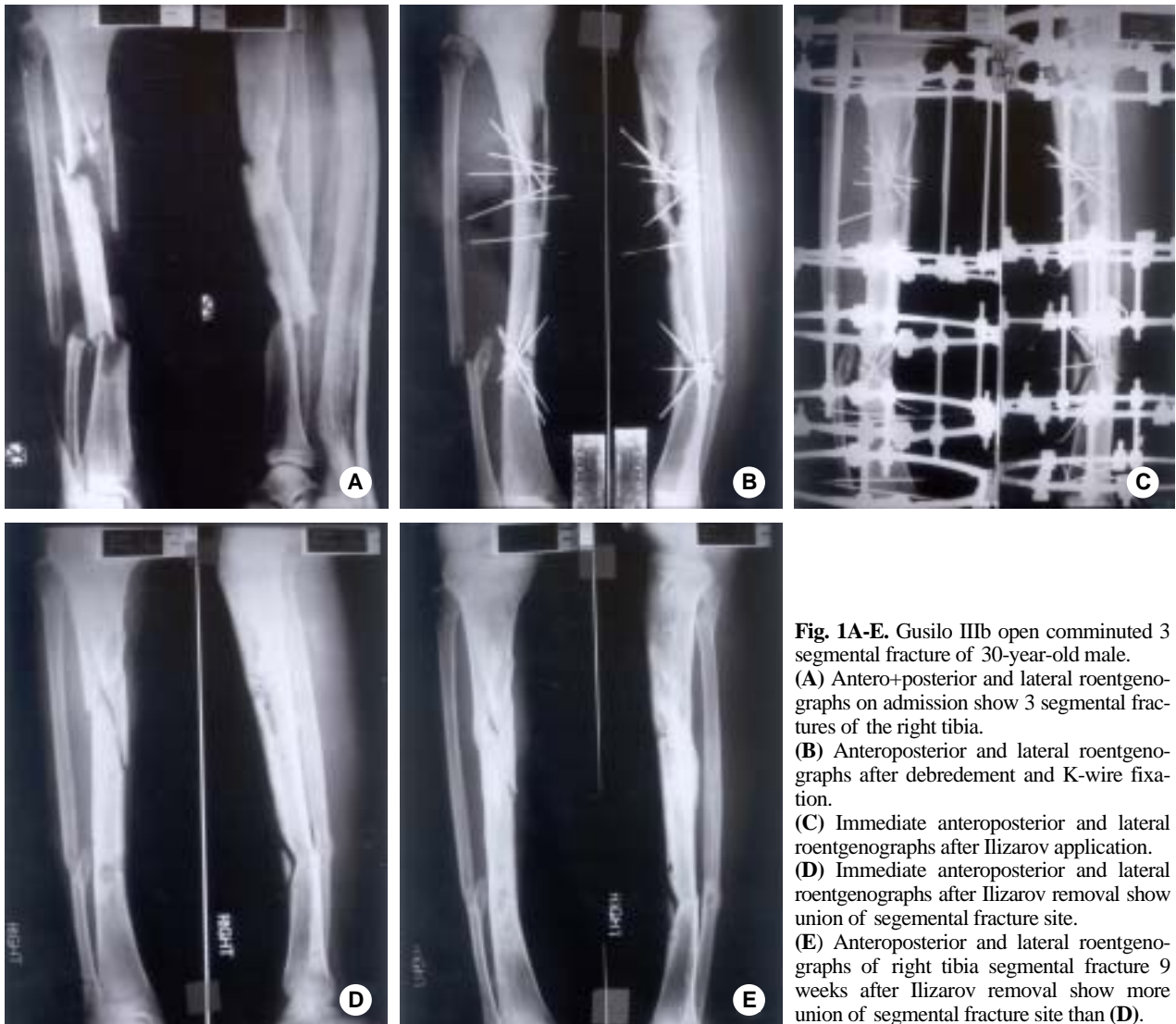
Department of Orthopaedic Surgery, Dongsan Medical Center, Keimyung University, 194 Dongsan-dong, Joong-gu, Taegu 700-712
Tel : 82-53-250-7250 · Fax : 82-53-250-7205
E-mail : skspos@dsmc.or.kr

가 2 . 5 cm , 3 cm 가 12 . 10 가 5 , 4 , 1 , 가 1 .

가 , , 15 , 51 5 (9.8%)

가 1 16.4 . 2 , 2 , Ilizarov 1 . Gustilo 1, 2 Gustilo 3 3 1 , 1 , 1 Ilizarov 가 가 가 1993 11 , 2000 3 , Iliazov 13 , 14 , 15 32.4 , 5 30.4 가 5 (33%), 2 (13%), 1 (7%), 7 (47%) , 가 (Fig. 1, 2).

가 (excellent), 75% (good), 50% (fair), 50% (poor) , 가 가 50~60% ²¹⁾ . 15 30 73 , 45 . 12 , 76%가 , 66% 2 가 . 14 13 가 (93%) , 1 , 11 (73%) , Gu- ²⁹⁾ . stilo 1 6 , 2 2 , 3a 1 , 3b 2 , 8 (53%) , 2 , 4 , 3 , 2 , 가 , 가 , 가 1 . 3 9 (60%), 4 6 (40%) 가 3 가 ³⁹⁾ . 가 3 , 5 , 63~83% 가 1 , 가 4 , ^{14~16)} . 가 가 가 4 , ,



가 가 6).

33).

가 ,

가 ,

(DCP)

(Bridge plate) 가

가 5).

(LC-DCP)

가 ,

17).

Ilizarov

1952

가 가

가 ,

가

6).

Smith

가

38). Iliz-

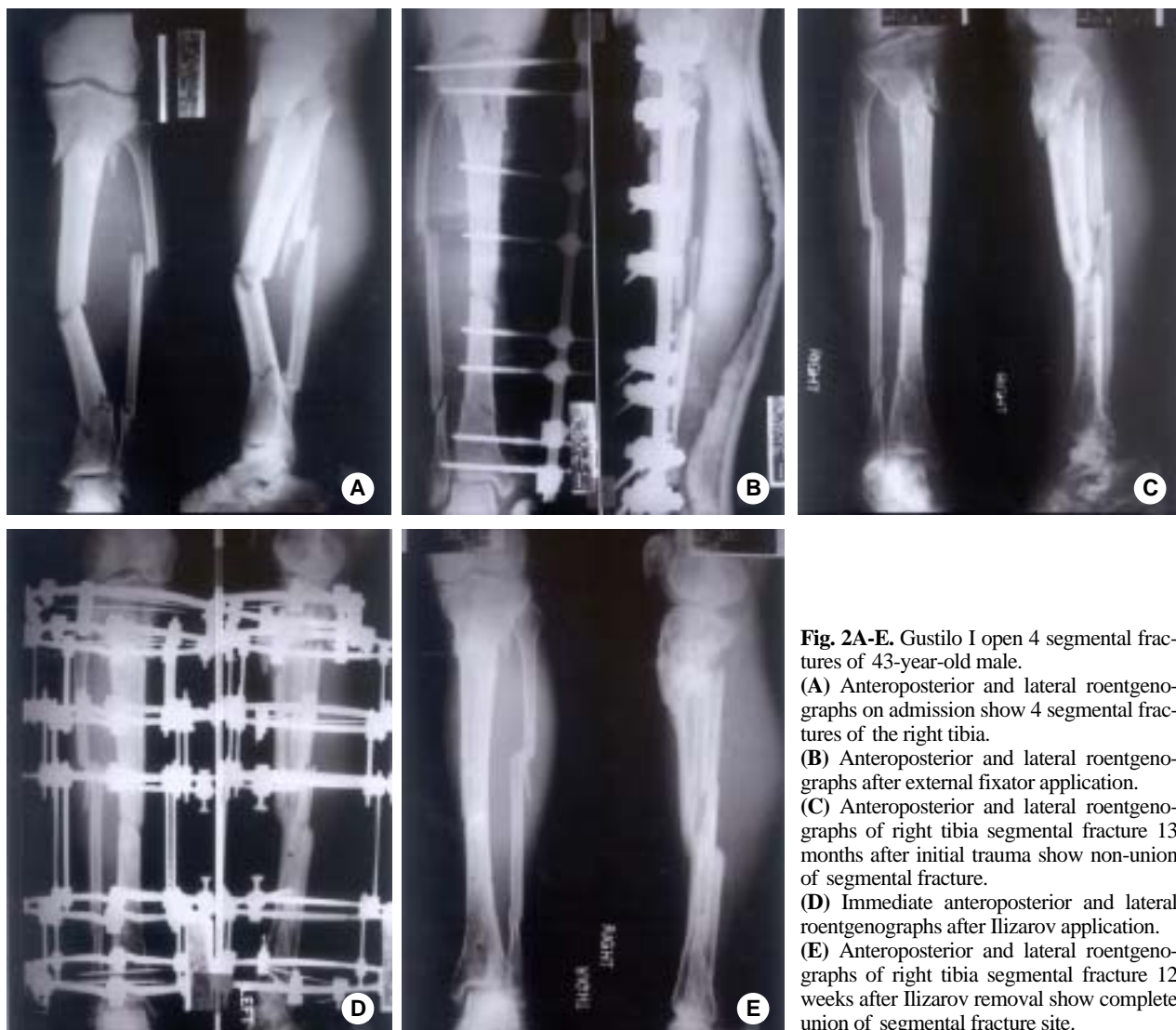


Fig. 2A-E. Gustilo I open 4 segmental fractures of 43-year-old male.

(A) Anteroposterior and lateral roentgenographs on admission show 4 segmental fractures of the right tibia.

(B) Anteroposterior and lateral roentgenographs after external fixator application.

(C) Anteroposterior and lateral roentgenographs of right tibia segmental fracture 13 months after initial trauma show non-union of segmental fracture.

(D) Immediate anteroposterior and lateral roentgenographs after Ilizarov application.

(E) Anteroposterior and lateral roentgenographs of right tibia segmental fracture 12 weeks after Ilizarov removal show complete union of segmental fracture site.

arrov , , 24 , 34.2 , 10) 6% , 가 , 가 49 , 15 , 51 5 (9.8%) 1,2,4,7~9,11,13,18,20,22,23,25~28,34~36,40) 가 , 1 Shtarker 32) Tucker 38) 16.4 , 30.4 , 100% 2 , 2 , 1 22~25 , 34,35) 20.5 , 35.4 , , Ilizarov 19) 36.5 , , 21.5 , 26.3 , , 가 32.4 .

- Ilizarov
Holbrook¹²⁾ 35% . (33%), 2 (13%), 1 (7%), 7
15 1 (7%) (47%) , 가
가 . 7 3 가
0° , 1
, 2 . 7
. Suh ³⁷⁾ 9% 4 가 0~20° ,
, 6% 0~10° . 3
1 (7%) , 1
Gustilo 3b 가 ,
, ,
. 가 ,
Gustilo 1, 2
Gustilo 3 3 1 , 1 7
, 1 6 (86%) , 34.2
. Ilizarov 가 .
Ilizarov Gustilo
3 K- , ,
45 Ilizarov . , ,
, 가 , Ilizarov
Gustilo 3b K- 가 , ,
21 Ilizarov ,
Ilizarov Ilizarov
, Ilizarov
, Ilizarov
Ilizarov .
,
가
가
³⁷⁾ Ilizarov
, 가
^{3,30)} Ilizarov 가 75% ,
가 60%
^{3,30)} 15 8
5) **A.S.A.M.I. group:** Operative principles of Ilizarov. 1st ed. Milan, William and Wilkins, 94-107, 1991.
6) **Cattaneo R, Catagni M and Johnson EE:** The treatment of infected nonunions and segmental defects of the tibia by the methods of Ilizarov. Clin Orthop, 280: 143-152, 1992.
7) **Chan KM, Leung YK, Cheng CY, et al:** The management of type III open tibial fractures. Injury, 16: 157-165, 1984.
8) **Choy WS, Lee KW, Kim HY and Hwang IS:** Treatment of unstable open tibia fractures with Ilizarov system. The Journal of the Korean Society of Fractures, 11(3): 367-575, 1998.
9) **Clase L, Heitemeyer U, Krischak G, Braun H and Heierholzer G:** Fixation technique influences osteogenesis of comminuted fractures. Clin Orthop, 365: 221-229, 1999.
10) **Collinge CA and Sanders RW:** Percutaneous plating in the lower extremity. J Am Acad Orthop Surg, 8(4): 211-216, 2000.
11) **Dagher F and Riukoz S:** Compound tibial fractures with

- bone loss treated by the Ilizarov technique. *J Bone Joint Surg Br*, 73: 316-321, 1991.
- 8) **Dendrinos GK, Kontos S and Lyritis E:** Use of the Ilizarov technique for treatment of non-union of the tibia associated with infection. *J Bone Joint Surg Am*, 77: 835-846, 1995.
 - 9) **Green SA, Jackson JM, Wall DM, Marinow H and Ishkanian J:** Management of segmental defects by the Ilizarov intercalary bone transport method. *Clin Orthop*, 280: 136-142, 1992.
 - 10) **Han SK, Lee LJ, Choi NY, Park SJ, Yoo G and Ahn HS:** Treatment of open fracture of the tibial shaft by sequential compression technique in Ilizarov device. *The Journal of the Korean Society of Fractures*, 11(4): 817-824, 1998.
 - 11) **Higgins TE, DeLuca PA and Ariyan S:** Salvage of open tibial fracture with segmental loss of tibial nerve. case report and review of the literature. *J Orthop Trauma*, 13: 380-385, 1999.
 - 12) **Hollbrook JL, Swiontkowski MF and Sanders R:** Treatment of open fractures of the tibial shaft: Ender nailing versus external fixation. A randomized prospective comparison. *J Bone and Joint Surg*, 71-A: 1231-1238, 1989.
 - 13) **Hosny G and Shawky MS:** The treatment of infected non-union of the tibia by compression-distraction techniques using the Ilizarov external fixator. *Int Orthop*, 22: 298-302, 1998.
 - 14) **Hupel TM, Aksenov SA and Schemitsch EH:** Cortical bone flow in loose and tight fitting locked undreamed intramedullary nailing: a canine segmental tibia fracture model. *J Orthop Trauma*, 12: 127-135, 1998.
 - 15) **Hupel TM, Aksenov SA and Schemitsch EH:** Effect of limited and standard reaming on cortical bone blood flow and early strength of union following segmental fracture. *J Orthop Trauma*, 12: 400-406, 1998.
 - 16) **Hupel TM, Weinberg JA, Aksenov SA and Schemitsch EH:** Effect of unreamed, limited reamed, and standard reamed intramedullary nailing on cortical bone porosity and new bone formation. *J Orthop Trauma*, 15: 18-27, 2001.
 - 17) **Jain R, Podworny N, Hupel TM, Weinberg J and Schemitsch EH:** Influence of plate design on cortical bone perfusion and fracture healing in canine segmental tibial fractures. *J Orthop Trauma*, 13: 178-186, 1999.
 - 18) **Kim H, Nam WD and Ahn KC:** Treatment of open type-III tibial shaft fractures. *The Journal of the Korean Society of Fractures*, 11(1): 192-197, 1998.
 - 19) **Ko SM, Kim MK, Lee JY, Oh IS and Kim SE:** Treatment of tibial fractures with the Ilizarov external fixator. *The Journal of the Korean Society of Fractures*, 11(4): 834-840, 1998.
 - 20) **Kumar A and Whittle AP:** Treatment of complex (Schatzker type VI) fractures of the tibial plateau with circular wire external fixation: retrospective case review. *J Orthop Trauma*, 14: 339-344, 2000.
 - 21) **Langard O and Bo O:** Segmental tibial shaft fractures. *Acta Orthop Scand*, 47: 351-357, 1976.
 - 22) **Lausen MB, Lass P and Christensen KS:** Ilizarov treatment of tibial nonunions results in 16 cases. *Acta Orthop Belg*, 66: 279-285, 2000.
 - 23) **Lerner A, Nierenberg G and Stein H:** Ilizarov external fixation in the management of bilateral, high complex blast injuries of lower extremities: a report of two cases. *J Orthop Trauma*, 12: 442-445, 1998.
 - 24) **Melis GC, Sotgiu F, Lepori M and Guido P:** Intramedullary nailing in segmental tibial fractures. *J Bone Joint Surg Am*, 63: 1310-1318, 1981.
 - 25) **Milicevic N:** Deficit (14 cm) of the tibia solved by a double sliding graft using the Ilizarov apparatus. *J Orthop Trauma*, 4: 366-369, 1990.
 - 26) **Naggar L, Chevalley F, Blanc CH and Livio JJ:** Treatment of large bone defects with the Ilizarov technique. *J Trauma*, 34: 390-393, 1993.
 - 27) **Pearson RL and Perry CR:** The Ilizarov technique in the treatment of infected tibial nonunions. *Orthop Rev*, May; 18(5): 609-613, 1989.
 - 28) **Ring D, Jupiter JB, Gan BS, Israeli R and Yaremchuk MJ:** Infected nonunion of the tibia. *Clin Orthop*, 369: 302-311, 1999.
 - 29) **Rommens PM, Coosemans W and Broos PL:** The difficult healing of segmental fractures of the tibial shaft. *Arch Orthop Trauma Surg*, 108(4): 238-242, 1989.
 - 30) **Sander DW, Galpin RD, Hosseini M and MacLeod MD:** Morbidity resulting from the treatment of tibial nonunion with the Ilizarov frame. *Can J Surg*, 45: 196-200, 2002.
 - 31) **Schemitsch EH, Kowalski MJ, Swiontkowski MF and Senft D:** Cortical bone blood flow in reamed and unreamed locked intramedullary nailing: a fractured tibia model in sheep. *J Orthop Trauma*, 8: 373-382, 1994.
 - 32) **Shtarker H, David R, Solero J, Grimberg B and Soudry M:** Treatment of open tibial fractures with primary suture and Ilizarov fixation. *Clin Orthop*, 335: 268-274, 1997.
 - 33) **Smith SR, Bronk JT and Kelly PJ:** Effect of fracture fixation on cortical bone flow. *J Orthop Res*, 8: 471-478, 1990.
 - 34) **Song HR, Cho SH, Koo KH, Jeong ST, Park YJ and KO**

- JH:** Tibial bone defects treated by internal bone transport using the Ilizarov method. *Int Orthop*, 22: 293-297, 1998.
- 35) **Song HR, Cho Sh, Koo KH, et al:** Treatment of the tibial fracture with ilizarov. *J Korean Orthop Assoc*, 29(2): 655-554, 1994.
- 36) **Song KS and Jeon SH:** Treatment for tibial fracture using the Ilizarov external fixator. *J Korean Orthop Assoc*, 33(5): 1437-1443, 1998.
- 37) **Suh JT, Nam TW and Yoo CI:** Ilizarov external fixation for severe open tibial shaft fractures in adults. *The Journal of the Korean Society of Fractures*, 12(3): 549-556, 1999.
- 38) **Tucker HL, Kendra JC and Kinnebrew TE:** Management of unstable open and closed tibial fractures using the Ilizarov method. *Clin Orthop*, 280: 125-135, 1992.
- 39) **Wu CC and Shih CH:** Segmental tibial shaft fractures treated with interlocking nailing. *J Orthop Trauma*, 7(5): 468-472, 1993.
- 40) **Wang JM, Roh KJ, Yun YH, Kim DJ, Yoo JD and Kim BG:** Treatment of the open tibia shaft fracture-a comparison: *J Korean Orthop Assoc*, 32(4): 897-904, 1997.
-