



무지 신전건에 발생한 섬유종: 증례 보고

박세진, 이인규, 조용운*

성균관대학교 의과대학 강북삼성병원 정형외과학교실, *건국대학교 의과대학 건국대학교 충주병원 정형외과학교실

Fibroma of the Extensor Digitorum Longus and Extensor Digitorum Brevis Conjoined Tendon Sheath: A Case Report

Se Jin Park, In Gyu Lee, Yongun Cho*

Department of Orthopaedic Surgery, Kangbuk Samsung Hospital, Sungkyunkwan University School of Medicine, Seoul,

*Department of Orthopaedic Surgery, Konkuk University Chungju Hospital, Konkuk University College of Medicine, Chungju, Korea

Fibroma of the tendon sheath (FTS) was initially described in 1936 by Geschickter and Copeland as a benign firm soft tissue tumor that is rare and less common than another soft tissue tumors, especially giant cell tumors (GCT) of the tendon sheath. The common distinct feature is a slow-growing least painful rare entity arising from the tendon or tendon sheath. FTS is detected mostly in the fingers, hands and wrists but less commonly in the foot. Very few cases of FTS have been described arising from a flexor tendon of the foot. This article describes a 51-year-old patient with FTS that developed in the extensor tendon of the foot, which is the only known FTS to form in this area. Heterogeneous low signal intensity in both the T1- and T2-weighted images was observed in magnetic resonance imaging. The lesion was excised completely by open surgery. Histologically, it showed randomly arranged, fibroblast-like spindle cells in dense fibrous tissue and had insufficient hemosiderin-laden macrophages that are typical for GCT.

Key Words: Fibroma, Foot

Fibroma of tendon sheath (FTS) was initially described in 1936 by Geschickter and Copeland¹⁾ as benign firm soft tissue tumor which is rare, less common than another soft tissue tumor especially giant cell tumor of the tendon sheath (GCTTS). Chung and Enzinger²⁾ in 1979 described the clinical and pathological features of 138 cases of the FTS. In cases of 138 patients, 98.6% of FTS occurred in the extremities: 86.2% in the upper extremities and 12.3% in the lower extremities; of the latter 5 were in the foot and 3 at the ankle. Kirby et al.³⁾ in 1989 described the 83 cases of the

soft tissue tumor of foot. They reported only one case of fibroma in the foot, which is the same result that very few were found in the foot. This article describes a 51-year-old patient of FTS that developed in the extensor tendon of foot, the only known FTS to form in this area. We report this case with a review of the literature because of the satisfactory results of surgical treatment of FTS. This study was approved by the Medical Research Ethics Review Committee of Kangbuk Samsung Hospital.

CASE REPORT

A 51-year-old female came in an orthopedic surgery clinic with a 2-month experience of an enlarging, painless mass along the dorsal side of second metatarsophalangeal (MTP) joint. She didn't suffer pain when she walk or sleep. She denied weight loss and re-

Received April 9, 2019 Revised June 2, 2019 Accepted June 3, 2019

Corresponding Author: Se Jin Park

Department of Orthopaedic Surgery, Kangbuk Samsung Hospital, Sungkyunkwan University School of Medicine, 29 Saemunan-ro, Jongno-gu, Seoul 03181, Korea
Tel: 82-2-2001-2168, Fax: 82-2-2001-2176, E-mail: qortn97@naver.com
ORCID: <https://orcid.org/0000-0002-3941-1857>

Financial support: None.

Conflict of interest: None.

Copyright ©2019 Korean Foot and Ankle Society. All rights reserved.

©This is an Open Access article distributed under the terms of the Creative Commons Attribution Non-Commercial License (<http://creativecommons.org/licenses/by-nc/4.0>) which permits unrestricted non-commercial use, distribution, and reproduction in any medium, provided the original work is properly cited.

ported no associated fever, chills, or night sweats. Medical history and family history of her were not cause and there wasn't a history of trauma.

Physical examination revealed 3.5 cm × 2 cm oval-shaped subcutaneous, soft and non-tender mass at the dorsal side of second MTP joint. The mass appeared to slightly move with the extensor digitorum longus (EDL) and extensor digitorum brevis (EDB) with dorsiflexion of ankle. There was no restriction of foot motions and not associated heating sense, erythema, edema. Muscle atrophy, and neurovascular examination were unremarkable. Routine laboratory data including white blood cell count, erythrocyte sedimentation rate, and C-reactive protein level were normal.

Plain radiography of the right foot showed no bony abnormal structure except soft tissue swelling. magnetic resonance imaging (MRI) of the foot revealed a well-defined 3.5 cm × 2 cm × 1.5 cm soft tissue mass external to the conjoined EDL and EDB tendon (Fig. 1). The mass was well margined and showed heterogeneous low intensity in T1- and T2-weighted scans. The lesion was indented and displaced from the dorsal surface of the second MTP joint to second metatarsal shaft. Bony erosion and bone marrow edema weren't occurred. Differential diagnosis at this time included GCTTS, Nodular fasciitis, and fibromatosis. Unfortunately, the patients didn't have contrast enhanced MRI so we couldn't exclude

malignant processes. Especially age of the patient and position of the lesion in the foot presented a malignant fibrous histiocytoma. Other malignancies, like extraosseous myxoid chondrosarcoma, synovial sarcoma, and fibrosarcoma, remained possibilities.

During general anesthesia of the patient, longitudinal incision were subsequently performed to show a well circumscribed 3.3 cm × 2 cm × 1.5 cm mass which was sturdily adherent to the dorsal side of second MTP joint capsule and conjoined tendon of EDL and EDB (Fig. 2). But no neurologic structure and vascular peduncle was found. And then excisional biopsy of the mass was subsequently performed. The gross specimen was shown as white-tan, multilobular, and rubbery mass. The histopathologic examination of the mass test showed fibrous lobulated tumor organized of dense fibrous tissue with some spindle cells (Fig. 3). The tumor was reported as FTS.

The patient left the hospital the 2 days after the operation with a simple compression dressing. After one month she returned to her normal foot activities with full range of motion. Perioperative complication wasn't occurred. At the 3 months follow-up, there was no evidence of clinical or radiological recurrence.

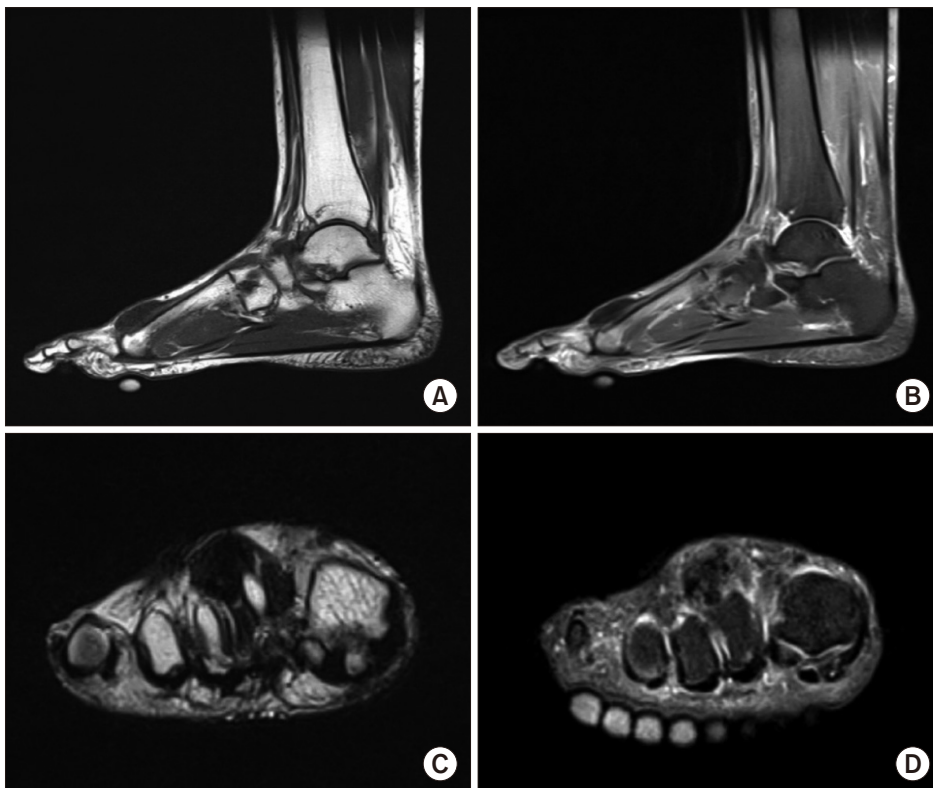

Figure 1. Magnetic resonance imaging (MRI) findings. (A) The tumor was well-defined heterogeneous low signal intensity on sagittal T1-weighted MRI image, located in the dorsal side of 2nd metatarsophalangeal (MTP) joint adjacent to the extensor digitorum longus (EDL) and extensor digitorum brevis (EDB). (B) The tumor shows same heterogeneous low signal intensity on sagittal T2-weighted MRI image. (C) Coronal T1-weighted MRI image revealing a mass firmly adherent to the dorsal side of 2nd MTP joint capsule and conjoined tendon of EDL and EDB. (D) The tumor on coronal T2-weighted MRI image shows same heterogeneous low signal intensity.

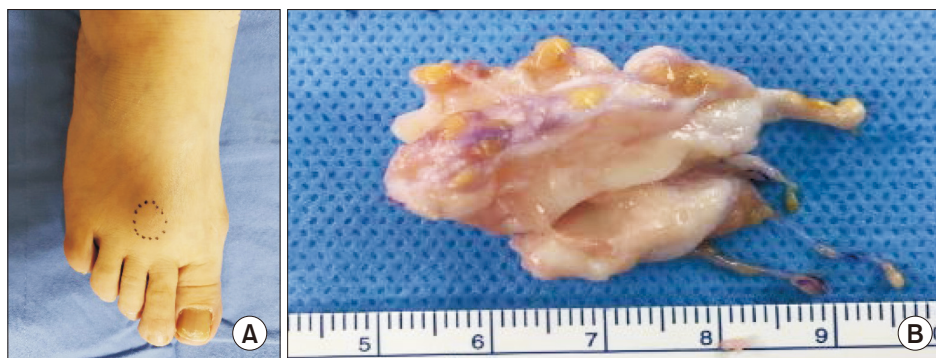


Figure 2. Gross photo. (A) Subcutaneous nodule protruded at dorsal side of 2nd metatarsophalangeal joint when patient flexion his toes. (B) At section, the mass appears to be white-tan, multilobular, and rubbery.

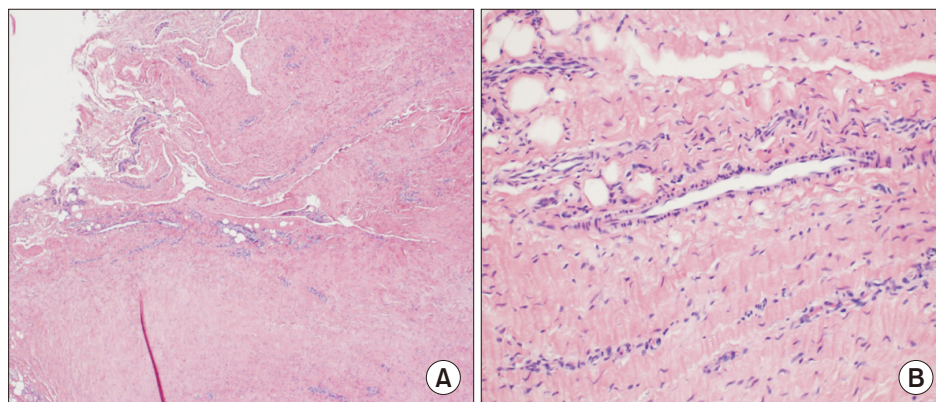


Figure 3. (A) Histologic image at low power showing a hypocellular mass of spindle cells within abundant collagenous stroma (H&E stain, $\times 40$). (B) Histologic image at high power showing spindle cells with elongated nuclei, fine chromatin, small nucleoli, and eosinophilic collagenous stroma (H&E stain, $\times 100$).

DISCUSSION

FTS of plantar side is associated with trauma history commonly. Even if some of them did not have trauma history, the tumor occurring resulted from surface of plantar area was rubbed frequently.⁴⁾ Because the extensor tendons of foot have a shorter excursion than the flexor tendons of foot,⁵⁾ there is less rub in the extensor tendons. Thus, FTS of extensor tendon is thought to be rare than flexor tendon.

Clinically, the most common presentation is slow-growing least painful rare entity arising from tendon or tendon sheath. The median age of 138 cases was 31 years, and male patients were affected about twice as many, with a ratio of 3.1:1.5.²⁾ Five cases were found around foot. In the feet, 4 of the 5 cases were removed from the plantar region.²⁾ Several other authors also described FTS around the foot, one each in the peroneus longus tendon, the flexor hallucis longus tendon, the plantar area.^{4,6)} Involvement of the conjoined tendon of EDL and EDB was first reported in our patient.

Plain radiographies of the foot are usually normal, except when large tumor mass protrudes from surrounding structures, or erosive bony changes were occurred which is greatly unusual. MRI features of fibroma are variable. T1-weighted images showed low

signal intensity and T2-weighted images showed various signal intensities and enhancement after contrast images.⁷⁾ This variation depends on the amount of hyalinization and sclerosis of the tumor.⁷⁾ Proliferation fibroblasts numbers can change T2-weighted images. Our patient's MRI also showed features alike; heterogeneous low signal intensity in both T1- and T2-weighted images. GCTTS, fibromatosis, and nodular fasciitis was considered as alternative diagnosis because they are usual in foot and also show signal intensities alike on MRI.⁷⁾ Differential diagnosis from fibromatosis is distinctly circumscribed margins of the fibroma. And the nodular fasciitis can be distinguished by character that relatively straight forward because fibroma is lobulated and not nodular.

Histologically, FTS are composed of fibroblasts' benign proliferation which are surrounded by collagen fibers, commonly including scattered axis shaped fibroblasts and narrow slit-like vascular spaces but sometimes stellate shaped fibroblast cells.^{1,2)} Scattered fibroblasts which shape is star like can exist in collagen bundles rarely and are frequently concentrated around the vascular spaces.⁸⁾ In histologically we can distinguish it and the GCTTS through fibroblastic spread. Due to similarities between some characteristic, some articles have described that FTS could have progressed from GCTTS, because of the progressive vascular damage.

The treatment of choice is local excision, with a reported recur-

rence rate of 18% to 24%. Most recurrences are owing to troubles of complete excision because of adherence to tendons and tendon sheaths.^{9,10)} So we should carefully and completely resect.

In our case we are presenting a patient who has tendon sheath fibroma which occurred in the EDL and EDB combined with tendon sheath which is unusual location. We think this is first reported case of this tumors developing in these tendon sheath, we report our case with a literature review.

REFERENCES

1. Geschickter CF, Copeland MM. *Tumors of bone*. New York: The American Journal of Cancer; 1931.
2. Chung EB, Enzinger FM. Fibroma of tendon sheath. *Cancer*. 1979;44:1945-54.
3. Kirby EJ, Shereff MJ, Lewis MM. Soft-tissue tumors and tumor-like lesions of the foot. An analysis of eighty-three cases. *J Bone Joint Surg Am*. 1989;71:621-6.
4. Lu H, Chen Q, Shen H, Shen XQ, Wu SC. Fibroma of tendon sheath in planta. *Springerplus*. 2016;5:575. doi: 10.1186/s40064-016-2260-z.
5. Hintermann B, Nigg BM, Sommer C. Foot movement and tendon excursion: an in vitro study. *Foot Ankle Int*. 1994;15:386-95. doi: 10.1177/107110079401500708.
6. Nason GJ, Baker JF, O'Toole P, Walsh A, Lui DF, O'Neill F, et al. Fibroma of the peroneus longus tendon sheath in a child: a case report. *J Orthop Surg (Hong Kong)*. 2013;21:387-90. doi: 10.1177/230949901302100326.
7. Fox MG, Kransdorf MJ, Bancroft IW, Peterson JJ, Flemming DJ. MR imaging of fibroma of the tendon sheath. *AJR Am J Roentgenol*. 2003;180:1449-53. doi: 10.2214/ajr.180.5.1801449.
8. Humphreys S, McKee PH, Fletcher CD. Fibroma of tendon sheath: a clinicopathologic study. *J Cutan Pathol*. 1986;13:331-8. doi: 10.1111/j.1600-0560.1986.tb00467.x.
9. Ciatti R, Mariani PP. Fibroma of tendon sheath located within the ankle joint capsule. *J Orthop Traumatol*. 2009;10:147-50. doi: 10.1007/s10195-009-0058-2.
10. Hashimoto H, Tsuneyoshi M, Daimaru Y, Ushijima M, Enjoji M. Fibroma of tendon sheath: a tumor of myofibroblasts. A clinicopathologic study of 18 cases. *Acta Pathol Jpn*. 1985;35:1099-107.