

# Intraosseous Epidermal Cyst of the Distal Phalanx: A Case Report

Gyu-Min Kong, Joo Yong Kim, Jung-Han Kim, Dae-Hyun Park, and Kwang Hun An

Department of Orthopaedic Surgery, Busan Paik Hospital, College of Medicine, Inje University, Busan, Korea

An intraosseous epidermal cyst is a rare benign cystic lesion. It is thought to result from congenital factors or trauma and can lead to bone destruction because the cyst develops at the soft tissue around the bone. Radiological findings of intraosseous epidermal cysts are a well-defined radiolucent lesion, with cortical expansion. It is important to differentiate an intraosseous epidermal cyst with other disease developed at distal phalanx because its clinical and radiological findings are similar. We report two rare cases of intraosseous epidermal cysts that developed at the distal phalanx.

**Key words:** intraosseous epidermal cyst, distal phalanx

Epidermal cysts are common benign tumors of the skin, but intraosseous epidermal cysts at the phalanx are rare.<sup>1,2)</sup> Congenital anomalies, trauma, and iatrogenic factors are reported as etiological causes. Phalangeal epidermal cysts commonly involve the distal phalanx. Epidermal cysts occur at periosteal soft tissue and invade the bone, resulting in circular or discoid bony destruction. Treatment involves a combination of curettage and bone grafting, and it has a good prognosis, with a low recurrence rate.<sup>1)</sup> Intraosseous epidermal cysts are too rare to be of primary concern. However, it is important to rule out other more common diseases of the distal phalanx that present with similar clinical manifestations and radiological findings. We conducted curettage and bone grafting in 2 cases of intraosseous epidermal cysts of the distal phalanx and obtained good results clinically and radiologically at 1 year follow-up.

abnormal findings in the radiological workup. There was no history of trauma or familial history of epidermal cysts. The  $0.5 \times 0.5$  cm sized mass was just below nail bed, with mild tenderness. There was no heating sensation or erythema, and the distal sensory status and the circulatory status were normal. Radiography revealed a  $9.3 \times 6.5$

## Case Report

### 1. Case 1

An 11 year-old girl attended our clinic with a mass in the left 4th finger. She detected the mass 4-5 years earlier, and it had gradually increased in size. She had visited a primary clinic for aggravating pain 2-3 months earlier and was referred to our hospital following

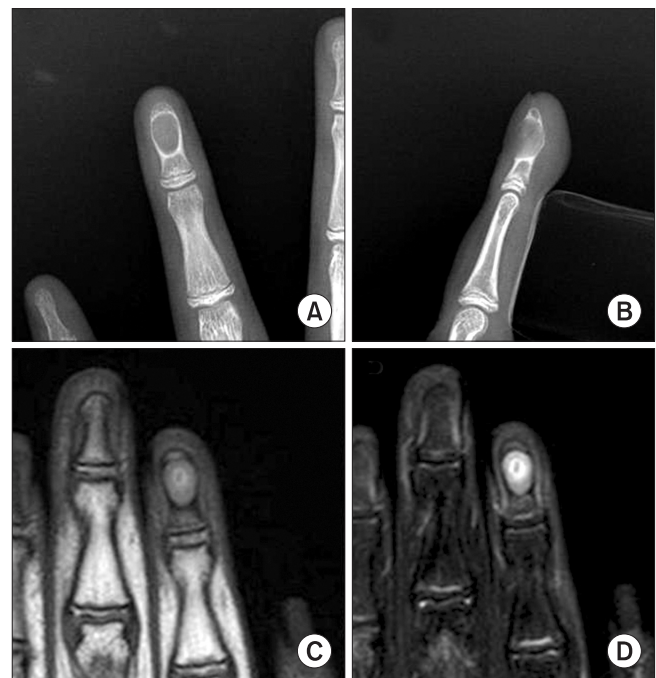


Fig. 1. (A, B) Radiographs show a round shaped radiolucent lesion with cortical expansion and thinning of left 2nd finger. (C, D) T1-weighted and T2-weighted MR images show lower and higher signal lesion at the left 2nd distal phalanx.

Received January 20, 2014 Revised May 28, 2014 Accepted June 2, 2014

Correspondence to: Joo Yong Kim

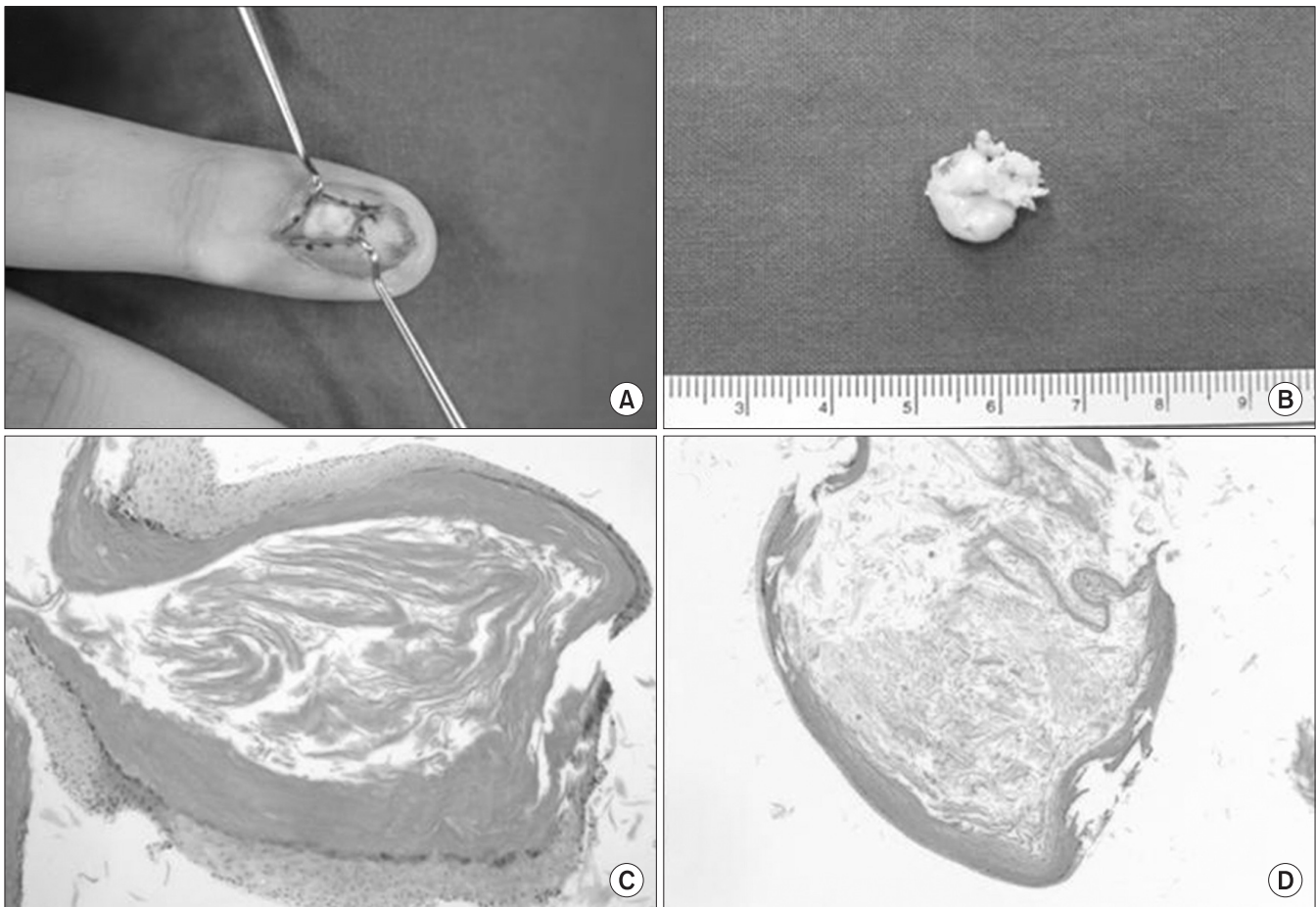
Department of Orthopaedic Surgery, Busan Paik Hospital, College of Medicine, Inje University, 75 Bokjiro, Busanjin-gu, Busan 614-735, Korea

TEL: +82-51-890-6129 FAX: +82-51-892-6619 E-mail: honaud0@hanmail.net

mm sized concentric radiolucent lesion at the distal phalanx, as well as cortical expansion and disruption of the cortical bony margin (Fig. 1A, B). On MRI, the lesion had intermediate signal intensity in T1-weighted images and high signal intensity in T2-weighted images (Fig. 1C, D). Surgery was performed for treatment and histological analysis. The 4th fingernail was extracted, and the lesion was exposed by oblique incision of the onyx. Eggshell-like thinning of the cortical bone was found intraoperatively, and a yellow-white creamy material was exposed after incision (Fig. 2A, B). The curettage was done carefully due to the thinned bony cortex, and the onyx was sutured. Based on microscopic findings, the cyst wall was composed of epithelial cells, and the cavity was full of keratinized lined material. The diagnosis was an intraosseous epidermal cyst (Fig. 2C, D). There was no complication postoperatively, no pain during 9 months of follow-up, and no recurrence.

## 2. Case 2

A 27 year-old male attended our hospital for pain at the left 2nd finger. He had undergone surgery 2 years earlier after his left 2nd fingertip had been crushed by a machine. Edema and tenderness were present at the left 2nd fingertip. A 4×4 mm sized radiolucent round-shaped lesion was found on the radiological workup, with cortical expansion and disruption of the periosteal margin (Fig. 3A, B). The lesion had intermediate signal intensity in T1-weighted images and high signal intensity in T2-weighted images (Fig. 3C, D). The lesion was exposed by oblique incision at the onyx after extracting the nail, and whitish material was exposed. Curettage was done, and the onyx was sutured. After 14 months of follow-up, the osteogenesis had not completely resolved (Fig. 4A, B) but there was no pain. Although there was nail deformity, the patient was satisfied (Fig. 4C).



**Fig. 2.** (A, B) Intraoperatively, the bone cortex was as thin as an egg shell; when the lesion was incised, yellow-tan cheese like creamy material was released, and a thick layer of tissue was peeled from within the cavity of the lesion. Curettage of the lesion was performed. (C, D) Cyst is lined by cornified epithelium, has a distinct granular layer, and contains lamellated keratin without calcification. Although some of these cysts result from traumatic inclusion for the epidermis, the majority probably arise from cystic dilation of the infundibular portion of hair follicles ( $\times 100$ ), ( $\times 40$ ).

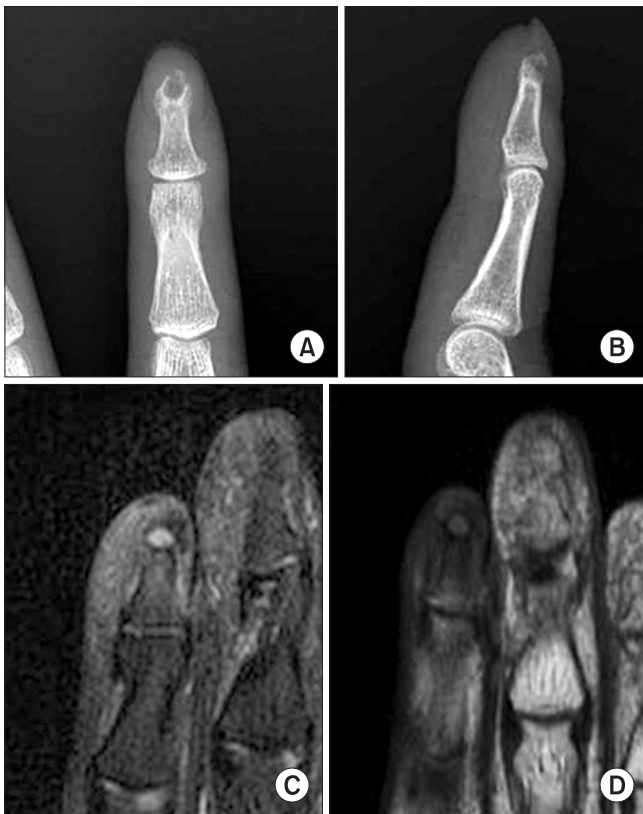

Fig. 3. (A, B) Radiographs show a round shaped radiolucent lesion with cortical expansion and thinning of left 4th finger. (C, D) T1-weighted and T2-weighted MR images show lower and higher signal lesion at the left 4th distal phalanx.

## Discussion

Epidermal cysts, also called epidermal inclusion cysts, are common, but intraosseous epidermal cysts are rare. Epidermal cysts usually invade the skull and phalangeal bone. They occur frequently in people aged 20 to 40 years.<sup>1-3)</sup> According to some studies, epidermal cells implanted in bony tissue after trauma or surgery may give rise to these cysts.<sup>2)</sup> They have also been attributed to the expansion of populations of embryonic cells that exist congenitally in bone.<sup>2,4)</sup> Symptoms of epidermal cysts are a slightly enlarged finger, with a rubbery to firm texture, often with tenderness. Most epidermal cysts do not invade the joint or limit the range of motion.<sup>1,2)</sup> Epidermal cysts at the distal phalanx are the most common site in the hand. Such cysts show up as a concentric pattern in bone radiographs. Other characteristics include an osteo-destructive lesion in the center, an expanded cortex, and a radiolucent lesion with well-defined margins. Gross findings intraoperatively in the cyst, the cystic cavity is found. It has the internal lining which is easily separated from the surrounding bone. The cystic cavity is sometimes empty, but it is

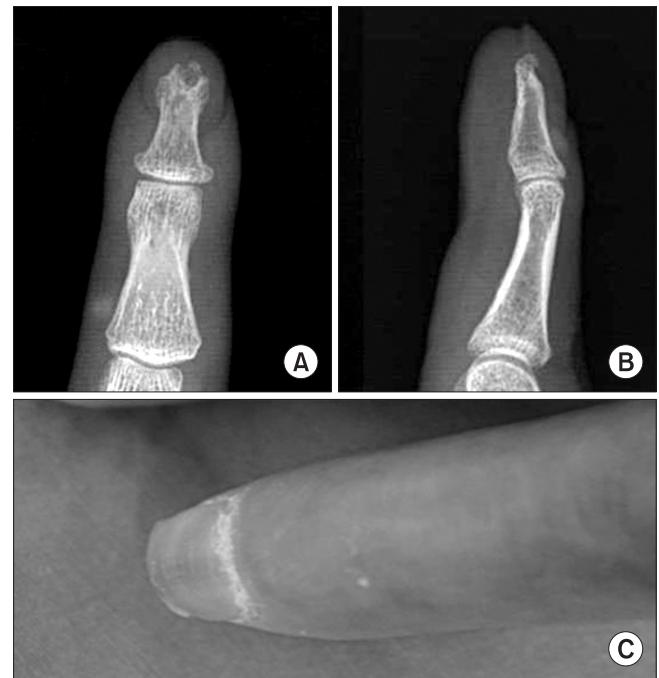

Fig. 4. (A, B) Anteroposterior and lateral radiographs 14 months after curettage show diminished radiolucent lesion and progression of union compared with previous radiographs. (C) Gross finding shows nail deformity 14 months after operation.

usually filled with a yellowish or yellow-white cheese-like material. Epidermal cysts are composed of stratified epithelium and intra-cyst material containing desquamated keratin, which can be examined using a polar microscope. Most intraosseous epidermal cysts are benign in nature. Transformation into a malignant lesion has been reported rarely.<sup>5)</sup>

The treatment of epidermal cysts is usually curettage, cystectomy, and bone grafting, and good prognosis can be expected. Histological examination is necessary for confirming the diagnosis and is also important for preventing recurrence.<sup>1,3)</sup>

The differential diagnosis should include enchondromas, glomus tumors, osteoid osteomas, giant cell tumors, metastatic tumors, and osteomyelitis.<sup>1,2,6,7)</sup> Most enchondromas occur in the hand, especially at the proximal phalangeal bone, and they are rare at the distal phalangeal bone.<sup>8,9)</sup> Enchondromas have a clear margin, in addition to an expanded radiolucent area and expansion and thinning of the cortex surrounding the lesion. These radiological findings are hard to distinguish from those of intraosseous epidermal cysts.<sup>10)</sup> One diagnostic indicator is that lesions associated with enchondromas usually contain a calcified portion, whereas those associated with intraosseous epidermal cysts do not. In addition, whitish or blue-whitish fragile tissue is seen in enchondroma intraoperatively, whereas intraosseous

epidermal cysts are filled with yellow–white caseous material, and a membrane surrounds the cyst. Glomus tumors are common at subungual sites, and stabbing pain is the chief complaint. Usually, there are no specific radiological findings indicative of a glomus tumor, but an indented lesion is often found under the nail. Patients with osteoid osteoma experience pain, which is aggravated at night. Characteristic radiological findings are a nidus that has round– or oval-shaped, radiolucent and centrally located in cortex of the long bone. Giant cell tumors are common at the metacarpal bone and proximal phalangeal bone, and they show rapid progression. Radiological findings are a poorly margined osteolytic lesion. In the hand, they are associated with cortical expansion and destruction and extension into the soft tissue.

Considering the differential diagnoses of epidermal cysts, an intraosseous epidermal cyst cannot be suspected based on an expanding osteolytic lesion alone. Other bone tumors and diseases should be differentiated through clinical and radiological examination. If an intraosseous epidermal cyst is confirmed by histology, optimal treatment can be easily followed.

## References

1. Hinrichs RA. Epidermoid cyst of the terminal phalanx of the hand. Case report and brief review. *JAMA*. 1965;194:1253-4.
2. Yang R, Chang MC, Liu Y, Lo WH. Intraosseous epidermoid cyst in distal phalanx of finger: a case reports. *Zhonghua Yi Xue Za Zhi*. 1997;60:109-12.
3. Takigawa K. Chondroma of the bones of the hand. A review of 110 cases. *J Bone Joint Surg Am*. 1971;53:1591-600.
4. Chakrabarti I, Watson JD, Dorrance H. Skin tumours of the hand: A 10-year review. *J Hand Surg Br*. 1993;18:484-6.
5. Adachi H, Yoshida H, Yumoto T, et al. Intraosseous epidermal cyst of the sacrum. A case report. *Acta Pathol Jpn*. 1988;38:1561-4.
6. Johnston AD. Aneurysmal bone cyst of the hand. *Hand Clin*. 1987;3:299-310.
7. Katz MA, Dormans JP, Uri AK. Aneurysmal bone cyst involving the distal phalanx of a child. *Orthopedics*. 1997;20:463-6.
8. Bogumill GP, Sullivan DJ, Baker GI. Tumors of the hand. *Clin Orthop Relat Res*. 1975;108:214-22.
9. Schajowicz F, Aiello CL, Slullitel I. Cystic and pseudocystic lesions of the terminal phalanx with special reference to the epidermoid cysts. *Clin Orthop Relat Res*. 1970;68:84-92.
10. Svenes JK, Halleraker B. Epidermal bone cyst of the finger. A case report. *Acta Orthop Scand*. 1977;48:29-31.

## 원위 지골에서 발생한 골내 표피낭종: 증례 보고

공규민 • 김주용 • 김정한 • 박대현 • 안광훈

인제대학교 의과대학 부산백병원 정형외과학교실

골내 표피낭종은 드문 양성 양성 병변이다. 이는 선천적인 요인이나 외상의 결과로 사료되며, 골 주변의 연부 조직에서 발생하기 때문에 골 파괴를 유발할 수 있다. 골내 표피낭종의 단순방사선 소견은 피질골의 팽대를 동반한, 경계가 명확한 방사선 투과성 병변이다. 임상적, 방사선학적 소견이 유사하기 때문에 원위 지골에서 발생한 다른 질환들과 골내 표피낭종을 감별하는 것이 중요하다. 저자들은 원위 지골에서 발생한 골내 표피낭종의 2개의 드문 증례를 보고하고자 한다.

**색인단어:** 골내 표피낭종, 원위 지골

접수일 2014년 1월 20일 심사수정일 2014년 5월 28일 게재확정일 2014년 6월 2일

교신저자 김주용

부산시 부산진구 복지로 75, 인제대학교 의과대학 부산백병원 정형외과학교실

TEL 051-890-6129, FAX 051-892-6619, E-mail honaud0@hanmail.net