

# Extragonadal Intraabdominal Mixed Germ Cell Tumor with Liver Metastasis: Successful Treatment and Long-term Follow-up

Jinyoung Park, M.D.

*Department of Pediatric Surgery, School of Medicine, Kyungpook National University,  
Taegu, Korea*

## INTRODUCTION

Extragonadal germ cell tumors (GCTs) are thought to derive from primordial germ cell precursors that become sequestered during embryologic migration and survive in ectopic locations<sup>1,2</sup>. Their anatomic location can vary widely, with tumors occurring along the body midline, following the course of embryonal germ cells. Preferred sites include the mediastinum, the sacrococcygeal and pineal regions, the neck, and the retroperitoneum<sup>3-6</sup>. Intraabdominally located extragonadal GCTs are extremely rare, with only a few cases reported in the English literature<sup>1-3,5-10</sup>. We describe here

an 18-month-old girl with an intraabdominal mixed GCT and liver metastasis, who was treated by surgical excision and postoperative chemotherapy.

## CASE REPORT

An 18-month-old girl was transferred to our hospital due to a large left upper abdominal mass, found incidentally while bathing. She had no associated complaints. On physical examination, an approximately 11 cm well-defined, firm, movable globular mass was palpated in the left upper quadrant of her abdomen. Her serum  $\alpha$ -fetoprotein (AFP) concentration was elevated to 950 ng/mL (normal, <8 ng/mL), whereas other biochemical parameters and tumor markers, including carbohydrate antigen (CA) 125 and  $\beta$ -human chorionic gonadotropin ( $\beta$ -hCG) were within normal limits. Abdominal ultrasonography (USG)

Submission : 13 / 5 / 6 Acceptance : 13 / 6 / 17

**Correspondence : Jinyoung Park, M.D.**

*Department of Pediatric Surgery, Kyungpook National University Hospital, 50 Samduk-Dong, 2-Ga, Jung-Gu, Taegu 700-721, Korea*

Tel : 053)420-5612, Fax : 053)421-0510

E-mail: kpnugs@knu.ac.kr

<http://dx.doi.org/10.13029/jkaps.2013.19.1.25>

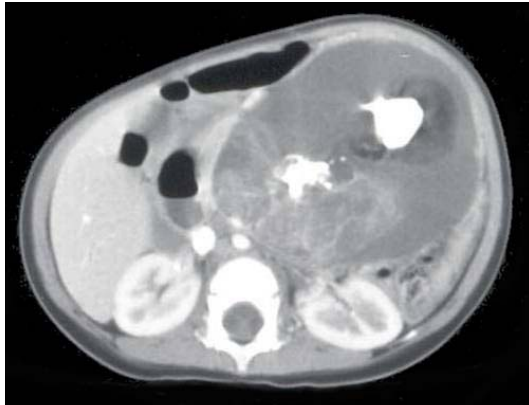


Fig. 1. Abdominal CT scan in our patient, showing a 12 x 8 cm, well-demarcated, cystic mass with calcification and solid and fat components in the left upper quadrant of the abdomen.

showed a huge cystic mass with multiseptation, calcification, and solid components in the left upper quadrant of the abdomen. Abdominal computed tomography (CT) scanning revealed a 12 x 8

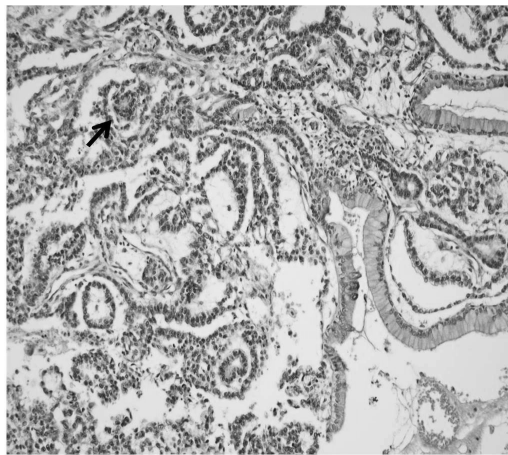


Fig. 3. Microscopic examination, showing that the primary tumor was composed primarily of endodermal sinus tumor components. A loose reticular pattern and rounded papillary processes with central capillary, "Schiller-Duval bodies" were also observed (arrow). The section from the liver shows a metastatic germ cell tumor, composed primarily of an endodermal sinus tumor component (H & E, x 200 magnification).

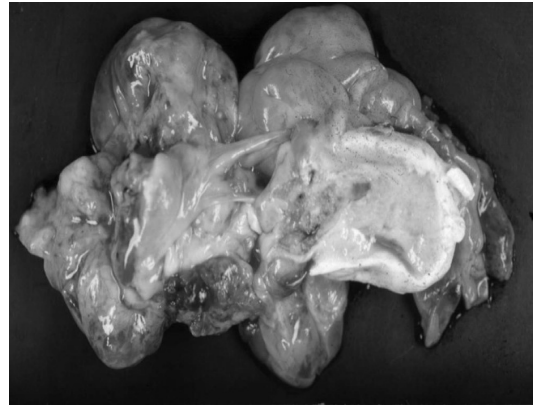


Fig. 2. Gross appearance of the resected tumor. The tumor appears as a whitish to gray globular solid mass, measuring 10 x 9 cm. The cut surface shows semisolid grayish material and cartilaginous tissue.

cm, well demarcated, cystic mass with calcification and solid and fat components in the left upper quadrant of the patient's abdomen, along with a 1 cm, well-defined, ovoid, low density nodule in segment IV of her liver (Fig 1). An explorative laparotomy revealed a 9 x 8 cm, globular encapsulated mass, located between the greater omentum and transverse mesocolon, and a 1 cm, ovoid nodule in segment IV of the liver. The mass showed no evidence of invasion of adjacent organs. Both ovaries were normal at the time of surgery. The mass was completely excised surgically, and the hepatic lesion underwent wedge resection. Grossly, the tumor was a 10 x 9 cm, whitish to gray, globular solid mass (Fig. 2); sectioning revealed semisolid grayish material and cartilaginous tissue. Pathologic examination revealed a mixed

Table 1. Reported 9 Pediatric Cases of Primary Extragenadal Intraabdominal Germ Cell Tumors in the English Literature

Study	Sex/age	Site	Histology	Treatment	Outcome
Tangour-Bouaicha et al (7)	F/16 yr	Transverse mesocolon + hepatic nodule	Yolk sac tumor	Resection + Adjuvant chemotherapy	Alive
Xinghui et al (8)	M/3 yr	Omentum	Endodermal sinus tumor	Chemotherapy + Resection	?
Billmire et al (2)	F/?	Liver + pulmonary metastasis	Choriocarcinoma	?	?
	??	Liver	Choriocarcinoma	?	?
	??	Liver	?	?	?
	??	Jejunum	?	?	?
Verma et al (3)	M/2 yr	Liver	Mixed (Yolk sac tumor + Mature teratoma)	Left lobectomy + Adjuvant chemotherapy	Died
Jones et al (5)	M/2 yr	Jejunal mesentery	Yolk sac tumor	Resection + Adjuvant chemotherapy	Alive
	M/17 yr	Transverse mesocolon	Yolk sac tumor	Resection + Adjuvant chemotherapy	Alive

malignant GCT made of two components, a mainly endodermal sinus tumor and a small mature teratoma. We also observed a loose reticular pattern and rounded papillary processes with central capillary, Schiller-Duval bodies. The tumor was immunohistochemically positive for AFP. The resected hepatic specimen was a metastasis of the mixed GCT and was histologically identical to that component of the primary tumor (Fig 3). Post-operatively, the patient received five courses of BEP chemotherapy, consisting of 15 mg/m<sup>2</sup> of bleomycin, 100 mg/m<sup>2</sup> of etoposide, and 40 mg/m<sup>2</sup> of cisplatin. Serum AFP concentration returned to normal 3 months after the operation. The patient was followed up annually with

measurement of serum AFP concentration and abdominal CT scans. At present, more than 10 years after surgery, this patient is alive and well, with no evidence of tumor recurrence.

## DISCUSSION

Extragenadal GCTs are defined as germ cell tumors displaying a histology associated with gonadal origin, but located outside the gonads. Extragenadal GCTs are relatively uncommon, accounting for fewer than 5% of all GCTs<sup>2</sup>. Their pathologic subtypes vary widely and include mature and immature teratomas, seminomas, yolk sac tumors, embryonal carcinomas, choriocarcinomas, and mixed

GCTs. Mixed GCTs, which are rare, include components of at least two malignant GCTs.

GCTs are thought to originate from primordial germ cells, which migrate to the primitive gonadal glands in the urogenital ridge<sup>1</sup>. The histogenesis of extragonadal GCTs, however, remains unclear, although several hypotheses have been proposed based on embryologic and histopathologic considerations<sup>10</sup>. The first hypothesis states that extragonadal GCTs derive from the aberrant differentiation of somatic cells. A more persuasive hypothesis states that extragonadal GCTs develop from primordial germ cell precursors, with the latter being misplaced or arrested during their embryologic migration to the gonads, resulting in their survival in ectopic locations. According to this hypothesis, the tumor observed in our patient may derive from the arrest of germ cell migration through the bowel wall, mesentery or omentum. The third hypothesis states that metastasis from the occult focus of testicular or ovarian gonadal GCTs may give rise to extragonadal GCTs; however, both ovaries were normal in our patient, and thorough examination has excluded this possibility.

The anatomic locations of extragonadal GCTs vary widely. These tumors have been found along the median line of the human body, which derives from the

embryonic germ cell ridge. Preferred sites include the mediastinum, the sacrococcygeal and pineal regions, the neck, the intracranial region, the retroperitoneum, the liver, and the pelvis. Although pelvic and/or retroperitoneal extension of a sacrococcygeal tumor is not unusual, an exclusively retroperitoneal or abdominal location is uncommon. Intraabdominally located extragonadal GCTs are extremely rare, with only 9 pediatric patients with these tumors have been reported in the English-language literature before the present report (Table 1), and long-term follow up of these patients was lacking. Due to the large size of the tumor in our patient, a precise site of origin could not be determined. Nevertheless, our case appears to be extraordinary due to the rare location of the primary tumor, the presence of a metastatic site in the liver at the time of surgery, and the long-term survival of our patient.

Extragonadal GCTs have a female preponderance. Most tumors are diagnosed at an advanced stage and are locally unresectable with metastases to the lungs or liver<sup>2</sup>. The advanced stage at diagnosis is possibly due to the retroperitoneal location of these tumors and the lack of obstructive symptoms, despite large tumor size.

Most intraabdominal and retroperitoneal extragonadal GCTs derive from metastases,

usually from primary testicular and ovarian tumors. It is difficult to distinguish morphologically between primary and metastatic GCTs, making clinical correlation decisive in these patients.

Mixed GCTs secrete AFP and/or  $\beta$ -hCG, depending on the components of the tumor. In our patient, serum AFP, a hallmark of endodermal sinus tumors, was elevated.

Management of mixed GCTs is geared toward the most malignant components. The preferred treatment for children with endodermal sinus tumor is complete surgical resection, with adjuvant chemotherapy evaluated on an individual basis. Surgical resection is determined by the extent of disease at the time of diagnosis. In most patients, however, it is difficult to remove the lesion completely due to its diffuse bulky extension. In these patients, a limited biopsy for tissue diagnosis, followed by chemotherapy and resection of the residual mass, has been recommended. Adjuvant chemotherapy after surgery has increased the survival rate of patients with GCTs<sup>10</sup>. Although several chemotherapeutic regimens have been employed, the best results were achieved using BEP, consisting of bleomycin, etoposide, and either standard or high dose cisplatin.

Although the rarity of extragonadal GCTs make it difficult to predict the long-term outcomes in patients with these

tumors, children with malignant germ cell tumors arising in the abdomen and retroperitoneum, including our patient, have an excellent prognosis, despite the advanced stage of disease at diagnosis<sup>2</sup>.

Our findings suggest that surgical resection and aggressive combination chemotherapy could improve the survival of pediatric patients with extragonadal mixed GCTs.

## REFERENCES

1. Theegarten D, Reinacher A, Graeven U, Philippou S: *Mixed malignant germ cell tumour of the liver*. Virchows Arch 433: 93-6, 1998
2. Billmire D, Vinocur C, Rescorla F, Colombani P, London W, Giller R, Cushing B, Lauer S, Cullen J, Davis M, Hawkins E: *Malignant retroperitoneal and abdominal germ cell tumors: an intergroup study*. J Pediatr Surg 38:315-8, 2003
3. Verma M, Agarwal S, Mohta A: *Primary mixed germ cell tumour of the liver--a case report*. Indian J Pathol Microbiol 46:658-9, 2003
4. Lack EE, Travis WD, Welch KJ: *Retroperitoneal germ cell tumors in childhood. A clinical and pathologic study of 11 cases*. Cancer 56:602-8, 1985
5. Jones MA, Clement PB, Young RH: *Primary yolk sac tumors of the mesentery. A report of two cases*. Am J Clin Pathol 101:42-7, 1994
6. Xu AM, Gong SJ, Song WH, Li XW, Pan CH, Zhu JJ, Wu MC: *Primary mixed germ cell tumor of the liver with*

- sarcomatous components*. World J Gastroenterol 16:652-6, 2010
7. Tangour-Bouaicha M, Bel Haj Salah M, Ben Brahim E, Ben Othmène M, Douggaz A, Sassi S, Chatti-Dey S: *Primary peritoneal yolk sac tumour. A case report*. Ann Pathol 30:378-81, 2010
  8. Xinghui Y, Jing H, Mingju L, Weizhong G: *Endodermal sinus tumour of the omentum in a child*. Pediatr Radiol 34:985-7, 2004
  9. Kim SW, Park JH, Lim MC, Park JY, Yoo CW, Park SY: *Primary yolk sac tumor of the omentum: a case report and review of the literature*. Arch Gynecol Obstet 279:189-92, 2008
  10. Park NH, Ryu SY, Park IA, Kang SB, Lee HP: *Primary endodermal sinus tumor of the omentum*. Gynecol Oncol 72:427-30, 1999

## 간 전이를 동반한 복강 내 성선 외 혼합 생식세포종양: 성공적인 치료 및 장기간 추적관찰

경북대학교 의학전문대학원 외과학교실

박진영

성선 외 생식세포종양은 비교적 드물어 모든 생식세포종양의 5% 미만을 차지한다. 주로 천미부 생식세포종양이 골반부나 후복막으로 확장된 경우가 대부분이며, 후복막이나 복강 내에 발생하는 생식세포종양은 매우 드물다. 저자는 복부 종괴를 주소로 내원한 18개월 된 여아에서 간 전이를 동반한 복강 내 혼합 생식세포종양을 치료하였다. 복부 초음파 및 전산화 단층촬영에서 복부 좌상 사분역에 석회화, 고형 및 지방 성분을 포함하고 있는 낭성 종괴와 간에 1cm 크기의 결절이 관찰되었다. 종괴는 개복 후 제거되었으며, 병리조직학적으로 대부분의 내배엽성 종양과 적은 성숙 기형종으로 구성된 혼합 생식세포종양으로 진단되었으며, 간의 전이병변도 동일하게 진단되었다. 수술 후 항암화학요법을 시행하였으며, 환자는 현재 수술 후 10년이 경과하였으나 재발의 소견은 없다.

(J Kor Assoc Pediatr Surg 19(1):25~31), 2013.

Index Words : *Extragenadal germ cell tumors, Endodermal sinus tumor, Mature teratoma, Girl*

---

교신저자 : 박진영

(700-721) 대구광역시 중구 삼덕동 2가 50번지, 경북대학병원 소아외과

Tel : 053)420-5612, Fax : 053)421-0510

E-mail: kpnugs@knu.ac.kr