

The Effect of Calcium Sulfate on the Periodontal Healing of 2-Wall Intrabony Defects in Dogs

Dong-Hoon Choi, Seong-Ho Choi, Kyoo-Sung Cho, Jung-Kiu Chai,
Chong-Kwan Kim, Ik-Sang Moon

Department of Periodontology, College of Dentistry, Yonsei University.
Research Institute for Periodontal Regeneration

I. INTRODUCTION

There have been numerous bone graft materials used in periodontics, in an attempt to reach the main goal of periodontal therapy, i.e. the regeneration of periodontal tissue lost due to destructive periodontal diseases. Autogenous bone grafts, with their ability to retain cell viability and a high potential of revascularization as well as low disease transmission, have been widely favored¹⁾. However, autogenous bone grafts generally require secondary surgical sites, and have limitations in the amount of grafts that can be procured. A search for the allografts and synthetic bone substitutes that can match the clinical success of autogenous bone grafts without the limitations inherent in the autogenous grafts has been going on for decades. Some of the materials studied include plaster of Paris^{2, 3)}, hydroxyapatite^{4, 5)}, calcium carbonate⁶⁾, and decalcified freeze-dried bone⁷⁾, to name a few.

The hemihydrate of calcium sulfate, also known as plaster of Paris, is prepared by

heating gypsum⁸⁾. When the dry powder is mixed with water, calcium sulfate hardens to form a solid mass of crystals. Initially, medical use of calcium sulfate was limited to a cast which immobilize the injured limb or incorporation in bandages and splints. However, there was a report in 1892 by Dressman as described by Peltier²⁾, where bone cavities were filled with plaster of Paris and later found to be filled with solid bone. Since then, the use of calcium sulfate in animals and in human orthopedic and dental bone defects has been reported in numerous publications. These reports generally agree that the plaster of Paris does not induce inflammatory reaction more than what is present before the grafting⁸⁾, and the grafted area is histologically normal. A number of animal studies using calcium sulfate suggest that calcium sulfate does not inhibit the osteoblast activities, and may provide conducting matrix for ingrowth of blood vessels and osteogenic cells. However, Shaffer & App³⁾ in 1971 reported that no new bone formation was found in the intrabony defects

grafted with plaster of Paris.

Frame et al.¹⁾ in 1987 suggested the possibility of plaster of Paris being used as a vehicle that can facilitate the handling of the graft particles such as hydroxyapatite. Recently, Sottosanti^{9, 10, 11)} reported clinical cases where calcium sulfate was used as a binder/filler and a protective barrier material for demineralized freeze-dried bone grafts. He suggests that the osteoinductive potential of BMP contained in decalcified freeze-dried bone as Urist et al.^{12), 13), 14)} reported, can be enhanced by the presence of calcium sulfate as a suitable delivery system, as suggested by Yamazaki et al.¹³⁾

Kim et al.¹⁶⁾ in 1994 studied the effects of calcium sulfate either grafted alone or in combination with demineralized freeze-dried bone in 3-wall intrabony defects of dogs. The results of that study show that significant differences exist between calcium sulfate treated sites and control sites in terms of new cementum and new bone formations.

The purpose of this study is to evaluate the regenerative potential of calcium sulfate in the treatment of 2-wall intrabony defects as compared to the flap procedure alone.

II. MATERIALS & METHODS

1. Animal & graft material selection

Four adult mongrel dogs, approximately 12 months old, weighing approximately 15kg were selected. The animals had an intact dentition and healthy periodontium. Medical-grade calcium sulfate*(Plaster of Paris) which has been sterilized in a dry-heat oven at 325F for 90 minutes was used as a graft

material.

2. Experimental design

The control sites were treated with flap procedures only, and the test sites were treated with flap procedures and calcium sulfate grafting in surgically created intrabony defects.

3. Surgical protocol

The surgical procedures were performed under intravenous sodium pentobarbital anesthesia # (30mg/kg) and infiltration anesthesia with 2% Lidocaine HCl in the surgical sites. The animals were given lactated Ringer's solution intravenously. Upper 1st and 2nd incisors have been previously extracted, and the extraction sites were allowed to heal for 2 months. Buccal and lingual mucoperiosteal flaps were elevated, and the box shaped trough-like 2-wall intrabony defects of 4mm in depth and 4mm in width were surgically created with burs in the mesial aspects of upper and lower 3rd incisors. Following a thorough root planing of surgically exposed root surfaces, the base of the defects were marked on the root surfaces with 1/4 round bur for the later reference. In the test sites, calcium sulfate powder was mixed with sterile water, and the mixture was placed in the defects. The flaps were then repositioned and sutured. The sutures were removed after 7 to 10 days.

4. Postsurgical management

Postsurgical management includes:

administration of broad spectrum antibiotic[§] intramuscularly, a soft diet, and a daily topical application of 2% chlorhexidine solution[@] during the healing period.

5. Histological analysis

Postoperative healing was uneventful. Animals were sacrificed 8 weeks after the surgical procedure by intravenous injection of concentrated sodium pentobarbital. Block sections including the surgical sites were removed , rinsed in saline and fixed in 10% buffered formalin for 10 days. Following the rinsing with water, the block sections were decalcified in 5% formic acid for 14 days, and

embedded in paraffin. Serial sections, 5μm thick, were made in a mesio-distal direction, and four sections from each block were stained with hematoxylin/eosin. The stained sections were examined under a light microscope for a histologic analysis.

For the histometric analysis, cementoenamel junction(CEJ), gingival margin(GM) and the base of the reference notch(BN) were used as the reference landmarks(Figure 1). The definitions of the parameters used in the experiment are as follows:

* Gingival recession(GR) : The distance from CEJ to the gingival margin(GM), with GM apical to CEJ constituting a positive score.

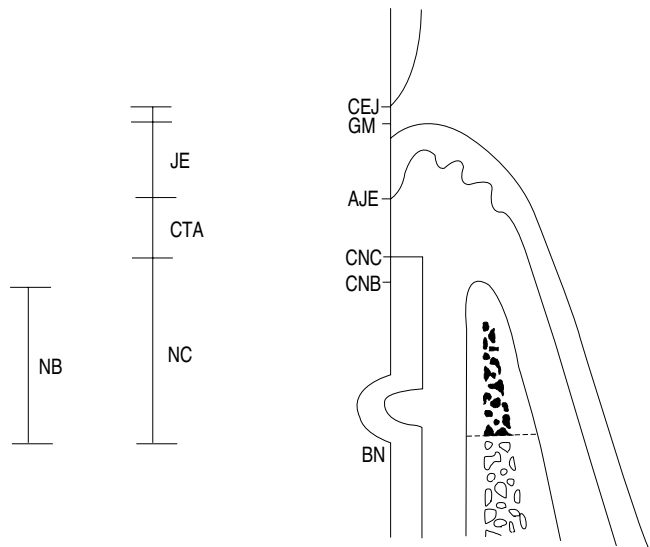


Figure 1 A schematic diagram depicting the experiment design, landmarks and the parameters used in histomorphometric analysis

CEJ, cemento-enamel junction; GM, gingival margin; BN, base of the reference notch; AJE, apical extent of junctional epithelium; CNC, coronal extent of new cementum; CNB, coronal extent of new bone.

* Calcium sulfate, Edgemark Co., U.S.A.
Entobar[®] sodium pentobarbital 100mg/2ml, Hanlim Pharm, Co., Korea.
§ Tetracycline HCl, Glaxo Pharm, Co., Korea
@ Hexamedin[®] 2% chlorhexidine, Bukwang Pharm, Co., Korea.

- * Junctional epithelium(JE): The distance from GM to the apical extension of the junctional epithelium(AJE).
- * Connective tissue adhesion(CTA): The distance from the apical extension of the junctional epithelium(AJE) to the coronal extension of the newly formed cementum.
- * New cementum(NC): The distance from the base of the reference notch(BN) to the coronal extension of the newly formed cementum(CNC).
- * New bone(NB): The distance from the base of the reference notch to the coronal extension of the newly formed alveolar bone(CNB).

6. Statistical analysis

Histometric recordings from 4 sections in each block were used to calculate the mean scores, and the data from four blocks in each group was statistically analyzed with Mann-

Whitney test.

III. RESULTS

1. Histologic observations

Apical migration of junctional epithelium is generally limited in both control and the test group. New cementum was observed in both groups, but the coronal extension of new cementum was generally greater in calcium sulfate treated specimens compared to control sites. Greater amount of new bone formation was observed in the test sites compared to the control sites. Connective tissue fibers were seen running parallel to root surfaces in most of the control sites, and in various arrangements in the test sites. Signs of root resorption was generally limited in both groups, but they were more frequently observed in the test specimens. None of the specimens showed any significant degree of

Table 1 Histometric analysis

	Control		Experimental	
	Median Mean	Range SD	Median Median	Range SD
Gingival recession	0,20	0,15	0,27	0,18
	0,21	0,09	0,25	0,10
Junctional epithelium	2,28	1,16	0,51*	0,50
	2,29	0,47	0,50	0,22
Bone	1,02	0,45	2,30*	1,10
	1,02	0,21	2,27	0,45
Cementum	1,33	0,98	2,59*	0,76
	1,17	0,45	2,55	0,34
Connective tissue adhesion	0,50	0,46	1,14	1,29
	0,53	0,20	1,16	0,65

* Statistically significant difference from the control(P<0,05).

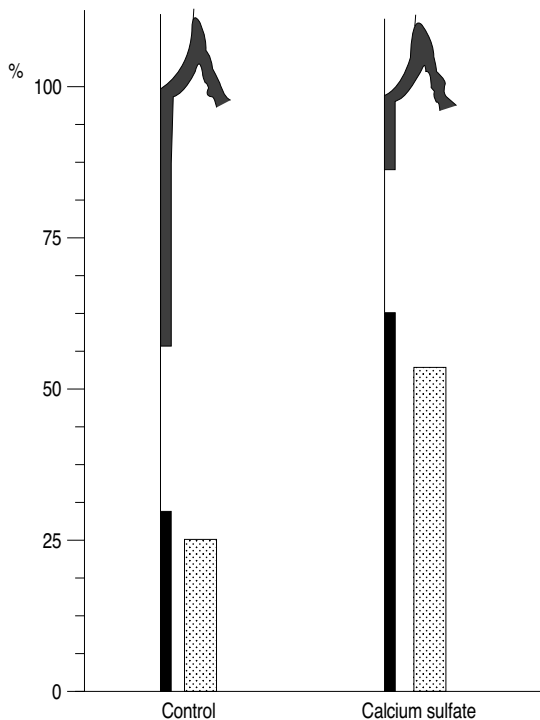


Figure 2 Periodontal healing illustrated in percent of the defect height

inflammatory cell infiltrations.

2. Histometric analysis

Apical extent of junctional epithelium from CEJ was 2.28mm in the control group, and 0.51mm in the test group with statistically significant difference($p<0.05$) between the two groups(Table 1).

The length of connective tissue adhesion was 0.50mm in the control group, and 1.14mm in the test group(Table 1). The difference was not significant.

The length of new cementum formation was 1.33mm in the control group, and 2.59mm in the test group with statistically

significant difference($p<0.05$) between the two groups(Table 1).

The length of new bone formation was 1.02mm in the control group, and 2.30mm in the test group with statistically significant difference($p<0.05$) between the two groups (Table 1).

IV. DISCUSSION

The main goal of periodontal therapy is the regeneration of periodontal tissue lost due to destructive periodontal diseases. This objective includes the establishment of connective tissue attachment to previously infected root surfaces and regeneration of cementum and alveolar bone.

Calcium sulfate has been known in the medical practice as a bone substitute material that can fill the bone defects^{17), 2)}. Early documentations on the use of plaster of Paris in bone defects produced by various diseases reported the possibility that the material may be used in human bony defects without an adverse inflammatory reactions⁸⁾. In the present study, none of the specimens showed the evidence of severe inflammation, and in an isolated samples, slight infiltration of inflammatory cells did appear, although it may not be attributable to the implantation of calcium sulfate.

Calcium sulfate is known to undergo rapid resorption after implantation into the host tissue. Bell¹⁸⁾ in 1964 studied the resorption rate of plaster of Paris and compared it with those of other types of bone and bone substitutes. He found that the plaster of Paris implants showed the highest resorption rate among the materials tested. Although a rapid

resorption rate is one of the requirements for an ideal bone substitute material, he cautioned against the assumption that the plaster of Paris should be preferable to other types of bone or bone substitutes based solely on the resorption rate. The present study shows that there is little calcium sulfate left in the host tissue after 8 weeks, corroborating the rapid resorption rate reported by other studies.

It is not generally agreed that the presence of calcium sulfate promotes osteogenesis. It may not induce osteogenesis, but rather act as a osteoconductive material. Peltier²⁾ in 1961 stated that the primary role of plaster of Paris is as a space filler, not a direct stimulatory source of osteogenesis. Bahn¹⁹⁾ in his review of the literature, stated that a space-occupying material could decrease the chance of clot breakdown, thereby increasing the chance of osseous regeneration. Radentz & Collings²⁰⁾ also emphasized the importance of space-filling property of plaster of Paris, stating that the tight sealing of the periphery of the periodontal intrabony defects could prevent the apical proliferation of junctional epithelium and encourage connective tissue attachment and bone regeneration from the apical aspects of the wound as the material was resorbed. To fulfill this goal, the surgical technique should be refined so that the implant material can fill the defects and seal the wound without disturbing the integrity of hardened plaster. The importance of wound protection and stabilization after surgery should be emphasized as well, since the trauma to the surgical sites and exposure of surgical wound may result in the disturbance of calcium sulfate integrity or even a loss of the material, allowing the epithelial migration.

The present study shows that the apical migration of junctional epithelium is effectively prevented by the implantation of calcium sulfate as compared to the control sites.

Peltier^{17), 2)} and Bahn¹⁹⁾ mentioned the role of calcium sulfate grafts as a source of inorganic ions. They states that the release of calcium and phosphorus ions from the graft material may increase the local concentration of these ions creating a favorable environment for bone regeneration in the presence of bone and periosteum. When enough organic matrix and functioning osteoblasts are present, these inorganic ions can be effectively utilized in the bone formation. The results of this study show that new bone and cementum formations are significantly greater in the calcium sulfate implanted sites as compared to the control sites where the new bone and cementum formations are minimal. A similar study by Kim et al⁸⁾, on 3-wall intrabony defects treated with calcium sulfate also showed significantly greater amount of new bone and cementum as compared to the control sites. It is speculated that the configuration of 3-wall intrabony defects allows a favorable environment for a wound stabilization and a graft retention. Furthermore, there are enough sources of organic matrix and functioning osteoblasts for the inorganic ions from calcium sulfate to be effectively utilized. In a reasonable extent, these assumptions can be extended to 2-wall intrabony defects as well, and it may be expected that the regenerative potential of calcium sulfate in 2-wall intrabony defects to be greater than those in other types of defects.

Controlled animal models with reproducible defect characteristics and biologic reaction are

critical for evaluation of safety and efficacy of periodontal reconstructive protocols²¹⁾. Cautions must be exercised when interpreting the data from the surgically created defects, as used in the present study, which may not represent the true condition of naturally-occurring defects. However, as Wikesjö et al²¹⁾, pointed out, once the root surfaces are adequately instrumented, healing conditions at the root-gingival interface must be identical whether the defects are surgically created or naturally-occurring.

It is important to realize the limitations of animal studies such as the present study. Although the defect size was carefully controlled, there still exist discrepancies in defect dimensions within and between the groups, which make the straight comparisons difficult. It may be more logical to compare the results measured as a percent of original defect height. However, as Selvig²²⁾ pointed out, this type of comparisons may allow a very small change in real units to appear as a large percentage change. He also mentioned biologic variability of experiment animals as an important limiting factor.

Within these limitations of the experiment, calcium sulfate grafted in 2-wall intrabony defects of dogs may be effective in the regeneration of cementum and bone as well as the prevention of apical migration of junctional epithelium, provided that the suitable environment for healing and wound stability is maintained and the correct surgical techniques are strictly adhered.

V. CONCLUSION

The present study evaluated the periodontal

healing of 2-wall intrabony defects grafted with calcium sulfate as compared to the defects treated with flap surgery alone. Experimental 2-wall intrabony defects of 4mm in width were surgically created in the upper and lower anterior edentulous areas between the third incisors. The test sites include four 2-wall intrabony defects in 3 dogs treated with a calcium sulfate graft. Another four 2-wall intrabony defects in 3 dogs were treated with flap surgery alone as the control sites. Healing was evaluated after 8 weeks, and the following conclusions were obtained.

1. Apical migration of junctional epithelium (JE) was 2.28mm in the control group and 0.51mm in the test group. The difference was statistically significant ($p<0.05$).
2. The length of connective tissue adhesion (CTA) was 0.50mm in the control group and 1.14mm in the test group. The difference was not statistically significant.
3. New cementum (NC) was 1.33mm for the control group and 2.59mm for the test group. The difference was statistically significant ($p<0.05$).
4. New bone (NB) was 1.02mm in the control group and 2.30mm for the test group. The difference was statistically significant ($p<0.05$).

These results suggest that calcium sulfate may be an effective and inexpensive bone substitute material which can contribute significantly in the formation of new bone and cementum in the treatment of periodontal defects.

REFERENCES

1. Frame J.W., Rout P.G., Browne R.M.: Ridge augmentation using solid and porous hydroxyapatite particles with and without autogenous bone or plaster, *J Oral Maxillofac Surg.*, 45:771-777, 1987.
2. Peltier L.F.: The treatment of open fractures. In Peltier L.F. The treatment of fractures: History & iconography. San Francisco: Norman Publishing, 1990.
3. Shaffer C.D., App G.R.: The use of Plaster of Paris in treating infrabony periodontal defects in humans, *J Periodont.*, 42:685-689, 1971.
4. Barnett J.D., Mellonig J.T., Gray J.L. and Towle H.J.: Comparison of freeze-dried bone allograft and porous hydroxyapatite in human periodontal defects, *J Periodontol.*, 60: 231-237, 1989.
5. Bowen J.A., Mellonig J.T., Gray J.J. and Towle H.T.: Comparison of decalcified freeze-dried bone allograft and porous particulate hydroxyapatite in human periodontal osseous defects, *J Periodontol.*, 60:647-654, 1989.
6. Choi E.J. and Cho K.S.: Clinical study on therapeutic effects of expanded polytetrafluoroethylene membrane and calcium carbonate in intrabony defects, *J.Korean Acad Periodontol*, 1994.
7. Mellonig J.T., Bowers G.M., Bright R.W. and Lawrence J.J.: Clinical evaluation of freeze-dried bone allografts in periodontal osseous defects, *J Periodontol.*, 47:125-131, 1976.
8. Habal M.B., Reddi A.H.: Bone grafts & bone substitutes. Philadelphia: W.B. Saunders Co., 1992.
9. Sottosanti J.S.: Aesthetic extraction with calcium sulfate and the principles of guided tissue regeneration, *Pract. Periodont. & Aesthetic Dent.*, 5:61-69, 1993.
10. Sottosanti J.S.: Calcium sulfate: A biodegradable and biocompatible barrier for guided tissue regeneration, *Compend. Cont. Education*, 13(3):226-234, 1992.
11. Sottosanti J.S.: Calcium sulfate is a safe, resorbable barrier adjunct to implant surgical procedures, *Dental Implantology Update*, 4:69-73, 1993.
12. Urist, M.R.: Bone formation by osteoinduction, *Science*, 150:893, 1965.
13. Urist, M.R., Dowell, T.A., Hay, P.H., Strates, B.S.: Inductive substrates for bone formation, *Clin. Ortho.*, 59:59, 1968.
14. Urist, M.R. and Strates, B.S.: Bone morphogenic protein, *J Dent Res.*, 50:1392, 1971.
15. Yamazaki Y., Oida S., Akimoto Y., Shioda S.: Response of the mouse femoral muscle to an implant of a composite of bone morphogenic protein and Plaster of Paris, *Clin. Orthoped. & Related Res.*, 234:240-249, 1988.
16. Kim H.Y. and Chai J.K.: The effect of calcium sulfate and demineralized freeze-dried bone on periodontal healing of 3-wall intrabony defects in dogs, *J. Korean Acad. Periodontol*, 1994.
17. Peltier L.F.: The use of Plaster of Paris to fill defects in bone, *Clin. Orthopedics*, 21:1, 1961.
18. Bell W.H.: Resorption characteristics of bone and bone substitutes, *Oral Surg., Oral Med. & Oral Path.*, 17:650-657,

- 1964.
19. Bahn S.L.: Plaster: A bone substitute, Oral Surg., Oral Med. & Oral Path., 21:672-681, 1966.
20. Radentz W.H., Collings C.K.: The implantation of Plaster of Paris in the alveolar process of the dog, J Periodontol., 36:357-364, 1965.
21. Wikesjö U.M.E., Kean, C.J. and Zimmerman, G.J.: Periodontal repair in dogs: Supraalveolar defect models for evaluation of safety and efficacy of periodontal reconstructive therapy, J. Periodontol., 65:1151-1157, 1994.
22. Selvig K.A.: Discussion: Animal models in reconstructive therapy, J. Periodontol., 65: 1169-1172, 1994.

Illustrations

- Figure 1 A Surgically created 2-wall intrabony defect in the edentulous ridge between the 3rd incisors.
- Figure 2 A- 2wall intrabony defect grafted with calcium sulfate before being sutured.
- Figure 3 Section of the control site showing apical migration of junctional epithelium, connective tissue adhesion and minimal new bone formation above the notch(H-E; original magnification $\times 10$).
- Figure 4 Section of the control site as in figure 3, showing coronal extent of newly formed cementum coronal to the notch(H-E; original magnification $\times 100$).
- Figure 5 Section of the control site showing apical migration of junctional epithelium and a slight amount of new bone formation above the level of the reference notch(H-E; original magnification $\times 10$).
- Figure 6 Section of the control site as in figure 5. A slight amount of new bone formation above the level of the reference notch can be seen(H-E; original magnification $\times 40$).
- Figure 7 Section of the test site showing minimal extension of junctional epithelium and marked extension of newly formed alveolar bone coronal to the notch(H-E; original magnification $\times 10$).
- Figure 8 Section of the test site as in figure 7. New cementum and new bone extended coronal to the notch can be seen(H-E; original magnification $\times 40$).
- Figure 9 Section of the test site showing apical migration of junctional epithelium, and coronal extensions of new cementum and new bone formation(H-E; original magnification $\times 10$).
- Figure 10 Section of the test site as in figure 9, showing marked extension of new cementum and new bone coronal to the notch(H-E; original magnification $\times 40$).
- Figure 11 Section of a test site showing minimal apical migration of junctional epithelium, and coronal extensions of new cementum and new bone formation(H-E; original magnification $\times 10$).
- Figure 12 Section of the test site as in figure 11, showing marked amount of new bone and cementum formation coronal to the notch(H-E; original magnification $\times 40$).

B : alveolar bone	E : junctional epithelium	C : cementum
CT : connective tissue	R : root resorption	PL : periodontal ligament
NC : new cementum	NB : new bone	N : reference notch.

Illustration(I)

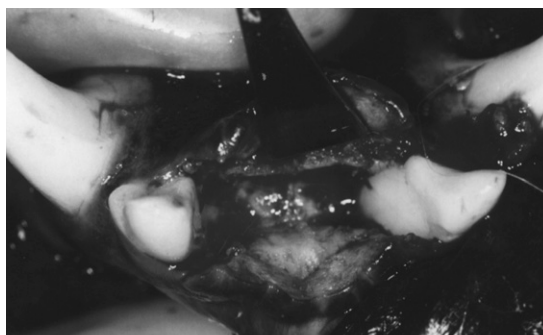


Figure 1

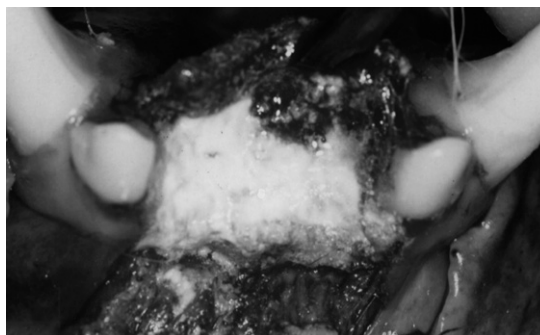


Figure 2




Figure 3

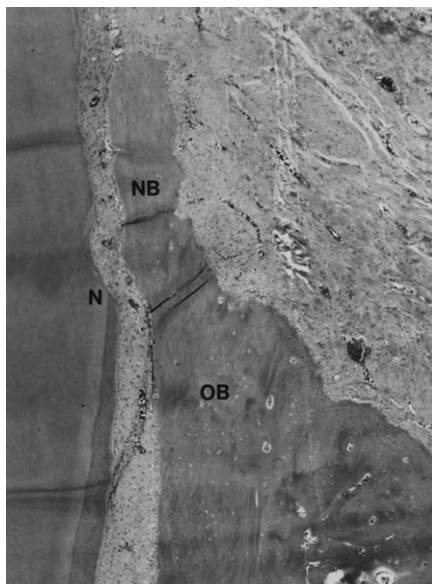


Figure 4

Illustration(II)

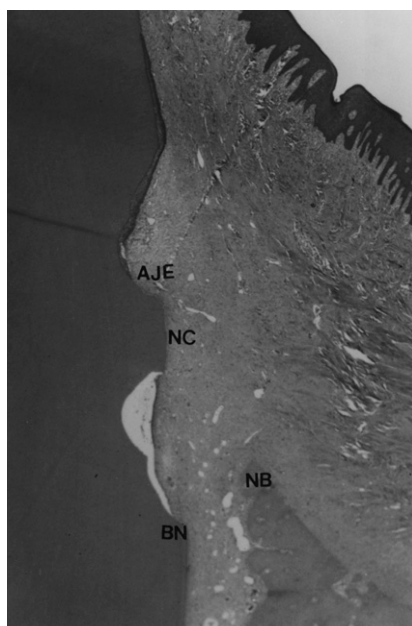


Figure 5

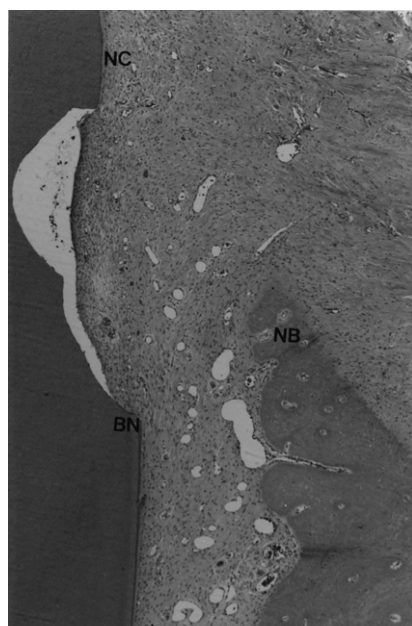


Figure 6

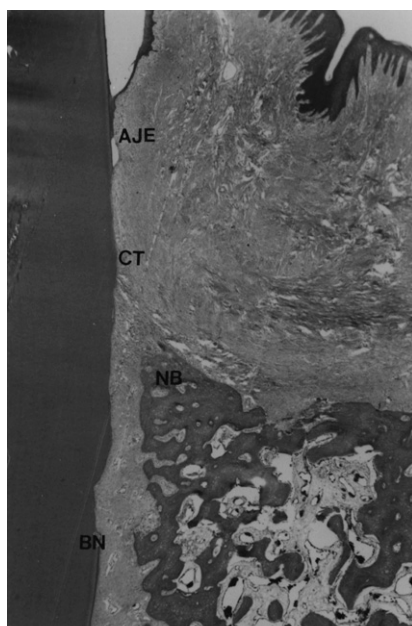


Figure 7

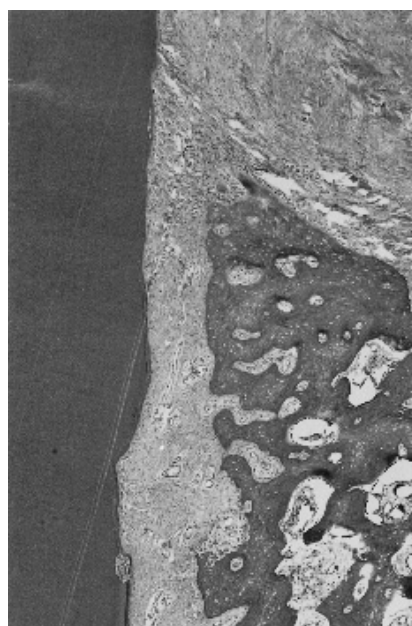
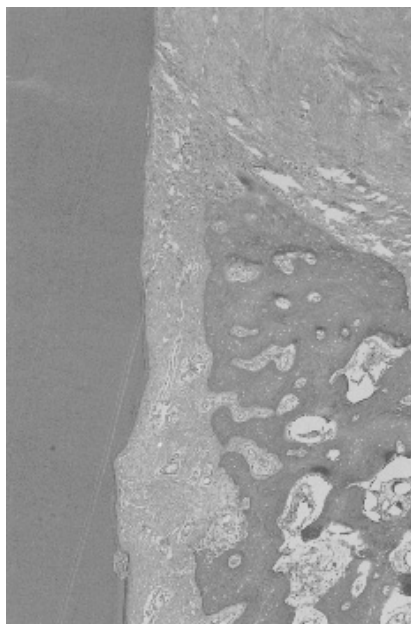
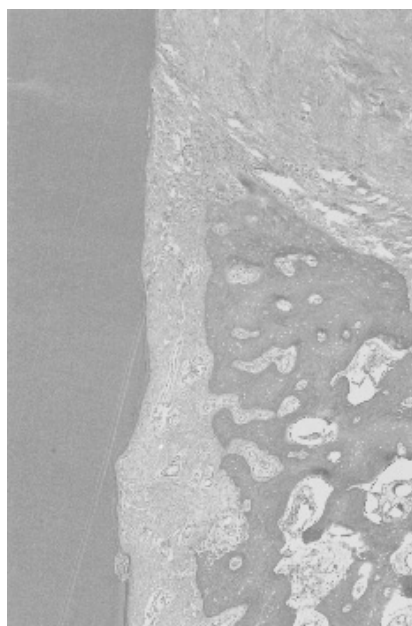
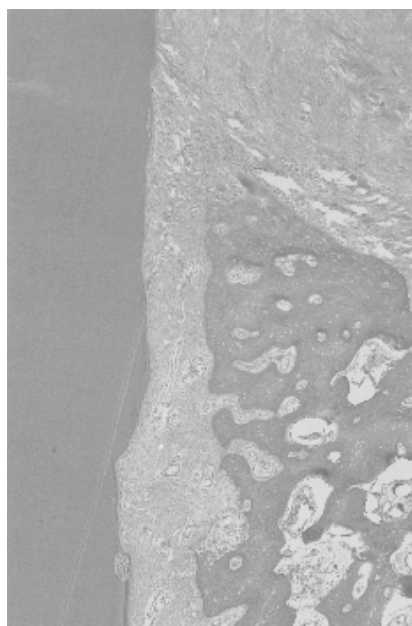


Figure 8







Illustration(III)

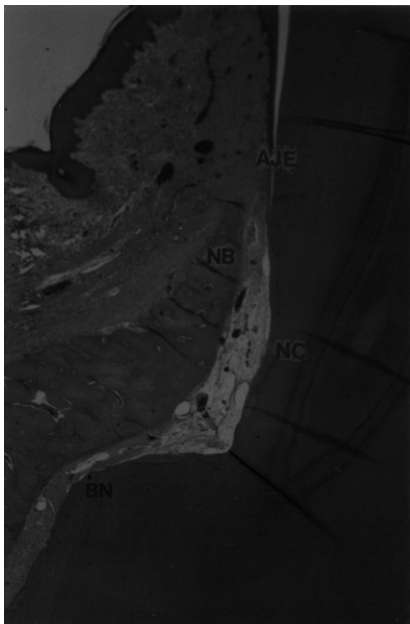


Figure 9

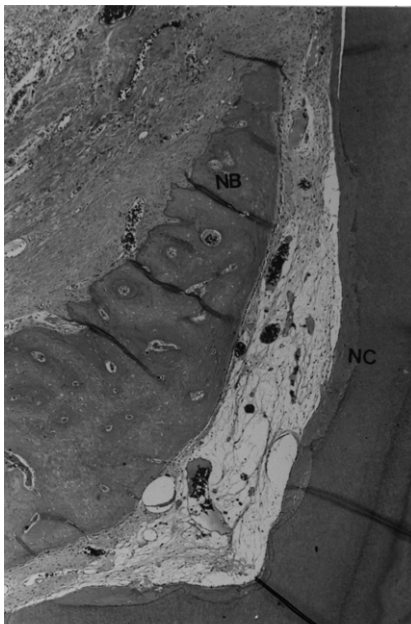

Figure 10

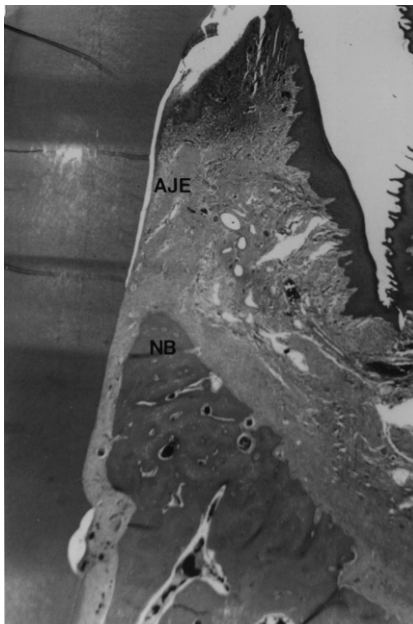


Figure 11

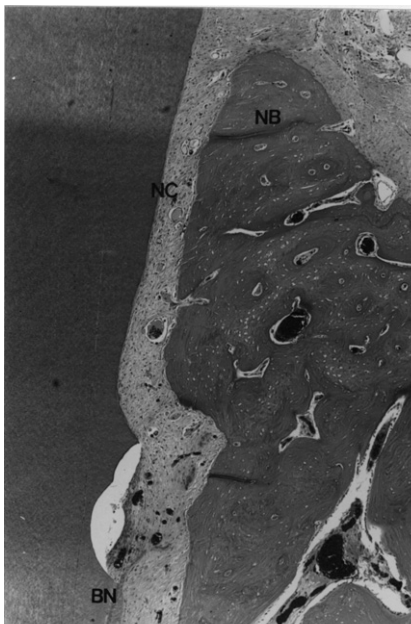


Figure 12

The purpose of this study is to evaluate the regenerative potential of calcium sulfate in the treatment of 2-wall intrabony defects as compared to the flap procedure alone. Periodontal healing of surgically created 2-wall intrabony defects grafted with calcium sulfate were evaluated in dogs. Experimental 2-wall intrabony defects of 4x4x4mm were surgically created in the upper anterior edentulous areas between the canines. The test sites include four 2-wall intrabony defects in 4 dogs treated with a calcium sulfate graft. Another four 2-wall intrabony defects in 4 dogs were treated with flap surgery alone as the control sites. Healing was evaluated after 8 weeks. Apical extension of junctional epithelium(JE) was 2.29mm in the control group and 0.50mm in the test group. The length of connective tissue adhesion(CTA) was 0.53mm in the control group and 1.16mm in the test group. The length of new cementum(NC) was 1.17mm for the control group and 2.55mm for the test group. The length of new bone(NB) was 1.02mm in the control group and 2.27mm for the test group. The test group showed statistically significant differences from the control group in junctional epithelium extension, new cementum and new bone formations ($p<0.05$). Within the limitations of the present study, the results suggest that calcium sulfate may be a safe and cost-effective bone graft material for the treatment of intrabony periodontal defects.

Key words : Calcium sulfate; grafts, bone; bone regeneration; periodontal defects, intrabony; junctional epithelium; cementum; alveolar bone.

성견의 2면 골내낭에 Calcium Sulfate 이식이 치주조직 치유에 미치는 영향

최동훈 · 최성호 · 조규성 · 채중규 · 김종관 · 문익상
연세대학교 치과대학 치주과학교실
치주조직 재생연구소

성견의 2면 골내낭에서 calcium sulfate 이식이 치조골 및 백악질 재생 능력과 접합상피의 근단이동에 미치는 영향에 대해 알아보하고자 3마리 성견의 상하악 제3대구치 근심면을 연결하는 깊이 4mm, 너비 4mm의 2면 골내낭을 외과적으로 형성하고 calcium sulfate를 이식한 군을 실험군으로, 치은박리술만을 실시한 군을 대조군으로 설정하였다. 술후 8주후에 치유결과를 접합상피의 길이, 백악질 형성, 치조골 형성, 결합조직 유착으로 나누어 조직학적으로 비교 관찰하여 다음과 같은 결과를 얻었다.

1. 접합상피의 길이는 대조군에서 2.28mm, 실험군에서 0.51mm로 나타났으며, 대조군과 실험군간에 유의성 있는 차이가 있었다($p<0.05$).
2. 백악질 형성은 대조군에서 1.33mm, 실험군에서 2.59mm로 나타났으며, 대조군과 실험군간에 유의성 있는 차이가 있었다($p<0.05$).
3. 치조골 형성은 대조군에서 1.02mm, 실험군에서 2.30mm로 나타났으며, 대조군과 실험군간에 유의성 있는 차이가 있었다($p<0.05$).
4. 결합조직 유착은 대조군에서 0.50mm, 실험군에서 1.14mm로 나타났으며, 대조군과 실험군간에 유의성 있는 차이가 있었다($p<0.05$).

이상의 결과를 본 실험상의 한계내에서 고려하여 볼 때, calcium sulfate는 2면 골내낭의 치주치료에 치조골 및 백악질 재생 효과가 있으며 안전하고 경제적인 골 이식재 재료로 사용될 수 있으리라 사료된다.

핵심되는 말 :

황화칼슘; 골이식재; 치주조직재생; 골내낭 결손부;

접합상피; 백악질; 치조골