

# 마이크로스크류가 가이드 임플란트 수술을 위한 영상정합 과정에서 작업시간과 술자편의성에 미치는 영향

마이해연<sup>1</sup> · 이두형<sup>1,2\*</sup>

<sup>1</sup>경북대학교 치과대학 치과보철학교실, <sup>2</sup>경북대학교 치의학중개연구소

## Time efficiency and operator convenience of using a micro-screw in image registration for guided implant surgery

Hai Yen Mai<sup>1</sup>, Du-Hyeong Lee<sup>1,2\*</sup>

<sup>1</sup>Department of Prosthodontics, School of Dentistry, Kyungpook National University, Daegu, Republic of Korea

<sup>2</sup>Institute for Translational Research in Dentistry, Kyungpook National University, Daegu, Republic of Korea

**Purpose:** The image registration of radiographic image and digital surface data is essential in the computer-guided implant guide system. The purpose of this study was to examine the effects of using micro-screw on the working time and convenience of operators in the process of image matching for guided implant surgery. **Materials and methods:** A mandibular dental model was prepared in partial edentulism for Kennedy class I classification. Two micro-screws were placed on the each side of retromolar area. Radiographic and scan images were taken using computed-tomography and digital scanning. The images were superimposed by 12 operators in software in two different conditions: using remaining teeth image alone and using teeth and micro-screws images. Working time, operator convenience and satisfaction were obtained, and analyzed using the Mann-Whitney U test ( $\alpha=.05$ ). **Results:** The working time was not statistically different between image registration conditions ( $P>.05$ ); however, operator convenience and satisfaction were higher in the teeth and micro-screw assisted condition than in the teeth-alone assisted condition ( $P<.001$ ). **Conclusion:** The use of micro-screw for the image registration has no effect in working time reduction, but improves operator convenience and satisfaction. (*J Korean Acad Prosthodont* 2019;57:219-24)

**Keywords:** Micro-screw; Image registration; Computer-guided implant surgery; Working time; Convenience; Satisfaction

## Introduction

Proper implant position is fundamental to achieve esthetic and functional implant-supported prostheses.<sup>1</sup> A meticulous preoperative diagnostic and implant planning is mandatory to obtain predictable results. The most conventional way of placing an implant was to create a radiographic guide templates and then converting it to a surgical guide template after cone-beam computed tomography (CBCT) is

taken.<sup>2</sup> This manual fabrication of guide templates involves possibly inaccurate laboratory procedure, and would lead to the difficulty in placing the implant fixture as planned.<sup>3</sup> In recent years, the matching of 3-dimensional (3D) cone-beam computed tomography (CBCT) dataset in digital imaging and communications in medicine (DICOM) format and 3D Mesh dataset in STL format has begun and allowed the introduction of digital surgical guide. Those images are used for planning the placement of implants considering bone, mucosa, and

\*Corresponding Author: Du-Hyeong Lee

Department of Prosthodontics, School of Dentistry, ITRD, Kyungpook National University,  
2175 Dalgubeol-daero, Jung-gu, Daegu 41940, Republic of Korea  
+82 (0)53 600 7651: e-mail, deweylee@knu.ac.kr

Article history: Received April 30, 2019 / Last Revision May 21, 2019 / Accepted June 20, 2019

©2019 The Korean Academy of Prosthodontics

© This is an Open Access article distributed under the terms of the Creative Commons Attribution Non-Commercial License (<http://creativecommons.org/licenses/by-nc/4.0>) which permits unrestricted non-commercial use, distribution, and reproduction in any medium, provided the original work is properly cited.

※This research was supported by the technology transfer and commercialization Program through INNOPOLIS Foundation funded by the Ministry of Science and ICT (2018-DG-RD-0002-01-201).

teeth.<sup>4</sup> Using digital surgical guides, drilling and placing implants at a predetermined position became more predictable, which decreases errors in the implant placement compared to the traditional method. In addition, the advantages of this digital guide system are minimal invasiveness, accurate implant placement, less post-surgical discomfort and reduced time required for surgery.<sup>5-7</sup>

Image surface mapping enables the matching images between CBCT and mesh using at least 3 congruent points.<sup>8</sup> This image registration protocol is applicable when enough number of teeth is remained and distributed in oral cavity. This condition is important in order to create a virtual oral cavity same to the corresponding patient by the image superimposition.<sup>9,10</sup> In patients with extensive tooth loss, the use of additional markers has been suggested to improve the accuracy of image registration.<sup>11-13</sup> Recently, a new protocol using a micro-screw was introduced for enhancing the accuracy of computer-guided implant surgery in a fully edentulous jaw.<sup>14</sup> The effects of micro-screw use was shown in terms of image fusion and guide positioning in a clinical report.<sup>15</sup> However, the effect of micro-screw on the operator performance factors of image registration process in unknown. The purpose of this study was to evaluate whether the use of micro-screw influences the operators' working time and convenience on the image registration process for computer-guided implant surgery. The null hypothesis was that there is no difference between conventional and micro-screw assisted image registration methods in the time and convenience.

## Materials and methods

A mandibular dental model was prepared in the form of Kennedy Class I edentulism. Two micro-screws were placed on the each side of retromolar area using an electric torque driver (MEG-TORQ, MegaGen, Daegu, Korea), and scan caps were connected to the micro-screws. Afterwards, the surface of the mandibular model was digitized by using an intraoral scanner (CS 3600, Carestream, Rochester, NY, USA), and the scan image was saved in standard tessella-

tion language (STL) format. Then, radiographic images were taken by using a CBCT scanner (PaXFlex3D, Vatech, Seoul, Korea) with a field of view of 120 × 85 mm, voxel size of 0.2 mm, exposure conditions of 90 kVp, 10 mA, and a 24-s pulsed scan (Fig. 1). Data were saved in the DICOM format.

The STL and DICOM data were imported into a dental software program (R2GATE v1.1.1, MegaGen, Daegu, Korea) for computer-aided implant surgery planning and guide fabrication. Using volume rendering, the DICOM data were reformatted as a 3D reconstruction image with which the surface scan data were merged. The image registration was conducted manually by designating 3 congruent points from the two images. The registration process was carried out two times per each operator with different matching conditions (Fig. 2). In the first matching, matching points were limited to the remaining teeth. In the second matching, the scan cap images were included as matching areas, as well as the tooth image. Twelve dental graduates who were blinded to the purpose of study and had same the working year in the dental filed, participated in this study. While performing the registration process, working time was recorded for each condi-

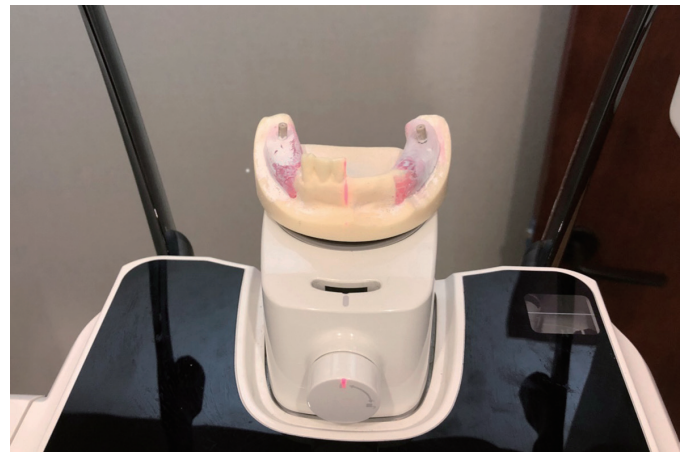

Fig. 1. Cone-beam computed tomography taking of study model.

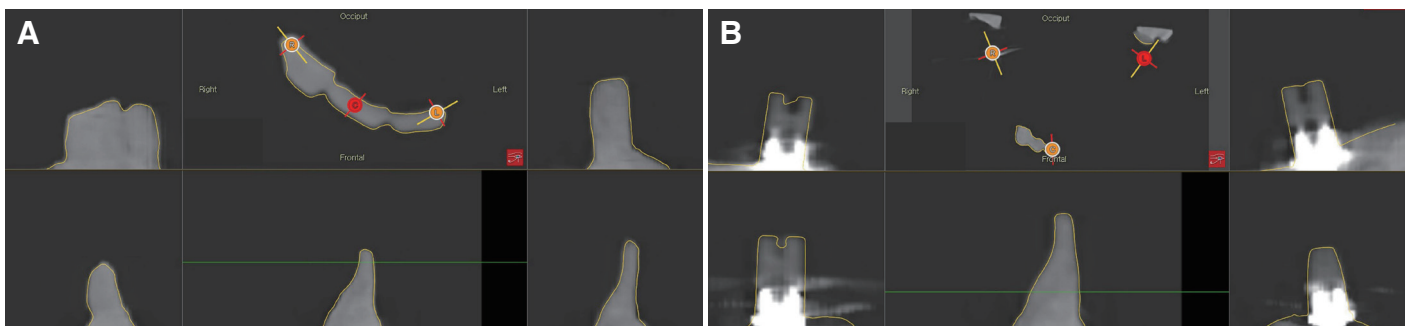


Fig. 2. Image matching process in different conditions. (A) Image matching with remaining teeth alone, (B) Image matching with teeth and micro-screws.

tion. After finishing the image registration, operators' convenience and satisfaction on each matching condition was investigated using a questionnaire (Fig. 3).

All data were reported as the mean  $\pm$  standard deviation. The Mann-Whitney U test were used to compare the amounts of performance time, convenience, satisfaction between the 2 groups. Statistical analyses were performed using SPSS 25.0 for Windows (SPSS Inc., Chicago, IL, USA). A  $P$  value  $< .05$  was considered significant.

## Results

The results of this study is shown in Table 1. The performance time was not statistically different between image registration conditions ( $P > .05$ ). As for operator convenience and satisfaction evaluations, micro-screw assisted image registration condition showed higher values than the condition teeth alone used ( $P < .001$ ). In the

analyses among factors, performance time and operator satisfaction did not show tendency. In the other hand, operator convenience and satisfaction showed positive correlation (Fig. 4).

**Table 1.** Mean  $\pm$  Standard deviation of performance time, convenience, satisfaction according to image registration conditions

	Image registration condition		$P$
	Tooth alone	Micro-screw assisted	
Performance time (second)	304.1 $\pm$ 140.7	302.9 $\pm$ 258.6	$> .05$
Convenience (0-10)	5.1 $\pm$ 1.2	8.1 $\pm$ 0.7	$< .001$
Satisfaction (0-10)	4.6 $\pm$ 1.3	8.3 $\pm$ 0.5	$< .001$

### Q1) How convenient is the operation of Process 1 and Process 2 in the image superposition step?

#### Q1-1) Process 1

Convenient	10	9	8	7	6	5	4	3	2	1	Inconvenient
------------	----	---	---	---	---	---	---	---	---	---	--------------

#### Q1-2) Process 2

Convenient	10	9	8	7	6	5	4	3	2	1	Inconvenient
------------	----	---	---	---	---	---	---	---	---	---	--------------

### Q2) How is your assumed accuracy of each Process 1 and 2?

#### Q2-1) Process 1

Quiet accurate	10	9	8	7	6	5	4	3	2	1	Inaccurate
----------------	----	---	---	---	---	---	---	---	---	---	------------

#### Q2-2) Process 2

Quiet accurate	10	9	8	7	6	5	4	3	2	1	Inaccurate
----------------	----	---	---	---	---	---	---	---	---	---	------------

### Q3) How is your satisfaction when superimposing images in each Process 1 and 2?

#### Q3-1) Process 1

Quiet satisfied	10	9	8	7	6	5	4	3	2	1	Unsatisfied
-----------------	----	---	---	---	---	---	---	---	---	---	-------------

#### Q3-2) Process 2

Quiet satisfied	10	9	8	7	6	5	4	3	2	1	Unsatisfied
-----------------	----	---	---	---	---	---	---	---	---	---	-------------

**Fig. 3.** Questionnaire for evaluating the convenience and satisfaction of operators based on workflow of different matching conditions.

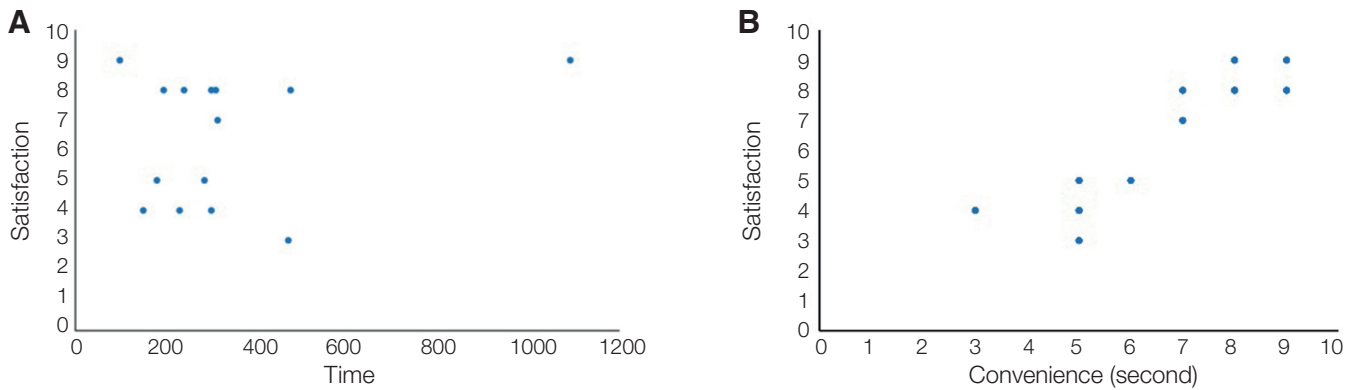


Fig. 4. Scatter plot of performance time and convenience to satisfaction. (A) Relation of time to satisfaction, (B) Relation convenience to satisfaction.

## Discussion

The premise of this article is that the presence of micro-screw in the oral cavity can increase the time efficiency and convenience on the image matching of radiographic and digital scan data in computer-guided implant surgery as an additional fiducial marker. The finding of the study demonstrated that the micro-screw use did not reduce the performance time, but increased convenience of the process. Thus, the null hypothesis, there is no difference between conventional and micro-screw assisted image registration methods in the convenience and time, was partially rejected.

In the past several years, with the introduction of CBCT and 3D printing into the field of implant dentistry, computer-aided design/computer-aided manufacturing (CAD/CAM) technology brought a great evolution of new treatment concepts to dental implant treatment.<sup>16</sup> CBCT and 3D implant planning software provides clinicians not only 3D information of patient's anatomic structures, but also data regarding the patient's final prosthesis. These digital data can be combined with the CAD/CAM technology and further lead to a digital workflow ending with the production of stereolithographic template via a prototyping system.<sup>17,18</sup>

Nowadays, two types of techniques are available in transferring the planned implant position information to the clinical situation; dynamic and static.<sup>19</sup> Dynamic guided implant surgery uses the navigation technique with a software provides a real-time feedback which allows to adjust the implant position and any modification if necessary. However, this dynamic system is not frequently used mostly due to the high costs of the equipment requested and complicated software. The static or application of surgical templates is less flexible in regard to changing the surgical plan as the information is only transmitted through the template. Nonetheless, this static guided implant surgery has been preferred due to no requirement a sophisti-

cated process to carry out, insuring the predictability, a reduced invasiveness of surgical procedures,<sup>20</sup> a shorten healing period, and less postoperative discomfort.<sup>21</sup>

Participants in this study were dental graduates with no exposure to conventional way of image registration or advanced technique of merging 3D images from CBCT and surface scan. This homogeneous group allowed investigating the efficiency of these matching images techniques in an objective and non-biased manner. This is of particular importance because results from a different study population including experienced clinicians or professional designers could be confounding factors to interpret. Whereas, this investigation addressed only the efficiency and operator's preference on both merging 3D data set techniques. Several other aspects need further investigations. This study yielded initial evidence that the effects of use of micro-screws on the operator performance factors.

Even there was not a significant difference of time performance with assistance of micro-screws comparing to conventional technique but greater number of participants agreed that they preferred using micro-screws in matching image due to their assumption of accuracy for final merged image which had been observed directly during the processes. The level of difficulty judged by participants was significantly lower with assistance of micro-screws. These subjective difference in the process of merging images also affected participants' perception of effectiveness.

As for the aspects of accuracy, several attempts have been performed to facilitate the image superimposition in digital guide fabrication. Widmann *et al.*<sup>13</sup> proved the use of implants with ball attachments to increase the number of reference points for image matching in edentulous jaws and concluded that a fixed reference improves registration procedure. Oh *et al.*<sup>12</sup> suggested the insertion of additional resin markers on the palatal gingiva, increasing the reference points and improving the registration of CBCT and digital surface scan data.



The first limitation of this study is that the number of participants is small. The second restraint is that this study was performed with a dental model as a clinical scenario that excluded the effect of actual treatment conditions. Patient consent for placement of micro-screws associated with treatment is also of implant concern. Although results of this study set the first brick to build statement that the insertion of a micro-screw in the posterior area of an edentulous ridge changed the conditions for guided implant surgery, more large scaled clinical studies are need to confirm the effects of improving satisfaction and convenience in use of micro-screw.

## Conclusion

Within the limits of the study, it can be concluded that a higher satisfaction of operators may be achieved if surgical templates are designed by superimposing a surface scan with CBCT with assistance of micro-screws as one of fiducial markers in order to transform the virtual plan into reality. Further clinical studies are needed to support the finding of this study.

## ORCID

Hai Yen Mai <https://orcid.org/0000-0002-9604-5267>

Du-Hyeong Lee <https://orcid.org/0000-0003-2803-7457>

## References

1. Rungcharassaeng K, Caruso JM, Kan JY, Schutyser F, Boumans T. Accuracy of computer-guided surgery: A comparison of operator experience. *J Prosthet Dent* 2015;114:407-13.
2. Kola MZ, Shah AH, Khalil HS, Rabah AM, Harby NM, Sabra SA, Raghav D. Surgical templates for dental implant positioning; current knowledge and clinical perspectives. *Niger J Surg* 2015;21:1-5.
3. Nickenig HJ, Eitner S. Reliability of implant placement after virtual planning of implant positions using cone beam CT data and surgical (guide) templates. *J Craniomaxillofac Surg* 2007;35:207-11.
4. Ganz SD. Three-dimensional imaging and guided surgery for dental implants. *Dent Clin North Am* 2015;59:265-90.
5. Gargari M, Prete V, Pujia M, Ceruso FM. Development of patient-based questionnaire about aesthetic and functional differences between overdentures implant-supported and overdentures tooth-supported. Study of 43 patients with a follow up of 1 year. *Oral Implantol (Rome)* 2013;5:86-91.
6. Schneider D, Marquardt P, Zwahlen M, Jung RE. A systematic review on the accuracy and the clinical outcome of computer-guided template-based implant dentistry. *Clin Oral Implants Res* 2009;20:73-86.
7. Van Assche N, van Steenberghe D, Quirynen M, Jacobs R. Accuracy assessment of computer-assisted flapless implant placement in partial edentulism. *J Clin Periodontol* 2010;37:398-403.
8. Lee DH, An SY, Hong MH, Jeon KB, Lee KB. Accuracy of a direct drill-guiding system with minimal tolerance of surgical instruments used for implant surgery: a prospective clinical study. *J Adv Prosthodont* 2016;8:207-13.
9. Flügge T, Derksen W, Te Poel J, Hassan B, Nelson K, Wismeijer D. Registration of cone beam computed tomography data and intraoral surface scans - A prerequisite for guided implant surgery with CAD/CAM drilling guides. *Clin Oral Implants Res* 2017;28:1113-8.
10. DE Vico G, Spinelli D, Bonino M, Schiavetti R, Pozzi A, Ottria L. Computer-assisted virtual treatment planning combined with flapless surgery and immediate loading in the rehabilitation of partial edentulies. *Oral Implantol (Rome)* 2012;5:3-10.
11. Kim JE, Amelya A, Shin Y, Shim JS. Accuracy of intraoral digital impressions using an artificial landmark. *J Prosthet Dent* 2017;117:755-61.
12. Oh JH, An X, Jeong SM, Choi BH. Digital workflow for computer-guided implant surgery in edentulous patients: A case report. *J Oral Maxillofac Surg* 2017;75:2541-9.
13. Widmann G, Zangerl A, Keiler M, Stoffner R, Bale R, Puelacher W. Flapless implant surgery in the edentulous jaw based on three fixed intraoral reference points and image-guided surgical templates: accuracy in human cadavers. *Clin Oral Implants Res* 2010;21:835-41.
14. Lee DH. Strategic use of microscrews for enhancing the accuracy of computer-guided implant surgery in fully edentulous arches: A case history report. *Int J Prosthodont* 2018;31:262-3.
15. Mai HN, Choi SY, Lee ST, Lee DH. Optimizing accuracy in computer-guided implant surgery with a superimposition-anchor micro screw system: A clinical report. *J Prosthet Dent* 2018;120:789.e1-789.e5.
16. Orentlicher G, Abboud M. Guided surgery for implant therapy. *Oral Maxillofac Surg Clin North Am* 2011;23:239-56, v-vi.
17. Tahmaseb A, Wismeijer D, Coucke W, Derksen W. Computer technology applications in surgical implant dentistry: a systematic review. *Int J Oral Maxillofac Implants* 2014;29:25-42.
18. Chen X, Yuan J, Wang C, Huang Y, Kang L. Modular preoperative planning software for computer-aided oral implantology and the application of a novel stereolithographic template: a pilot study. *Clin Implant Dent Relat Res* 2010;12:181-93.
19. Jung RE, Schneider D, Ganeles J, Wismeijer D, Zwahlen M, Hammerle CH, Tahmaseb A. Computer technology applications in surgical implant dentistry: a systematic review. *Int J Oral Maxillofac Implants* 2009;24:92-109.
20. Hultin M, Svensson KG, Trulsson M. Clinical advantages of computer-guided implant placement: a systematic review. *Clin Oral Implants Res* 2012;23:124-35.
21. Scherer U, Stotzer M, Ruecker M, Gellrich NC, von See C. Template-guided vs. non-guided drilling in site preparation of dental implants. *Clin Oral Investig* 2015;19:1339-46.

# 마이크로스크류가 가이드 임플란트 수술을 위한 영상정합 과정에서 작업시간과 술자편의성에 미치는 영향

마이해엔<sup>1</sup> · 이두형<sup>1,2\*</sup>

<sup>1</sup>경북대학교 치과대학 치과보철학교실, <sup>2</sup>경북대학교 치의학중개연구소

**목적:** 컴퓨터 가이드 임플란트 수술에서 방사선 영상과 디지털 영상과의 정합은 필수적인 과정이다. 본 연구의 목적은 마이크로스크류의 사용이 가이드 수술을 위한 영상정합 과정에서 작업시간과 술자편의성에 미치는 영향을 조사하는 것이다.

**재료 및 방법:** 연구모형의 제작을 위해 Kennedy class I 하악 덴티폼에 마이크로스크류 2개를 후구치 삼각 부위에 식립 후 컴퓨터 단층촬영과 디지털 스캔을 통해 방사선 영상과 스캔 영상을 획득하였다. 영상들은 잔존 치아 부위만을 이용하는 방법과 치아와 마이크로스크류를 이용하는 방법을 이용하여 12명의 술자에 의해 중첩되었다. 이 중첩된 영상에 대하여 작업시간, 술자편의성, 만족도의 자료가 수집되고, Mann-Whitney U test을 통해 분석되었다.

**결과:** 작업시간은 영상정합 조건 사이에 통계학적인 차이가 없었다 ( $P > .05$ ). 술자편의성과 만족도는 치아와 마이크로스크류를 이용하는 방법에서 잔존 치아 부위만을 이용하는 방법보다 높았다 ( $P < .001$ ).

**결론:** 영상정합에서 마이크로스크류의 이용은 작업시간의 단축에는 영향을 미치지 않지만 술자편의성과 만족도는 향상시킨다. (대한치과보철학회지 2019;57:219-24)

**주요단어:** 마이크로스크류; 영상정합; 컴퓨터 가이드 임플란트 수술; 작업시간; 편의성; 만족도

\*교신저자: 이두형

41940 대구 중구 달구벌대로 2175 경북대학교 치과대학 치과보철학교실

053 600 7676; e-mail, deweylee@knu.ac.kr

원고접수일: 2019년 4월 30일 / 원고최종수정일: 2019년 5월 21일 / 원고채택일: 2019년

6월 20일

© 2019 대한치과보철학회

© 이 글은 크리에이티브 커먼즈 코리아 저작자표시-비영리 4.0 대한민국 라이선스에 따라  
이용하실 수 있습니다.