

# 심한 하악 치조제 흡수를 가진 환자에서 임플란트를 이용한 가철성 국소의치로 수복한 증례

최바다 · 김연주 · 이재훈\*

연세대학교 치과대학 치과보철학교실

## Implant-assisted removable partial denture for severely atrophied mandible

Bada Choi, Yeun Ju Kim, Jae Hoon Lee\*

*Department of Prosthodontics, Yonsei University College of Dentistry, Seoul, Republic of Korea*

Mandible with severe alveolar bone atrophy poses a significant challenge in terms of reproducing clinically acceptable anatomy for a removable prosthesis. To overcome this potential complication, altered cast impression technique is often recommended to capture accurate and functional gingiva tissues. It becomes possible to get proper anchors functional impression by placing 2 implants crowns which were impossible in previous implant overdenture impression technique. In this case, an 80-year old female patient with severe mandibular ridge atrophy was treated with an implant-assisted removable partial denture with two implant crowns on the canine area. An altered cast impression was taken with an individual tray on a metal framework of removable partial denture on both posterior edentulous areas. The patient was satisfied with the final prosthesis after failure of 2 previous prostheses. Clinician had a difficult time to manage disabled patient and patient were suffered with ill-fitting denture due to inaccurate impression in conventional overdenture condition. The oral rehabilitation was completed with placing 2 implants as proper anchor. (*J Korean Acad Prosthodont* 2019;57:171-5)

**Keywords:** Altered cast impression; Implant removable denture; Disabled patient; Oral rehabilitation

### Introduction

Osseointegrated implants have long been considered a dependable treatment for effectively restoring oral function and improving quality of life of edentulous patients.<sup>1-3</sup> Particularly in the case of removable prostheses for mandibular edentulous patients, use of removable prostheses with dental implants are well documented to improve function, usually in the form of an implant overdenture with two or four implants.<sup>4,5</sup>

Mandible with severe alveolar bone atrophy poses a challenge to prosthodontists aiming to achieve successful oral rehabilitation.<sup>6</sup> The shape of the posterior ridge often changes from a positive structure to a flat or negative one as the ridge atrophy progresses, making it hard

to achieve a proper impression to reproduce clinically acceptable anatomy on the working cast.

In mandibular distal extension cases, an altered cast impression procedure has been recommended to improve the stability and support of the removable partial dentures with accurate reproduction of the anatomy of residual ridges.<sup>7-9</sup> To avoid incorrect or incomplete seating of the framework in the mouth, a major potential complication of this procedure, stable stops for the framework are necessary.<sup>10</sup>

Inaccurate impression following unfit tissue surface of the denture causes sore spots, making it difficult for the patient to accommodate the new prosthesis. A precise impression with stable stops and accurate reproduction of a clinically acceptable tissue surface of the denture can resolve this issues. The combination of implant, fixed

\*Corresponding Author: Jae Hoon Lee

Department of Prosthodontics, Yonsei University College of Dentistry,  
50-1 Yonsei-ro, Seodaemun-gu, Seoul 03722, Republic of Korea  
+82 (0)2 2228 3159: e-mail, jaehoon115@yuhs.ac

Article history: Received October 2, 2018 / Last Revision October 4, 2018 / Accepted October 23, 2018

©2019 The Korean Academy of Prosthodontics

©This is an Open Access article distributed under the terms of the Creative Commons Attribution Non-Commercial License (<http://creativecommons.org/licenses/by-nc/4.0>) which permits unrestricted non-commercial use, distribution, and reproduction in any medium, provided the original work is properly cited.

prosthesis and altered cast impression technique may help improve the accuracy of impression on atrophied mandible.

## Case Report

An 80-year old woman visited the Department of Prosthodontics at Yonsei University, College of Dentistry. The chief complaint was pain on chewing on her mandible. The patient had a pair of old prostheses made in a private dental clinic, an upper removable partial denture and lower complete denture. She had a medical history of cerebral infarction and had trouble controlling her right hand due to hemiplegia.

Clinical and radiographic examination revealed severe ridge resorption on the mandibular ridge, especially on the posterior region. On maxilla, there were 6 remaining teeth, from right second premolar to left central incisor, treated with a porcelain-fused-to-gold fixed partial denture (Fig. 1). She had no problem with the prosthesis on her maxilla, but could not use the lower complete denture due to pain from several sore spots. A dental implant could not be placed on the posterior region due to severe atrophy. Thus implant-retained overdenture with implants on both canine positions was planned.

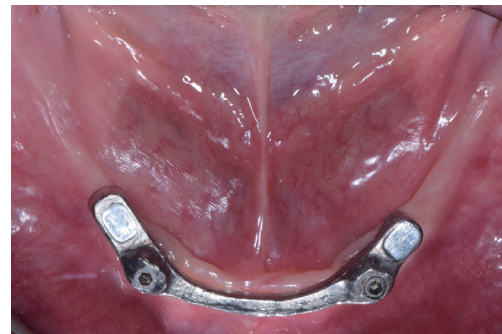
The implant was placed at the Department of Periodontics. After 4 months of healing, a final impression with customized open tray was taken for implant abutment crowns. Milled bar and magnet were selected for the attachments of the first prosthesis to enhance implant support and stability. The magnets (Magfit Ex, Aichi Steel Co., Tokai, Aichi, Japan) were placed on the bar distal to each implant. The denture with milled bar and magnets was designed for easy and proper placement on the mandible by the hand-disabled patient (Fig. 2).

After the first implant overdenture was delivered, however, the patient consistently complained of sore spots on the posterior mandible for several months. Minor denture movements from the gap between

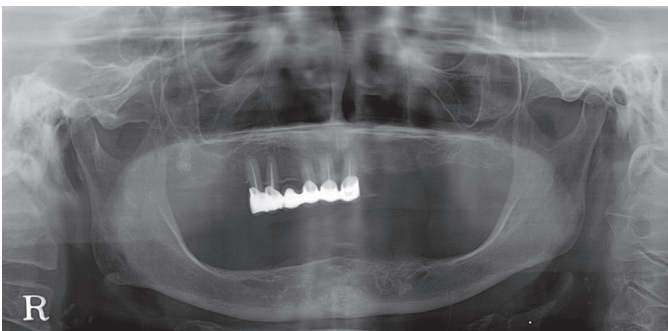
the milled bar and denture seemed to keep causing soreness. The attachments were therefore changed to locator attachments (Kerator, Daekwang I.D.M, Seoul, Korea) to reduce the minor movement of the first prosthesis and the overdenture was remade (Fig. 3).

However, the patient was not able to chew with the second overdenture either, complaining of severe sore spots and lack of stability. Like the first overdenture with the milled bar attachment, the second prosthesis was unsatisfactory to the patient in restoring the chewing function.

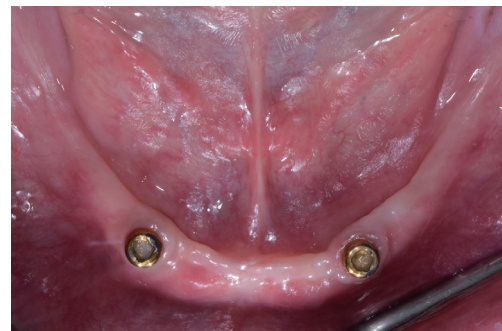Inaccuracy in terms of both the impression and reproduction of the anatomical details of the atrophied mandible seems to mainly account for the failure of both prostheses. Because proper placement of the customized tray was difficult without stable tissue stops, accurate impressions of the posterior ridge for the two former trials were compromised. Finally, an implant-assisted removable partial denture with two single implant abutment crowns was fabricated and installed on both canine regions. After the try-in of the metal framework, a customized tray for a secondary impression of the posterior region was connected to the framework (Fig. 4).



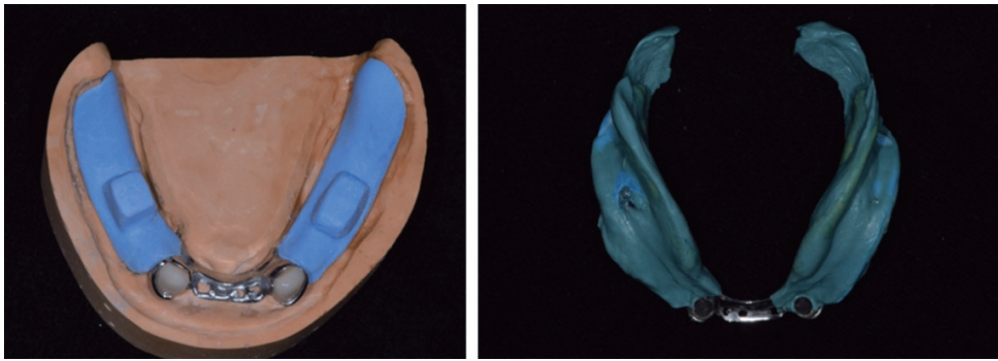
**Fig. 2.** Bar attachment with magnets. After dental implants placed on both canine of mandible, milled bar with magnets distal to the implants was delivered.



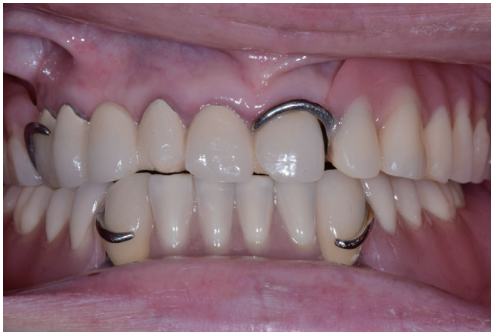**Fig. 1.** Patient's panoramic radiograph upon 1st visit. Severe alveolar bone resorption of mandible is found. The patient was treated previously with upper removable partial denture and lower complete denture, but not satisfied with it.



**Fig. 3.** Locator attachments. Locator attachments were delivered after fail overdenture with milled bar attachment.



**Fig. 4.** Altered cast impression technique. (A) Individual tray was fabricated on Cr-Co metal framework. Cingulum rests on both implant crowns were used as stops for tray, (B) Border molding and secondary impression were taken.



**Fig. 5.** Implant assisted removable partial denture (IARPD). Final prosthesis was delivered. The patient was satisfied with the result.

With the stable tray stops of the rest seat on the implant crowns, border molding of the posterior tray was done, and then a final impression was taken for the implant assisted removable partial denture (IARPD). An altered cast model was made and the denture was fabricated and delivered to the patient (Fig. 5). The patient complained of minor sore spots at the first two check-up appointments, but afterwards was able to chew without pain and eventually expressed satisfaction with the third prosthesis, reporting no sore spots.

## Discussion

This 80-year-old woman had problems adapting to new restorations. First, her mandible was severely resorbed to a nearly flat alveolar ridge. Severe mandibular ridge atrophy poses a severe challenge to prosthodontists. Also, due to hemiplegia, she could not move her right hand, which made it hard to take the denture in and out. Moreover, most elderly patients don't recognize that they have lost proper muscle tone and movements. The patients always compare their new denture with a previous one that had satisfied them when they were

younger. These considerations make it more difficult for the clinician to satisfy the patients.

It was difficult to obtain a precise impression in this patient due to her physical condition and atrophied mandible, which both aggravated the situation. However, by sticking to fundamental denture concepts, a clinician eventually finds solutions.

There is still no consensus on using implant crowns as abutments of removable partial dentures. However, several recent clinical reports have reported short- or long-term successes.<sup>11-13</sup> If clinicians do not greatly deviate from orthodox concepts regarding removable prosthodontic dentures when using implants as abutments, they can achieve successful rehabilitation within limited circumstances. In a case such as this, when the patient's condition is neither healthy nor stable, frequent recall check-ups are to be recommended.

## ORCID

Bada Choi <https://orcid.org/0000-0003-2014-2674>

Yeun Ju Kim <https://orcid.org/0000-0001-7021-8679>

Jae Hoon Lee <https://orcid.org/0000-0003-2281-8885>

## References

1. Brånemark PI, Svensson B, van Steenberghe D. Ten-year survival rates of fixed prostheses on four or six implants ad modum Brånemark in full edentulism. *Clin Oral Implants Res* 1995;6:227-31.
2. Buser D, Mericske-Stern R, Bernard JP, Behneke A, Behneke N, Hirt HP, Belser UC, Lang NP. Long-term evaluation of non-submerged ITI implants. Part 1: 8-year life table analysis of a prospective multi-center study with 2359 implants. *Clin Oral Implants Res* 1997;8:161-72.
3. Thomason JM, Feine J, Exley C, Moynihan P, Müller F,

- Naert I, Ellis JS, Barclay C, Butterworth C, Scott B, Lynch C, Stewardson D, Smith P, Welfare R, Hyde P, McAndrew R, Fenlon M, Barclay S, Barker D. Mandibular two implant-supported overdentures as the first choice standard of care for edentulous patients-the York Consensus Statement. *Br Dent J* 2009;207:185-6.
4. Fontijn-Tekamp FA, Slagter AP, van't Hof MA, Geertman ME, Kalk W. Bite forces with mandibular implant-retained overdentures. *J Dent Res* 1998;77:1832-9.
  5. Pera P, Bassi F, Schierano G, Appendino P, Preti G. Implant anchored complete mandibular denture: evaluation of masticatory efficiency, oral function and degree of satisfaction. *J Oral Rehabil* 1998;25:462-7.
  6. van Waas MA. Determinants of dissatisfaction with dentures: a multiple regression analysis. *J Prosthet Dent* 1990;64:569-72.
  7. Holmes JB. Influence of impression procedures and occlusal loading on partial denture movement. *J Prosthet Dent* 1965;15:474-83.
  8. Leupold RJ, Flinton RJ, Pfeifer DL. Comparison of vertical movement occurring during loading of distal-extension removable partial denture bases made by three impression techniques. *J Prosthet Dent* 1992;68:290-3.
  9. Leupold RJ, Kratochvil FJ. An altered-cast procedure to improve tissue support for removable partial dentures. *J Prosthet Dent* 1965;15:672-8.
  10. Principles, concepts, and practices in prosthodontics-1994. Academy of Prosthodontics. *J Prosthet Dent* 1995;73:73-94.
  11. Chronopoulos V, Sarafianou A, Kourtis S. The use of dental implants in combination with removable partial dentures: a case report. *J Esthet Restor Dent* 2008;20:355-64.
  12. Jang Y, Emtiaz S, Tarnow DP. Single implant-supported crown used as an abutment for a removable cast partial denture: a case report. *Implant Dent* 1998;7:199-204.
  13. Pellecchia M, Pellecchia R, Emtiaz S. Distal extension mandibular removable partial denture connected to an anterior fixed implant-supported prosthesis: a clinical report. *J Prosthet Dent* 2000;83:607-12.

## 심한 하악 치조제 흡수를 가진 환자에서 임플란트를 이용한 가철성 국소의치로 수복한 증례

최바다 · 김연주 · 이재훈\*

연세대학교 치과대학 치과보철학교실

치조제가 심하게 흡수된 하악의 정확한 해부학적 구조를 채득하는 것은 매우 어렵다. 이 경우 보다 정확한 인상을 채득하기 위하여 수정모형 제작법을 통한 기능 인상 채득이 추천된다. 이를 위해서는 양측에 2개의 임플란트 크라운을 이용하여 적절한 고정원을 얻을 필요가 있다. 이를 통해 임플란트 피개의치에서는 불가능하였던 수정모형 제작법을 시행할 수 있다. 본 증례에서는 하악의 치조제가 심하게 흡수된 80세 여환을 하악 양측 견치 부위의 임플란트 크라운을 지대치로 한 가철성 국소의치를 이용하여 수복하였다. 가철성 국소의치의 금속구조물을 이용하여 개인 트레이를 제작하고 수정모형 제작을 위한 이차 인상을 채득하였다. 환자는 앞선 2회의 피개의치 실패 후 제작된 최종 보철물에 만족하였다. 치료 초기에 행해진 피개의치 치료에서는 부정확한 인상법에 따른 부적절한 보철물로 인해 술자와 환자 모두 만족하지 못했지만, 2개의 임플란트를 적절한 고정원으로 이용함으로써 성공적인 수복이 가능하였다. (대한치과보철학회지 2019;57:171-5)

**주요단어:** 수정모형 인상법; 임플란트 국소의치; 장애 환자; 구강 회복

\*교신저자: 이재훈

03722 서울 서대문구 연세로 50-1 연세대학교 치과대학 치과보철학교실

02 2228 3159; e-mail, jaehoon115@yuhs.ac

원고접수일: 2018년 10월 2일 / 원고최종수정일: 2018년 10월 4일 / 원고채택일: 2018년 10월 23일

© 2019 대한치과보철학회

이 글은 크리에이티브 커먼즈 코리아 저작자표시-비영리 4.0 대한민국 라이선스에 따라 이용하실 수 있습니다.