

심한 마모를 가진 환자에서 임플란트와 가철성 국소의치를 이용한 전악수복 증례

이신언 · 이원섭 · 이철원 · 이수영*

가톨릭대학교 의과대학 서울성모병원 치과보철과

Full mouth rehabilitation of severely worn dentition with implants and removable partial dentures

Shin Eon Lee, Won Sup Lee, Cheol Won Lee, Su Young Lee*

Department of Prosthodontics, Seoul St. Mary's Hospital, College of Medicine, The Catholic University of Korea, Seoul, Republic of Korea

Excessive tooth wear can lead to decrease in occlusal vertical dimension and can cause pathological changes in the oral environment and masticatory system. When recovering occlusal vertical dimension and occlusion, accurate diagnosis and analysis are essential. This clinical case describes a 75-year-old woman with severely worn dentition due to loss of the posterior support. Full mouth rehabilitation with occlusal vertical dimension increment was planned. Clinical and radiographic examinations, occlusal vertical dimension evaluation, and diagnostic wax-up were performed and patient adaptability was evaluated using provisional restorations. As for definitive restoration, considering economic condition of the patient, removable partial denture was fabricated and solitary implants were placed in the mandibular left and right posterior region to increase support and retention of the removable partial denture. During one year of follow-up, functional and esthetic outcomes were observed satisfactory. (*J Korean Acad Prosthodont* 2018;56:70-6)

Keywords: Mouth rehabilitation; Tooth wear; Occlusal vertical dimension; Dental implants; Removable partial denture

Introduction

Tooth wear refers to loss of tooth surface by causes other than dental caries, dental trauma or developmental disability.¹ Tooth wear can be categorized into physiological wear and pathological wear. Physiological wear occurs gradually through a lifetime and it is accepted as a natural phenomenon. However pathological wear occurs at a certain time with an excessive amount.^{2,3}

An important consideration in restoring worn dentition is to determine the amount of occlusal vertical dimension (OVD) that has been lost. In the case of physiological wear, it is known that OVD can be maintained due to the eruption of the teeth and the compensatory

growth of the alveolar bone.^{4,5} On the other hand, pathological tooth wear is faster than the compensatory mechanism, which accompanies loss of OVD. As a result, side effects occur such as esthetic problems, decreased masticatory function, and joint disease due to loss of anterior and lateral guidance.⁶

Turner and Missirlian recommend to set up a treatment plan considering the amount of decreased OVD and interocclusal space required for prosthetic rehabilitation.⁷ It is often necessary to restore decreased OVD in order to secure interocclusal space for prosthetic restoration and improve occlusion and esthetics.^{7,8} Increment of OVD should be carefully determined through overall analysis of the patient. When increasing the OVD, its effects to the temporoman-

*Corresponding Author: Su Young Lee

Department of Prosthodontics, Seoul St. Mary's Hospital, College of Medicine, The Catholic University of Korea, Banpo-daero 222, Seocho-gu, Seoul 06591, Republic of Korea

+82 (0)2 2258 1795; e-mail, lsuyoung@daum.net

Article history: Received September 4, 2017 / Last Revision September 21, 2017 / Accepted September 27, 2017

© 2018 The Korean Academy of Prosthodontics

© This is an Open Access article distributed under the terms of the Creative Commons Attribution Non-Commercial License (<http://creativecommons.org/licenses/by-nc/3.0>) which permits unrestricted non-commercial use, distribution, and reproduction in any medium, provided the original work is properly cited.

dibular joints, neuromuscular activity, and pronunciation must be monitored carefully.⁹

The patient in this case had excessive wear of the mandibular anterior teeth due to loss of mandibular posterior teeth for a long time, moreover the opposing maxillary dentition were porcelain prosthesis. This clinical report describes that a satisfactory clinical result was achieved with an improvement in functions and esthetics by full mouth rehabilitation restoring the OVD using removable partial dentures and few implants.

Case report

The patient was a 75-year-old female who was referred from the Department of Periodontics for prosthetic consultation. Her chief complaint was that it was inconvenient to eat because mandibular posterior teeth have been lost for a long time and mandibular anterior teeth were worn out. The patient was taking hypertension drugs and had history of bisphosphonate injections due to osteoporosis. A 14-unit one-piece fixed partial denture (FPD) on maxillary teeth was made 10 years ago and the mandibular molars were extracted about 5 years ago. Porcelain fracture on the left premolar area of maxillary porcelain fused metal (PFM) prosthesis and decementation with secondary caries on posterior molars were observed (Fig. 1). Missing teeth on mandible were right first and second molars, left second premolar, first and second molars. Severe occlusal wear was observed in all remaining mandibular teeth. Caries and pulp exposure were accompanied on several mandibular teeth. Radiographic examination revealed wears on occlusal surface of the mandibular teeth and severe secondary caries with peri-apical lesions on the maxillary posterior teeth (Fig. 2). There were no suspicious radiologic findings on temporomandibular joint, and mandibular opening movement was also in a normal range. There was no history of para-functional habit or TMJ disease. The patient had a brachycephalic face with slightly developed masseter muscles.

Preliminary impression was obtained to make diagnostic casts. The diagnostic casts were mounted on a semi-adjustable articulator (Hanau Modular Articulator, Whip Mix Corp., Louisville, KY, USA) with a face-bow record and a centric relation registration record. There was not enough interocclusal space to restore the missing mandibular molars. As the result, it was decided that full mouth rehabilitation with OVD increment for functional and esthetic restoration. The patient's freeway space was 5 mm, being greater than the normal value, 2 - 4 mm. Based on the analysis of patient's facial appearance, freeway space and interocclusal space for restoration, increment of OVD was 2 mm for functional and esthetical prosthesis. According to Turner and Missirlian's classification of tooth wear, this patient was in category 1 which indicates excessive tooth wear with loss of OVD.⁷ In this category, reduced OVD should be restored with trial restorations to evaluate patient's adaptation and function at the increased OVD, and then definitive restoration should be processed.

On the semi-adjustable articulator, OVD was elevated at 2 mm with incisal pin, and diagnostic wax up was made (Fig. 3). Temporary shells were prefabricated using autopolymerizing acrylic resin (Alike, GC America Inc., Chicago, IL, USA) based on the diagnostic wax-up. The maxillary one-piece FPD was removed, and maxillary

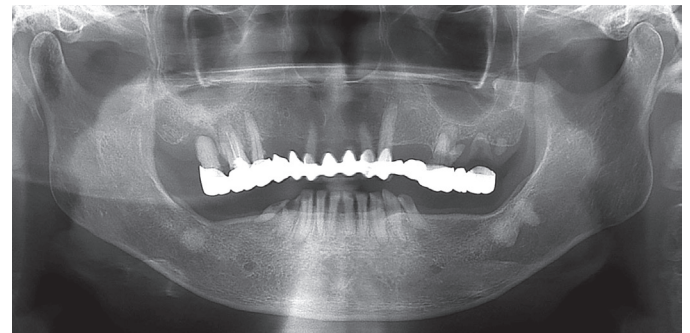


Fig. 2. Initial panoramic radiograph before treatment. Wears on occlusal surface of the mandibular teeth and severe secondary caries with peri-apical lesions on the maxillary posterior teeth were observed.

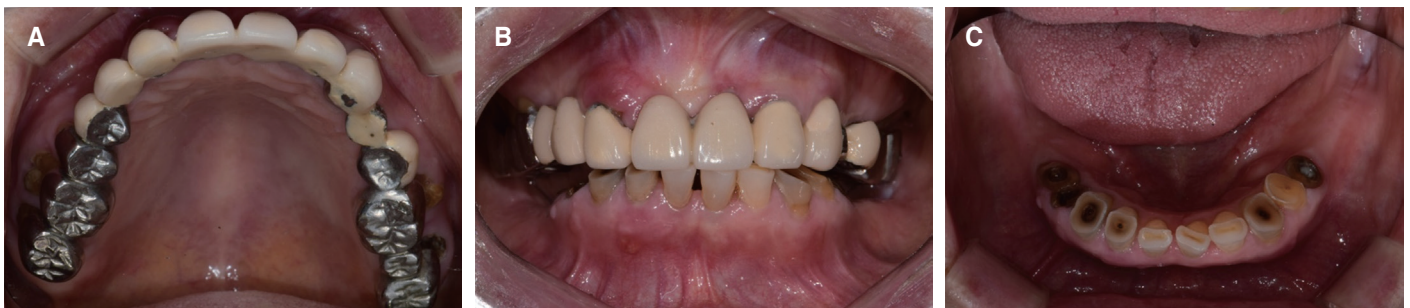

Fig. 1. Intraoral view of the patient before treatment. Severely worn mandibular natural teeth occluding maxillary PFM prosthesis were observed. (A) Maxillary occlusal view, (B) Frontal view, (C) Mandibular occlusal view.

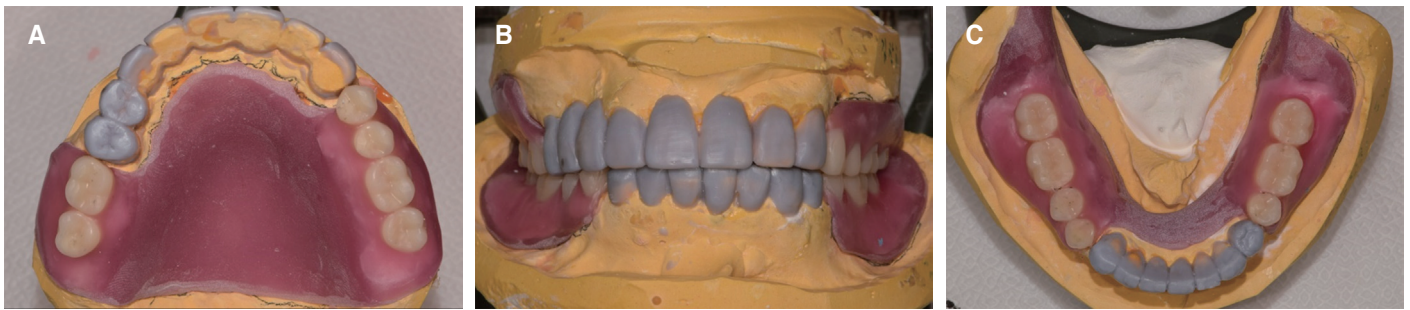


Fig. 3. Diagnostic wax up at increased OVD. (A) Maxillary occlusal view, (B) Frontal view, (C) Mandibular occlusal view.

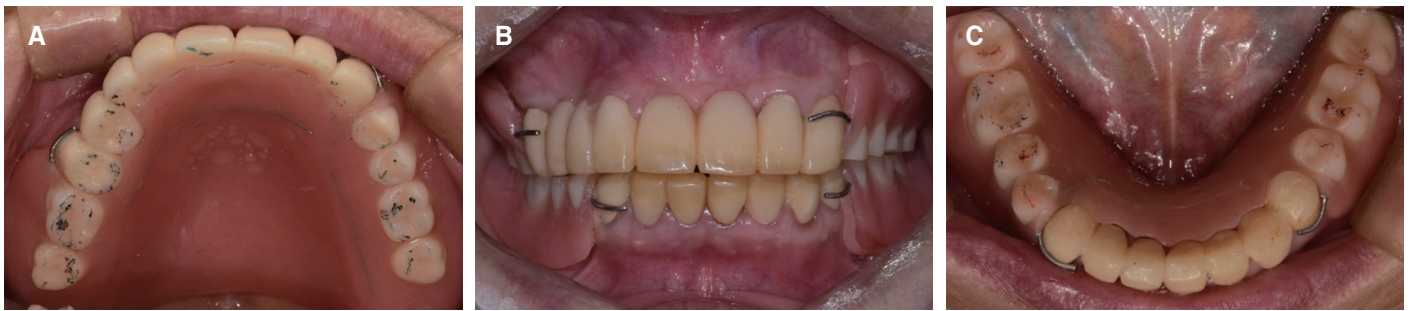

Fig. 4. Provisional restoration. (A) Maxillary occlusal view, (B) Frontal view, (C) Mandibular occlusal view.

first and second molars on both sides which were hopeless teeth were extracted. Then an 8-unit provisional FPD with maxillary right second premolar, right lateral incisor, left lateral incisor and canine abutment was delivered. Mandibular right first and second premolar and left first premolar were extracted and provisional restorations were delivered to the remained teeth after preparation. Provisional removable partial denture was fabricated for posterior edentulous area of maxilla and mandible (Fig. 4). After provisional restoration placement, reduced freeway space to 2 mm was verified which is in a normal range.

The patient used provisional restorations for 6 weeks. The patient was well adapted to the provisional prosthesis with raised OVD and did not show temporomandibular joint discomfort. Thus, definitive restorations were designed to reproduce OVD in provisional restorations. The patient wanted removable partial dentures and implants which are covered by national health insurance for definitive restorations, and did not want complicated surgery such as bone grafting. Therefore, definitive treatment plan was to make removable partial dentures (RPD) with surveyed crowns. In addition, placement of two implants in the mandibular posterior region was planned to obtain additional retention and support for the mandibular RPD.

Cone-beam computed tomography was taken with diagnostic stent prepared by duplicating the provisional removable partial denture for

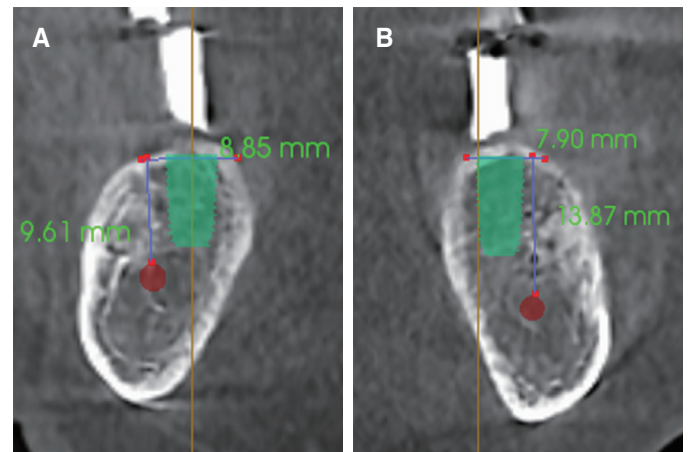


Fig. 5. Cone beam computed tomography image for implant placement. (A) Mandibular right second molar, (B) Mandibular left second molar.

implant placement (Fig. 5). In selecting positions for implant placement, it was considered that selecting mandibular premolar site to make Kennedy class I RPD, but alveolar bone was so narrow that guided bone regeneration was required for implant placement at planned position. On the other hand, the second molar site had sufficient bone width for an implant with a diameter of 5 mm. Consid-

erling the distance to the inferior alveolar nerve, internal connection implants (TSIII SA; Osstem implant Co., Busan, Korea) were placed on mandible, diameter of 5.0 and a height of 8.5 mm on right second molar, diameter of 5.0 and a height of 10 mm on left second molar. Root canal treatment and post and core build up was performed on mandibular right lateral incisor, canine, left lateral incisor, canine, first premolar and maxillary right second premolar due to hypersensitivity.

After osseointegration of implants, the definitive impression was made. The autopolymerizing acrylic resin (SR Ivoren, Ivoclar Vivadent, Schaan, Liechtenstein) was used to make individual trays. The pick-up impression coping was fastened to the mandibular implant and definitive preparation of teeth was done. Definitive impression was made with polyvinyl siloxane impression material (Imprint II Garant, 3M ESPE, St. Paul, MN, USA) for surveyed crowns. The master casts were fabricated with a Type IV dental stone (GC Fujirock EP, GC Europe N. V., Leuven, Belgium). Occlusal rims were fabricated with visible light-curing acrylic resin (Triad TruTray VLC, Dentsply Inc., York, PA, USA) and baseplate wax (Truwax Baseplate Wax, Dentsply Inc., York, PA, USA). Interocclusal registration was made with occlusal rim and polyvinylsiloxane occlusal registration material (O-bite, DMG, Hamburg, Germany). The casts were mounted on a semi-adjustable articulator (Hanau Modular Articulator, Whip Mix Corp., Louisville, KY, USA) with a face-bow record. On the mounted working casts, appropriate size of stock abutments was selected and milled.

The definitive fixed restorations were PFM surveyed crowns that were designed and fabricated in a digital method. 3D laser scanner (3Shape D800, 3Shape A/S, Copenhagen, Denmark) was used to make digital impressions of mater casts and interocclusal relation. Computer-aided design program (3Shape Dental Manager, 3Shape A/S, Copenhagen, Denmark) was used to make digital wax-ups for crowns (Fig. 6A). Then the digital wax-ups were cut back to allow for porcelain application (Fig. 6B). PFM frameworks were made of cobalt-chrome alloy through laser-sintering technique using 3D printer (EOSINT M270, Electro Optical Systems GmbH, Munich, Germany). An 8-unit FPD in maxilla and single crowns in mandible were fabricated. The metal frameworks were tried in and confirmed good fit and marginal adaptation. The metal frameworks were veneered with porcelain. The definitive fixed prostheses were cemented with resin modified glass ionomer cement (FujiCEM II, GC Corp., Tokyo, Japan).

Polyvinyl siloxane impression material (Exadenture, GC Corp., Tokyo, Japan) with individual tray was used for the definitive impression of RPD. The maxillary RPD was Kennedy Class I which uses palatal plate as major connector, and the mandibular RPD was Kennedy Class III which uses lingual bar as major connector. RPD frameworks were fabricated with the conventional casting technique.

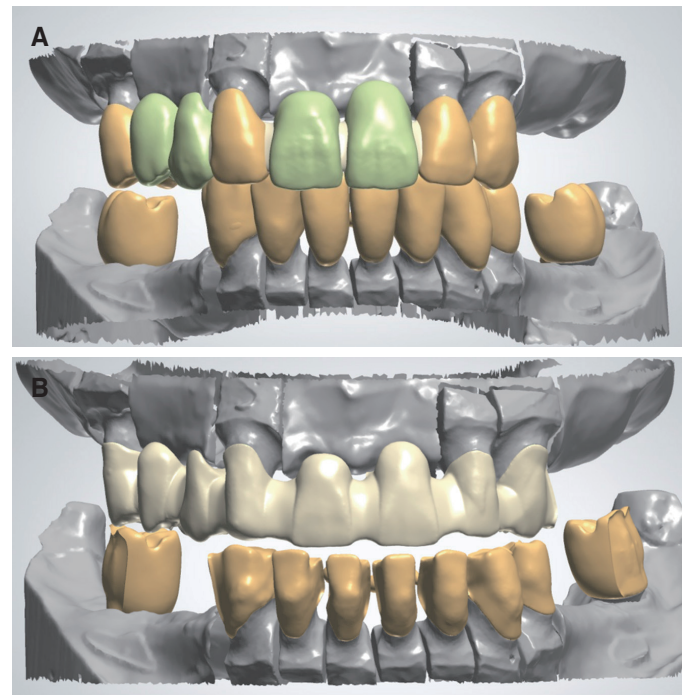


Fig. 6. Computer-aided design for porcelain fused metal framework fabrication using laser sintering technique. (A) Full contour design, (B) Cut-back.

Fit of RPD frameworks was examined intraorally with silicone material (Fit-checker, GC, Tokyo, Japan), which showed good adaptation and satisfactory retention. On top of the frameworks, baseplate wax (Truwax Baseplate Wax, Dentsply Inc., York, PA, USA) was build up to make occlusal wax rim and inter-occlusal relation was recorded with bite record material (O-bite, DMG, Hamburg, Germany). Master casts were mounted on articulator and denture teeth were aligned by mutually protected occlusion. After the trial of wax dentures, curing with pink denture resin (Rapid simplified, Vertex, Zeist, Netherlands) were carried on. Maxillary and mandibular removable partial dentures were delivered to the patient (Fig. 7). Oral hygiene instruction and regular follow up check were administered. After follow-up checks at one week, one month, six months, and 1 year interval, the result was functionally and esthetically satisfying.

Discussion

Loss of posterior support has been identified as the cause for severe anterior attrition and decreased OVD.¹⁰ In this case, it is considered that the pathological teeth wear has progressed as the mandibular natural anterior teeth are occluded with the maxillary PFM restorations. The reduced OVD was restored and the posterior support was established through full mouth rehabilitation using surveyed crowns, removable partial dentures, and implants. Freeway

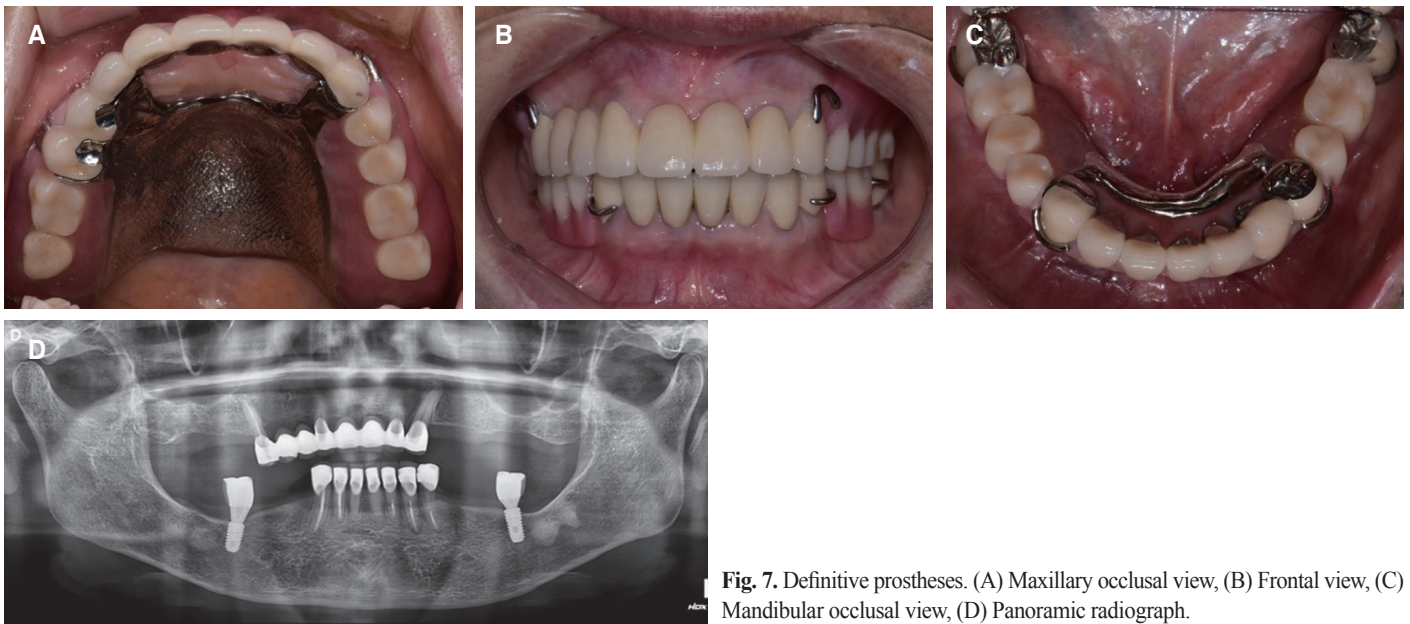


Fig. 7. Definitive prostheses. (A) Maxillary occlusal view, (B) Frontal view, (C) Mandibular occlusal view, (D) Panoramic radiograph.

space, interocclusal space for restoration and facial appearance were carefully evaluated to determine the amount of OVD increment, and OVD was increased by 2 mm through prosthetic rehabilitation. In general, increasing OVD up to 5 mm is considered to be a feasible alteration and whether an alteration of OVD exceeds the capacity of the neuromuscular system should be evaluated through provisional restorations or removable appliances.¹¹ The patient used the provisional restorations for about 4 months and there were no discomforts, temporomandibular joint disorders, and wears or fractures of the provisional restoration. In the definitive restorations, the anterior guidance was established by fixed restorations on the anterior teeth and uniform occlusal contact of the posterior teeth was achieved in the centric occlusion, preventing recurrence of wears and blocking lateral forces to the posterior implants. No abnormal findings were found during the follow-up period of 1 year. It is necessary to confirm the maintenance of occlusion through periodic observation, and occlusal adjustment or denture relining may be required.

In this case, the laser-sintering technique used in the fabrication of metal frameworks of PFM restorations is a new computer aided design/computer aided manufacturing (CAD/CAM) method. Based on the three-dimensional CAD data, high intensity laser can rapidly fuse base metal alloy powder. This technique can save manufacturing time and costs compared to the lost wax casting technique and good results have been reported in respect of internal fit, bond strength with porcelain, and strength.^{12,13} Because of the risk of casting distortion for maxillary long-span PFM framework, laser-sintering tech-

nique was used in this case and good marginal fit of the frameworks was confirmed.

The mandibular Kennedy Class I RPD requires periodic denture relining to establish posterior support, because the alveolar ridge under the distal extension resorbs. Therefore, a cost-effective method to solve this problem has been reported by several authors, which is to establish the posterior support by placing implants in the posterior region.^{14,15} This treatment which provides additional support and retention to removable partial denture using a small number of implants is referred to as implant-assisted removable partial denture (IARPD).¹⁶

In this case, the patient wanted an economical treatment and rejected complicated surgery, so IARPD was fabricated and delivered by placing implants at the mandibular second molar sites. Since 2016, in Korea, dentures and implants for elderly patients over 65 years old have been covered by national health insurance. Because up to two implants including upper prosthesis are covered by national health insurance, two implants were placed in the mandibular left and right second molar sites, and implant surveyed crowns were fabricated. Therefore, the effect of converting the mandibular Kennedy Class I RPD to the Kennedy Class III RPD was obtained.

The technique using surveyed crowns on implants in IARPD has been reported only in case reports and all cases were about distal extension RPD.¹⁷⁻²⁰ On the other hand, in this case, two single implants were placed on the mandibular posterior molars, and the occlusal rests and the retention arms were designed on the implant surveyed crowns, so it was suspected that functional force will be exerted on

the implant during insertion, removal and function. However, the bone quality of implants insertion site was good, and the measured implant stability quotient (ISQ) values were 88 (mandibular left implant) and 86 (mandibular right implant). It is also expected that the implants will have a good prognosis because the occlusal force on the implants will not be large due to the opposing maxillary distal extension RPD and because the implant is protected during lateral & protrusive excursion by canine guidance.

Conclusion

In this case, the OVD of the patient was evaluated by examining freeway space, interocclusal space for restoration and analyzing facial appearance. Based on this, diagnostic wax-up was made to determine occlusal restoration, and a temporary prosthesis was fabricated to evaluate the patient's adaptation to the increased OVD. After confirming patient's comfort, full mouth rehabilitation with combination of removable partial denture and few implants was completed. This resulted in economical, functional, and esthetically pleasing outcome.

ORCID

Shin Eon Lee <https://orcid.org/0000-0002-7478-6478>

Su Young Lee <https://orcid.org/0000-0003-4024-6139>

References

- Hattab FN, Yassin OM. Etiology and diagnosis of tooth wear: a literature review and presentation of selected cases. *Int J Prosthodont* 2000;13:101-7.
- Smith BG, Knight JK. A comparison of patterns of tooth wear with aetiological factors. *Br Dent J* 1984;157:16-9.
- Smith BG, Knight JK. An index for measuring the wear of teeth. *Br Dent J* 1984;156:435-8.
- Dawson PE. Functional occlusion: from TMJ to smile design. St. Louis; Mo: Mosby; 2007, p. 430-52.
- Jahangiri L, Jang S. Onlay partial denture technique for assessment of adequate occlusal vertical dimension: a clinical report. *J Prosthet Dent* 2002;87:1-4.
- Muts EJ, van Pelt H, Edelhoff D, Krejci I, Cune M. Tooth wear: a systematic review of treatment options. *J Prosthet Dent* 2014;112:752-9.
- Turner KA, Missirlian DM. Restoration of the extremely worn dentition. *J Prosthet Dent* 1984;52:467-74.
- Ibbetson RJ, Setchell DJ. Treatment of the worn dentition: 2. *Dent Update* 1989;16:300-2, 305-7.
- Grippio JO, Simring M, Schreiner S. Attrition, abrasion, corrosion and abfraction revisited: a new perspective on tooth surface lesions. *J Am Dent Assoc* 2004;135:1109-18.
- Verrett RG. Analyzing the etiology of an extremely worn dentition. *J Prosthodont* 2001;10:224-33.
- Abduo J, Lyons K. Clinical considerations for increasing occlusal vertical dimension: a review. *Aust Dent J* 2012;57:2-10.
- Tang Y, Loh HT, Wong YS, Fuh JYH, Lu L, Wang X. Direct laser sintering of a copper-based alloy for creating three-dimensional metal parts. *J Mat Proc Tech* 2003;140:368-72.
- Akova T, Ucar Y, Tukay A, Balkaya MC, Brantley WA. Comparison of the bond strength of laser-sintered and cast base metal dental alloys to porcelain. *Dent Mater* 2008;24:1400-4.
- Keltjens HM, Kayser AF, Hertel R, Battistuzzi PG. Distal extension removable partial dentures supported by implants and residual teeth: considerations and case reports. *Int J Oral Maxillofac Implants* 1993;8:208-13.
- Kuzmanovic DV, Payne AG, Purton DG. Distal implants to modify the Kennedy classification of a removable partial denture: a clinical report. *J Prosthet Dent* 2004;92:8-11.
- Schneid TR, Mattie PA. Implant-assisted removable partial dentures. In: Phoenix RD, Cagna DR, DeFreest CF, editors. *Stewart's clinical removable partial prosthodontics*. 4th ed. Chicago; Quintessence Publishing Company; 2008. p. 259-77.
- Jang Y, Emtiaz S, Tarnow DP. Single implant-supported crown used as an abutment for a removable cast partial denture: a case report. *Implant Dent* 1998;7:199-204.
- Pellecchia M, Pellecchia R, Emtiaz S. Distal extension mandibular removable partial denture connected to an anterior fixed implant-supported prosthesis: a clinical report. *J Prosthet Dent* 2000;83:607-12.
- Starr NL. The distal extension case: an alternative restorative design for implant prosthetics. *Int J Periodontics Restorative Dent* 2001;21:61-7.
- Chronopoulos V, Sarafianou A, Kourtis S. The use of dental implants in combination with removable partial dentures: a case report. *J Esthet Restor Dent* 2008;20:355-64.

심한 마모를 가진 환자에서 임플란트와 가철성 국소의치를 이용한 전악수복 증례

이신언 · 이원섭 · 이철원 · 이수영*

가톨릭대학교 의과대학 서울성모병원 치과보철과

과도한 치아 마모는 수직 고경 감소를 초래하고 구강 환경과 저작계의 병적 변화를 유발할 수 있다. 수직 고경과 교합을 회복시켜주기 위해서는 정확한 진단과 분석이 필수적이다. 본 증례에서는, 75세 여성환자로 구치부 지지 상실로 인한 치아 심한 마모가 관찰되었다. 따라서 수직 고경 거상을 동반한 전악 재건 수복을 계획하였다. 정확한 임상적 방사선학적 검사, 수직 고경 평가 후 진단 납형을 제작하였고 임시보철수복을 통해 환자의 적응여부를 평가하였다. 최종 수복은 환자의 경제적 상황을 고려하여 가철성 국소의치를 제작하였으며 하악 좌우측 구치부에 임플란트를 한 개씩 식립하여 국소의치의 지지와 유지를 보강하였다. 최종 수복물 장착 후 1년 간의 경과관찰 기간 동안 기능적, 심미적으로 만족할 만한 결과를 보였다. (*대한치과보철학회지* 2018;56:70-6)

주요단어: 전악 수복; 치아 마모; 수직 고경; 국소의치

*교신저자: 이수영

06591 서울 서초구 반포대로 222

가톨릭대학교 의과대학 서울성모병원 치과보철과

02 2258 1795: e-mail, lsuyoung@daum.net

원고접수일: 2017년 9월 4일 / 원고최종수정일: 2017년 9월 21일 / 원고채택일: 2017년 9월 27일

© 2018 대한치과보철학회

이 글은 크리에이티브 커먼즈 코리아 저작자표시-비영리 3.0 대한민국 라이선스에 따라 이용하실 수 있습니다.