

REHABILITATION OF A PATIENT WITH A POST RADIOTHERAPY TRISMUS WITH AN OBTURATOR AND A MAXILLARY DENTURE USING MAGNET ATTACHMENTS

Hanna Eun Kyong Bae¹, BDS, MSD, Jeong Ho Jeon², CDT,

Moon Kyu Chung^{3*}, DDS, PhD

¹Clinical Assistant Professor, Department of Prosthodontics, Yonsei University Dental Hospital,

²Dental Technician, Dental laboratory, Yonsei University Dental Hospital,

³Professor, Department of Prosthodontics, Yonsei University Dental Hospital

INTRODUCTION

Construction of an obturator is necessary to restore normal function and aesthetics in patients who had a resection of a tumor in the soft and hard palates. The design of the prosthesis is affected by the remaining supporting structures of the oral cavity, presence and extent of reconstructed tissue and the severity and location of the lesion. Many adverse forces act on an obturator and these can be minimized by maximizing palatal coverage, selecting the proper occlusal scheme and utilizing direct retention to name a few methods.¹ Maximizing the lateral peripheral contour can increase retention and reduce vertical displacement by facilitating the skin grafted lateral wall of the defect.² This procedure can however, be more challenging when the patient suffers from trismus and the access is severely restricted.

A combination of surgery and radiotherapy is one of the methods for managing a head and neck cancer patient³ For the patients undergoing radiotherapy, numerous short and long term side effects are expected. One of the well known complications is trismus, which may have been caused by inflammation and insults to muscles of mastication and other surrounding tissues.^{4,6} Wang reported that the degree of trismus has been reported to increase continuously over time. In patients treated for nasopharyngeal carcinoma with radiotherapy, the maximum interincisal distance was reported to be reduced to 97% of its original distance in the

first nine weeks after radiotherapy. Further reduction to 73%, 69%, 68% and 67% were observed in 12, 24, 36, 48 months, respectively.⁵

Clinical applications of magnetic attachments in maxillofacial prostheses have been used as overdenture abutments and for attachments between components of the prostheses.⁷⁻¹¹ With improvements in magnetic attachments, the issues regarding corrosion have been overcome and an improved retentive force in a smaller device has been developed. The magnetic attachments are self limiting in transmitting forces vertically and horizontally, where no greater than the retention force of the attachment can be transferred to the other component.

In a large defect area where a single insertion path for a stable prosthesis was not possible, use of magnetic attachments to connect several pieces of a prosthesis have been reported to achieve stability and retention.^{7,8} This accommodates maximum use of anatomical features and undercuts. The aim of this clinical report is to describe prosthetic management in a patient with post-radiotherapy trismus.

CLINICAL REPORT

A 54 years old male patient, who was diagnosed with squamous cell carcinoma of the left maxilla, was referred to the Department of Prosthodontics from the Department of Ear, Nose and Throat for prosthetic management. The

Corresponding Author: Moon Kyu Chung

Department of Prosthodontics, Yonsei University Dental Hospital

250 Seongsanno, Seodaemun-gu, Seoul, 120-752, Korea +82 2 2228 3156; e-mail, mcdh@yuhs.ac

Received October 22, 2008 Last Revision November 24, 2008 Accepted November 26, 2008.

patient received a subtotal maxillectomy and subsequently developed severe trismus after the radiotherapy on the left maxilla of a total dose of 6,480 cGy.

A surgical obturator was fabricated and delivered during surgery while further adjustments were made post operatively.¹³ An intermediate obturator was delivered after the radiotherapy but the patient failed to attend the clinic for the follow up appointments until 6 months after radiotherapy. His main concern was that he was unable to place the intermediate obturator intraorally for the last few weeks. The intraoral examination had revealed severe trismus, where no vertical distance between the maxillary and mandibular canine was present at maximum mouth opening. The patient was educated and instructed to use tongue blades to increase mouth opening. After 4 months the patient gained a 9 mm maximum intercanine distance (Fig. 1 a, b).

The patient had three remaining dentition on the upper arch. The upper right lateral incisor root was endodontically treated and retained and the remaining upper right canine and first premolar teeth had reduced periodontal support.

Despite the compromised prognosis the patient had refused any further treatment other than construction of the obturator. Additionally, an ongoing inflammatory lesion of 5mm in diameter was observed at the lateral posterior wall of the defect area. This was histologically investigated and was found to be granulation tissue and no abnormal hypermetabolism was noted in the PET (Positron Emission Tomography) scan. Therefore, a conservative treatment option was taken by the surgeons.

To compensate for the compromised direct retention, maximum use of the lateral periphery contour of defect and scar tissue was desired. The increase in the maximum intercanine distance, however, was insufficient to obtain the impression of the desired area or a path of insertion for one piece prosthesis to achieve adequate retention from the surgical defect area. For these reasons an obturator and a temporary maxillary denture was planned utilizing magnetic attachments.

The primary impression for the obturator was made with wax (Utility Wax, Daedong In., Daegu, Korea) and irreversible hydrocolloid, followed by the final impression

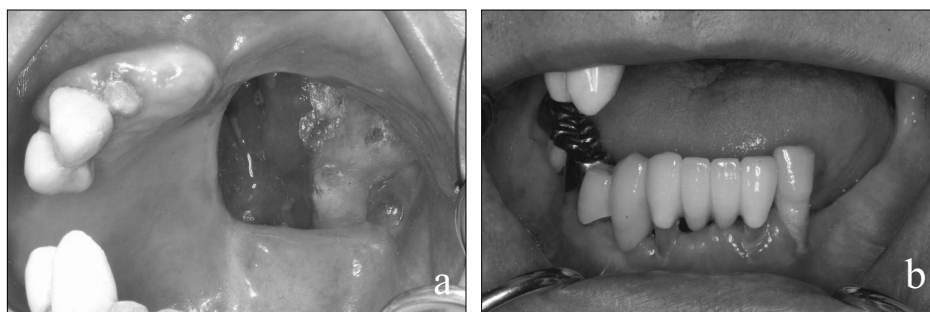

Fig. 1. **a** The occlusal view of the healed maxilla after a subtotal maxillectomy and radiotherapy. **b** Limited maximum intercanine distance even after use of tongueblades to improve mouth opening due to trismus.

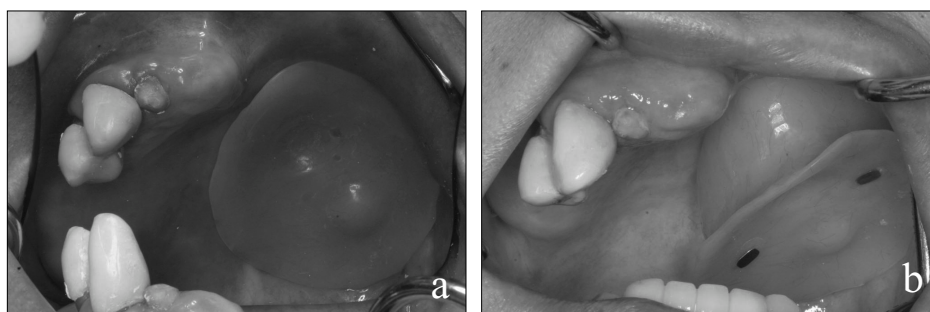


Fig. 2 . **a** Intraorally fully seated obturator. **b** The obturator at mid of its medio-anterior rotational insertion path.

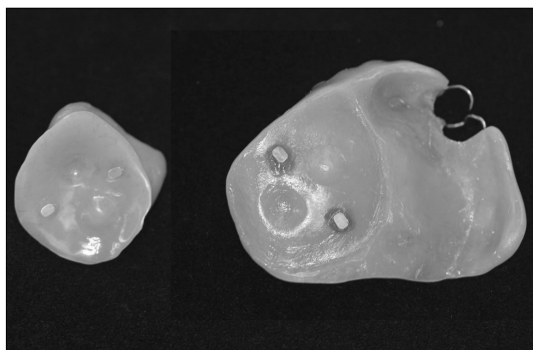


Fig. 3. Matching surface of the obturator and the maxillary denture after placing attachment components.

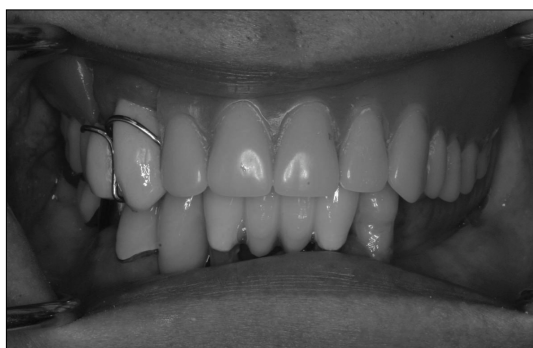

Fig. 5. The intraoral view of the prosthesis in position.

with an individual tray using a modeling plastic impression compound (Modelling compound medium, GC Co., Tokyo, Japan) and addition silicon (Aquasil XLV Ultra, Dentsply, Milford, USA) with the wash impression technique. The obturator was constructed maximizing use of the lateral defect wall and bucco-anterior undercut, and a small extension of approximately 5 mm over the palatal surface at the defective margin was placed to prevent vertical displacement of the obturator. The palatal surface of the obturator was designed with two small positioning references of small semi circular indentations and projections. The insertion of the obturator into the defect was possible in a rotational path; from medio-distal to bucco-anterior (Fig. 2 a, b).

The obturator was fully seated and confirmed that the prosthesis was easily placed and removed by the patient. A further irreversible hydrocolloid impression with the obturator in position was taken and the maxillary denture was constructed in a conventional manner. Meanwhile in the laboratory, two dental magnet attachments (Magfit EX 600, Aichi Steel Corporation, Tokai-shi, Japan) were placed

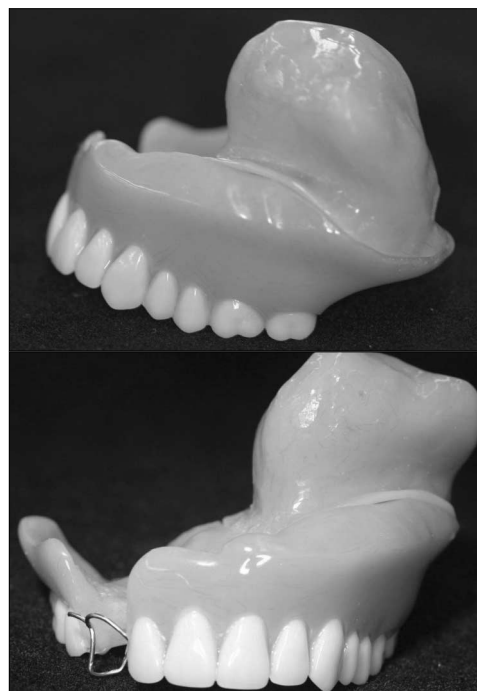

Fig. 4. The extraoral lateral and front view of compiled prosthesis.

on the palatal side of the obturator, one on the anterior-buccal and one on the medio-distal side (Fig. 3).

When the maxillary denture was constructed the obturator and the denture were tried in the mouth for their fit. When the fit was satisfied the keepers were placed on the antagonistic surface of the maxillary denture at the chair side with a self-curing acrylic resin (Pattern resin LS, GC America Inc. Apsip. USA) and the prosthesis was delivered (Fig. 4, 5). The patient was more compliant with the follow up appointments. On intraoral examination, there were no impingements of the palatal surface at the junction between the obturator and the denture nor were other discomforts noted. At the 6 month evaluation of the prosthesis, no further complications were found. The patient was satisfied with the function, aesthetic and retention of the prosthesis and greatly improved oral hygiene and maintenance were observed.

DISCUSSION

The advantages of these kinds of prostheses are that the

oral portion of the prosthesis can be remade readily when necessary in acrylic resin or in combination with framework and continue to use the same keepers. Secondly, due to improved fit and comfort, improved patient compliance and attendance could be achieved. Prior to delivery of the prosthesis, tissue impingement between the obturator and the denture from vertical occlusal force was of concern, but with adequate examination of the fit surfaces, no complications were noted. Lastly, the retentive forces from the magnet attachments were sufficient to retain the peripheral seal of the denture during the function. However, this technique will be contraindicated for patients who are unable to place or remove the obturator and prostheses due to reduced manual dexterity. The technique was easy to achieve and may be used in clinically challenging situations when maximum use of anatomical features are greatly needed.

SUMMARY

A separate obturator enabled the use of the buccal tissue undercut and lateral wall contour more satisfactorily with greater retention and stability of the prosthesis.

REFERENCE

1. Aramany MA. Basic principles of obturator design for partially edentulous patients. Part II: Design principles. 1978 [classical article]. *J Prosthet Dent* 2001;86:562-8.
2. Brown KE. Peripheral consideration in improving obturator retention. *J Prosthet Dent* 1968;20:176-81.
3. Kademani D, Bell RB, Schmidt BL, Blanchaert R, Fernandes R, Lambert P, Tucker WM. Oral and maxillofacial surgeons treating oral cancer: a preliminary report from the American Association of Oral and Maxillofacial Surgeons Task Force on Oral Cancer. *J Oral Maxillofac Surg* 2008;66:2151-7.
4. Sciubba JJ, Goldenberg D. Oral complications of radiotherapy. *Lancet Oncol* 2006;7:175-83.
5. Wang CJ, Huang EY, Hsu HC, Chen HC, Fang FM, Hsiung CY. The degree and time-course assessment of radiation-induced trismus occurring after radiotherapy for nasopharyngeal cancer. *Laryngoscope* 2005;115:1458-60.
6. Dijkstra PU, Kalk WW, Roodenburg JL. Trismus in head and neck oncology: a systematic review. *Oral Oncol* 2004;40:879-89.
7. Boucher LJ, Heupel EM. Prosthetic restoration of a maxilla and associated structures. *J Prosthet Dent* 1966;16:154-68.
8. Javid N. The use of magnets in a maxillofacial prosthesis. *J Prosthet Dent* 1971;25:334-41.
9. Tokuhisa M, Matsushita Y, Koyano K. In vitro study of a mandibular implant overdenture retained with ball, magnet, or bar attachments: comparison of load transfer and denture stability. *Int J Prosthodont* 2003;16:128-34.
10. Gillings BR, Samant A. Overdentures with magnetic attachments. *Dent Clin North Am* 1990;34:683-709.
11. Thean HP, Khor SK, Loh PL. Viability of magnetic denture retainers: a 3-year case report. *Quintessence Int* 2001;32:517-20.
12. Beumer J, Curtis D, Firtell D. Restoration of acquired hard palatal defects: etiology, disability and rehabilitation. In: *Maxillofacial rehabilitation: prosthodontics and surgical considerations*. Beumer J III, Curtis TA, Marunick MT. St. Louis: Medico Dental Media Int 1996;225-84.

REHABILITATION OF A PATIENT WITH A POST RADIOTHERAPY TRISMUS WITH AN OBTURATOR AND A MAXILLARY DENTURE USING MAGNET ATTACHMENTS

Hanna Eun Kyong Bae¹, BDS, MSD, Jeong Ho Jeon², CDT,

Moon Kyu Chung^{3*}, DDS, PhD

¹*Clinical Assistant Professor, Department of Prosthodontics, Yonsei University Dental Hospital,*

²*Dental Technician, Dental laboratory, Yonsei University Dental Hospital*

³*Professor, Department of Prosthodontics, Yonsei University Dental Hospital*

Construction of an obturator for rehabilitation of a patient who underwent a maxillectomy is vital. Routinely a constructed obturator includes denture portion. A patient who may present anatomical limitations due to surgical or radiotherapy complications often challenges the clinician. Purpose: This clinical report describes a patient with severe trismus after surgical resection and radiotherapy treatment of a tumor in the upper left maxilla. Conclusion: This report describes the concepts of using a rotational path insertion for an obturator and a separately constructed maxillary denture. The stability and retention of the obturator were obtained from anatomical features. Where as these were achieved through magnetic attachments and the remaining edentulous ridge to ensure esthetic and function of the prosthesis.

KEY WORDS: Maxillectomy, Obturator, Post radiotherapy trismus

Corresponding Author: **Moon Kyu Chung**

Department of Prosthodontics, Yonsei University Dental Hospital

250 Seongsanno, Seodaemun-gu, Seoul, 120-752, Korea +82 2 2228 3156; e-mail, mcdh@yuhs.ac

Article history

Received October 22, 2008 Last Revision November 24, 2008 Accepted November 26, 2008.