

Maxillary distraction osteogenesis in the management of cleft lip and palate: report of 2 cases

Jin-Woo Kim, Sung-Ho Park, Jin-Hyun Jang, Myung-Rae Kim, Sun-Jong Kim

*Department of Oral and Maxillofacial Surgery, Ewha Womans University Mokdong Hospital,
Ewha Womans University School of Medicine, Seoul, Korea*

Abstract (J Korean Assoc Oral Maxillofac Surg 2011;37:321-8)

This study is to evaluate the growth and development of the maxilla advanced by transoral distraction osteogenesis of cleft lip and palate children. Subjects are two patients diagnosed as maxillary hypoplasia with cleft lip and palate, and followed up over 5 years after distraction. At the age of 11.4 years (mean), the distraction had been rendered and periodically taken lateral cephalograms were analysed to trace the growth of the maxilla. This cephalometric study showed continuous growth and development of the distracted maxilla to be stable through long term follow-up.

Key words: Distraction osteogenesis, Cleft lip and palate, Maxillary growth, Cephalometrics

[paper submitted 2011. 5. 2 / revised 2011. 7. 21 / accepted 2011. 7. 26]

I . Introduction

The selection of a proper treatment method in the treatment of cleft lip and palate (CLP) patients with severe maxillary hypoplasia is much complicated. This may be explained by palatal scar contracture, upper lip tension, and the fact that postoperative stability decreases due to large discrepancy of horizontal distance in these patients¹. Ross² has reported approximately 25% of CLP patients with class III malocclusion need surgical treatment. Although Le Fort I osteotomy has been widely performed, advancement of the maxilla in cleft patients is extremely difficult due to scars³ and a deficiency in bone and soft tissue may cause technical problems during surgery. Furthermore, 4-40% of patients undergoing Le Fort I osteotomy show various relapse patterns, which increases with long-term follow-up⁴. This may be attributed to scar contracture and remarkable interference of the nasal septum in CLP patients⁵. In contrast, special attention has been focused on distraction osteogenesis as a new surgical treatment which can compensate for the drawbacks of conventional orthognathic surgery techniques by inducing new bone formation by using

tension through gradual traction force. Since distraction osteogenesis was first described by Codivilla in 1905, it has been developed through clinical applications by Ilizalov. Polley and Figueroa⁶ applied this technique to patients with severe deficiencies in the maxilla and midface.

Since distraction osteogenesis has been applied to the maxilla and midface, it has been widely performed on CLP patients with class III malocclusion as a new treatment option. However, there have been few studies on the long-term follow-up results of maxillary growth after distraction osteogenesis, especially transoral approach. Whereas the mandible mainly shows normal growth in CLP patients, long term follow-up of maxillary growth in CLP patients after distraction osteogenesis has been relatively neglected, which may bring problems with predictability and stability. Therefore, we report the treatment outcomes of transoral distraction and the follow-up results of the growth of the distracted maxilla in terms of cephalometric parameters.

II . Cases report

We analyzed the clinical and cephalometric data from 2 patients with maxillary cleft deformities related to CLP who underwent distraction osteogenesis by a single clinician at Department of Oral and Maxillofacial Surgery, Ewha Womans University Mokdong Hospital. These two patients underwent cheiloplasty within one year of birth. The ages of the patients at distraction were 10 years 8 months and 12 years 10 months,

김 선 종

158-710 서울 양천구 목동 911-1

이화여자대학교 의과대학 이화여자대학교 목동병원 구강악안면외과

Sun-Jong Kim

*Department of Oral & Maxillofacial Surgery, Ewha Womans University
Mockdong Hospital, Ewha Womans University School of Medicine
911-1, Mok-dong, Yangcheon-gu, Seoul, 158-710, Korea*

TEL: +82-2-2650-5631 FAX: +82-2-2650-5764

E-mail: sjsj7777@ewha.ac.kr

respectively.(Table 1) Bone defect of hard palate and alveolar bone was reconstructed by iliac bone graft prior to distraction osteogenesis.

At surgery of distraction, a horizontal incision was made 5-10 mm superior to the mucogingival junction between bilateral first molar teeth. The anterior aspect of the maxilla and zygomatic buttress areas were exposed. The anticipated vector of the maxillary distraction was determined. The distractor was temporarily fixed at both zygomatic buttresses. To avoid damage to unerupted permanent tooth germ and previously repaired alveolar bone, the horizontal maxillary osteotomy was conducted superior to the level of conventional Le Fort I osteotomy. Minimal pterygomaxillary junction osteotomy was performed and the maxilla was not down-fractured. The distractor was then fixed to the zygomatic buttresses in the pre-planned position, and the maxilla was checked for sufficient mobility by activation of the distractor. After suture, the turning arm of distractor was fixed to the area between the incisor and canine teeth with microscrews and steel wires so that the patients or their parents might easily access and activate the

distractor. After the maxilla was checked for mobilization by rotating the screw clockwise, the distractor was returned to its original position.(Fig. 1)

After a latency period of 7 days, the maxilla was distracted 0.5 mm twice daily. The distractor was removed after a consolidation period of 12 weeks. The patients were observed with periodic follow-up for supervision of orthodontist and oral surgeon per three months and no additional surgeries were performed. Lateral cephalograms were taken immediately before surgery (T0), and immediately after distraction (T1), 6 months (T2), 1 year (T3), 2 years (T4) and 5 years (T5) after surgery.(Fig. 2)

To standardize the amount of maxillary movement and growth of the maxilla and mandible, the Natural Head Position (NHP) horizontal and vertical reference lines, as proposed by Madsen *et al.*⁷, were used. The horizontal reference line was defined as a line through the nasion rotated 7° upward from the sella-nasion, and the vertical reference line was defined as a line perpendicular to the horizontal line passing through the sella. The magnitude of the horizontal and vertical movement

Table 1. Patient information

	Patient I	Patient II
Age at the time of distraction	10 yr 8 mo	12 yr 10 mo
Cleft classification	Unilateral complete cleft lip and palate, Lt	Unilateral incomplete cleft lip and palate, Rt
Previous cheiloplasty	3 mo after birth	4 mo after birth
Previous cleft palate surgery	15 mo after birth	16 mo after birth
Previous reconstruction of alveolar cleft	anterior iliac bone graft reconstruction (9 yr 8 mo)	anterior iliac bone graft reconstruction (12yr 3mo)
Follow-up period	5 yr 8 mo	5 yr 3 mo
Preoperative overjet (mm)	-4.35	-5.84
Amount of advancement done (mm)	8.41	9.08
Postoperative overjet / last follow-up overjet (mm)	4.06/2.20	3.24/-1.75
Actual distracted amount (mm)	10/10 (Rt/Lt)	10/6 (Rt/Lt)
Orthodontic treatment after distraction	Camouflage treatment after distraction osteogenesis	Orthognathic surgery is planned due to remarkable growth of mandible

(yr: year[s], mo: month[s])

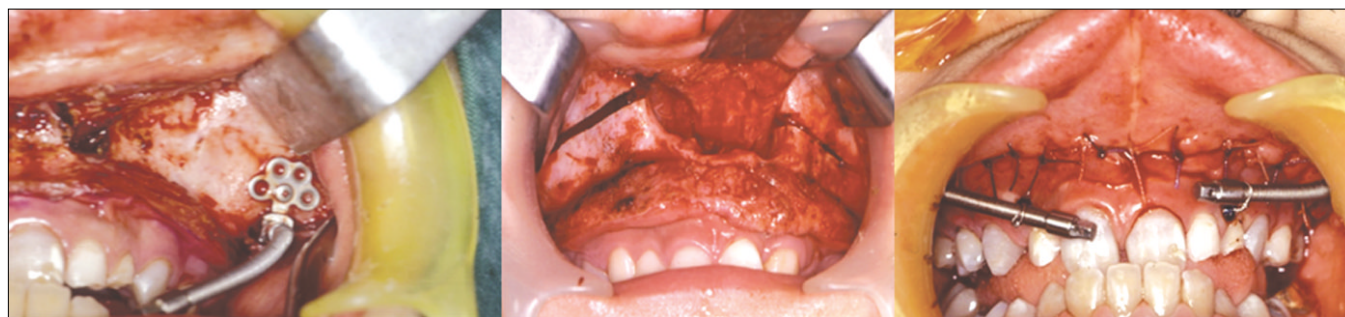

Fig. 1. Clinical photographs at surgery.

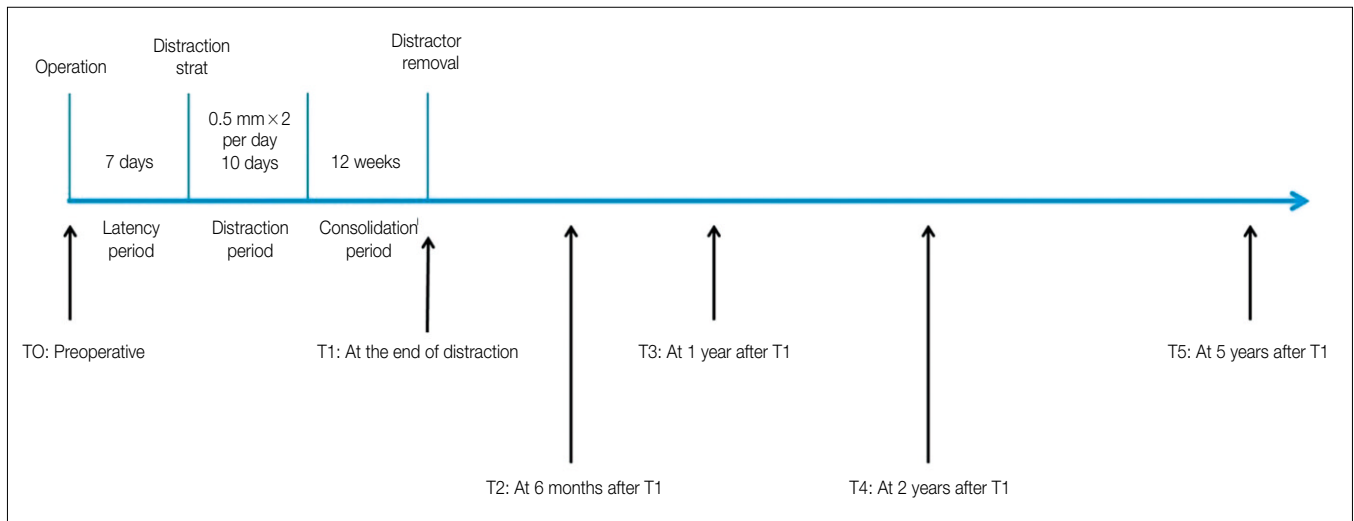


Fig. 2. Treatment protocol for maxillary distraction using an intraoral distractor.

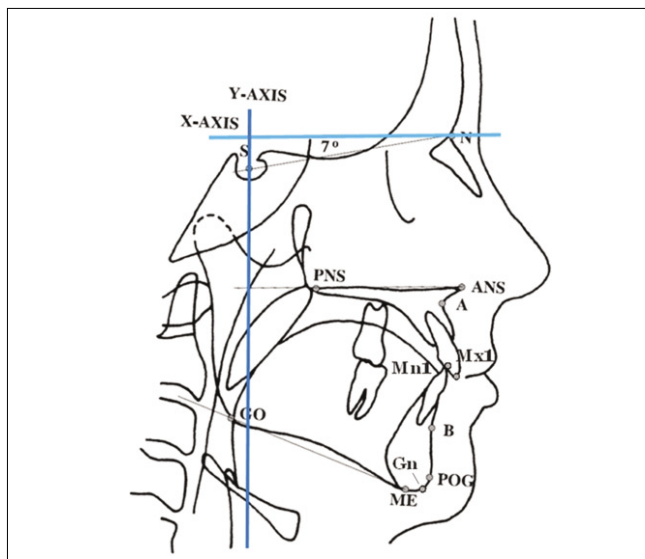


Fig. 3. Representation of landmarks and constructed lines used to identify craniofacial and dental parameters on lateral cephalometric radiograph. The following points were assessed: N: nasion, S: sella, ANS: anterior nasal spine, PNS: posterior nasal spine, A: subspinale, B: supramentale, Mx1: incisal edge of maxillary central incisor, Pg: pogonion, Gn: gnathion, Go: gonion, Me: menton, Mn1: incisal edge of mandibular central incisor, X-Axis: horizontal reference line-line through nasion rotated 7° upward from sella-nasion line, Y-Axis: vertical reference line-line perpendicular to horizontal reference line through sella.

of point A and B were measured on each lateral cephalogram, and SNA, SNB, ANB, upper incisor to SN, nasolabial angle, distance from the upper and lower lips to the E line, overjet and overbite were also measured.(Fig. 3) All measurements

were made by an oral surgeon and an orthodontist using the same program (V-ceph 5.5, Osstem, Seoul, Korea).

1. Case 1

The patient first reported to our department with multiple missing teeth at 5 years old. Cheiloplasty and hard palate surgery was done previously by plastic surgeons, and they referred the patient to our clinic for dental problems. He was diagnosed as complete unilateral CLP on the left side and skeletal Class III due to maxillary deficiency. Distraction of maxilla was planned and autogenous anterior iliac bone graft was performed 13 months prior to distraction due to bony defect of left side of hard palate and alveolar bone.

The patient's preoperative overjet was -4.35 mm and we intended for an overjet of +4 mm after distraction considering post-operative relapse. And since the direction of action of transoral distractor is not only forwards but also downwards, we decided to distract total of 10 mm in order to gain +4 mm overjet. Distraction osteogenesis was used in same amounts (10 mm) on both left and right sides. The maxilla showed increase in SNA (4.34°) and ANB (6.74°). From the horizontal and vertical reference lines, Point A moved a mean of 6.72 mm forward and a mean of 2.21 mm downward. The mandible showed posterior and downward rotation movements. Overjet increased 8.41 mm (-4.35-4.06 mm). During a period of 5 years and 8 months, decrease in ANB (1.58°) and SNA (2.30°) was observed. This decreasing tendency was particularly noticeable during the T2-T3 period rather than the T1-T2 period. From the horizontal and vertical reference lines, Point A

moved 2.80 mm forward and 7.88 mm downward. Overjet decreased by 1.86 mm (within 22% of baseline, 2.20 mm) which showed a Class I relationship. The maxillary anterior teeth to SN line angle increased by 10.34° due to camouflage

treatment. There were no complications from previous alveolar reconstruction and distraction osteogenesis. No extra follow up surgery is scheduled, and the patient will only be under orthodontic supervision until growth is finished.(Figs. 4-7, Table 2)

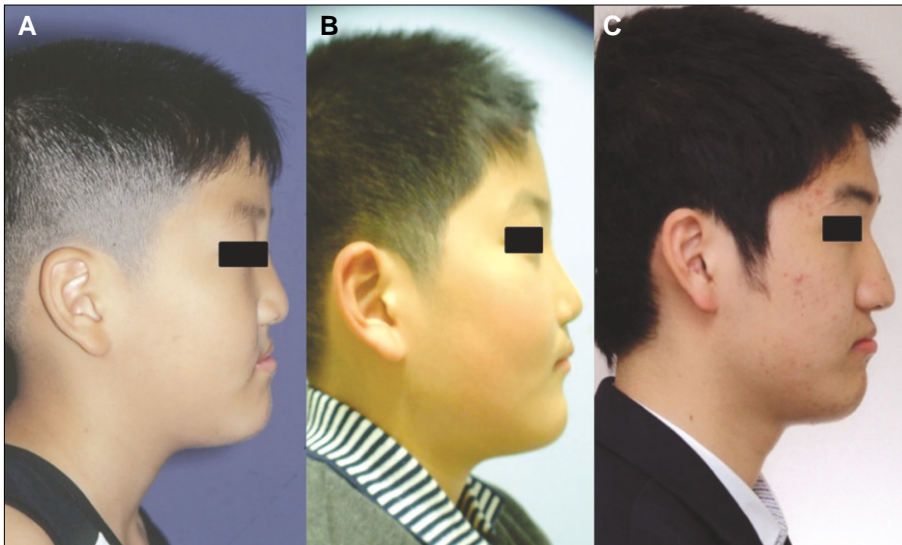


Fig. 4. Comparison of clinical photograph. A. Preoperative, B. After distraction osteogenesis, C. Post-op 5 years 8 months.

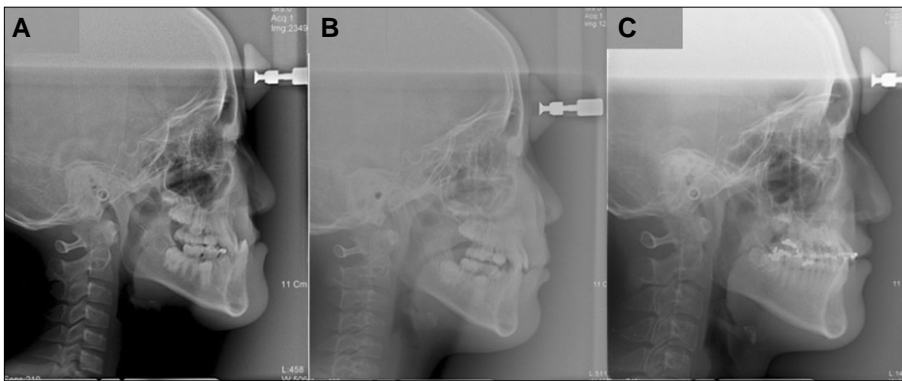


Fig. 5. Comparison of Lateral cephalogram. A. Preoperative, B. After distraction osteogenesis, C. Post-op 5 years 8 months.

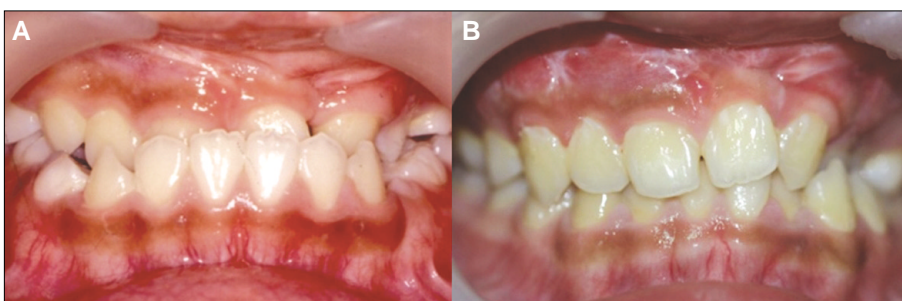


Fig. 6. Comparison of Introral photograph, frontal view. A. Preoperative, B. after distraction osteogenesis.

Table 2. Cephalometric analysis of patient I

	T0	T1	T2	T3	T4	T5	T1-T0	T5-T1
SNA (°)	74.11	78.45	78.14	76.54	76.97	76.87	4.34	-1.58
SNB (°)	80.10	77.70	77.57	79.12	79.59	78.42	-2.40	0.72
ANB (°)	-5.99	0.75	0.57	-2.58	-2.62	-1.55	6.74	-2.30
Point A to ver. reference line ¹ (mm)	60.19	62.40	62.33	65.54	68.48	70.28	2.21	7.88
Point A to hor. reference line ¹ (mm)	61.52	68.24	67.28	68.32	69.48	71.04	6.72	2.80
Point B to ver. reference line ¹ (mm)	98.82	97.42	100.03	100.62	114.81	118.42	-1.40	21.00
Point B to hor. reference line ¹ (mm)	77.72	77.04	77.82	80.48	80.42	79.02	-0.68	1.98
U1 to SN (°)	99.37	97.08	98.63	94.50	106.24	107.42	-2.29	10.34
Nasolabial angle (°)	83.35	95.62	93.56	95.31	91.13	89.42	12.27	-6.20
Upper lip to E-line (mm)	-7.42	-1.79	-1.70	-2.36	-4.24	-3.28	5.63	-1.49
Lower lip to E-line (mm)	-2.45	-1.60	-1.36	-1.23	-1.84	-1.89	0.85	-0.29
Incisal overjet (mm)	-4.35	4.06	5.68	3.10	2.40	2.20	8.41	-1.86
Incisal overbite (mm)	5.96	2.85	2.12	2.04	2.18	1.98	-3.11	-0.87

(T0: before distraction osteogenesis [DO], T1: after DO, T2: 6 months after DO, T3: 1 year after DO, T4: 2 years after DO, T5: 5 years after DO, ver: vertical, hor: horizontal)

¹: The natural head position (NHP) horizontal and vertical reference lines⁷ were used for measuring amount of Point A and B to reference lines. Refer to Fig. 3.

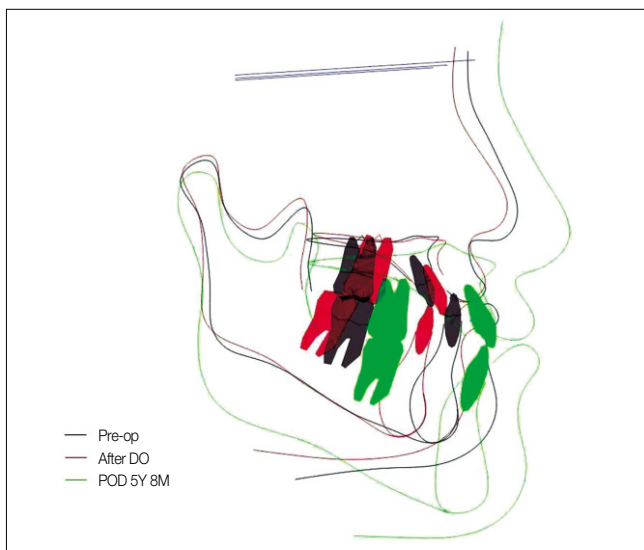


Fig. 7. Superimposition of Lateral cephalogram. (T0-Black, T1-Red, T5-Green)

2. Case 2

The patient first reported to our department with anterior cross-bite at 6 years old. Cheiloplasty and hard palate surgery was done previously by plastic surgeons. He was diagnosed as incomplete unilateral CLP on the right side and skeletal Class

III due to maxillary deficiency. Distraction of maxilla was planned and autogenous anterior iliac bone graft was performed 7 months prior to distraction due to bony defect of right side of hard palate and alveolar bone.

The patient's preoperative overjet was -5.84 mm and an overjet of +3 mm was planned according to the orthodontist's recommendation. Because right cleft resulted in collapse of maxillary dental arch with the dental midline offset to the right, we decided to correct maxillary yawing by distraction of different amount on each side. Distraction osteogenesis was done in different amounts on left (6 mm) and right (10 mm) side. The maxilla showed increases in SNA (3.44°) and ANB (7.23°), and post-operative dental midline showed similarity with facial midline. From the horizontal and vertical reference lines, Point A moved 7.05 mm forward and 1.98 mm downward. Overjet increased by 9.08 mm. During a period of 5 years and 3 months, increase in SNA (0.14°) and decrease in ANB (6.49°) were observed. From the horizontal and vertical reference lines, Point A moved 0.28 mm posteriorly and 7.20 mm downward. The mandible showed a significant increase in growth, leading to crossbite in T2 period and negative ANB values in T5 period. Overjet decreased by 4.99 mm (55% of baseline). No complication was observed on the maxillary right alveolar ridge which was treated with alveolar reconstruction. The facial midline was offset 1 mm to the left, but this will be treated through orthognathic surgery once growth is finished. (Figs. 8-10, Table 3)

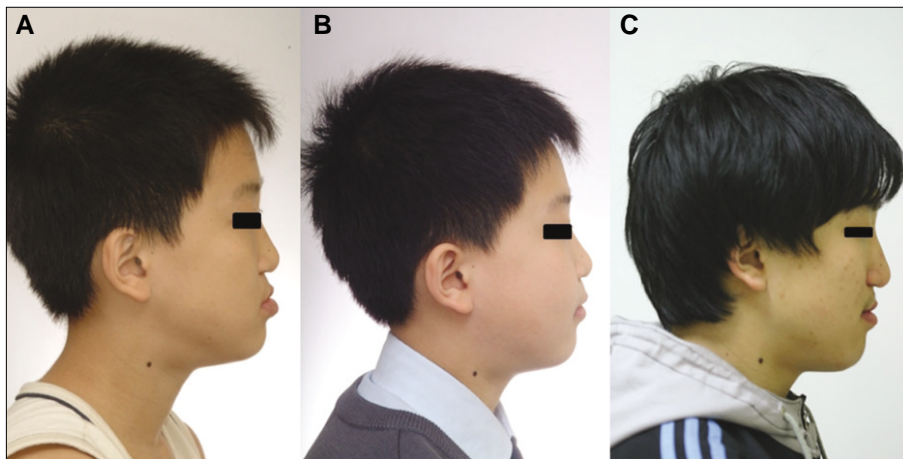


Fig. 8. Comparison of clinical photograph. A. Preoperative, B. After distraction osteogenesis, C. Post-op 5 years 3 months.

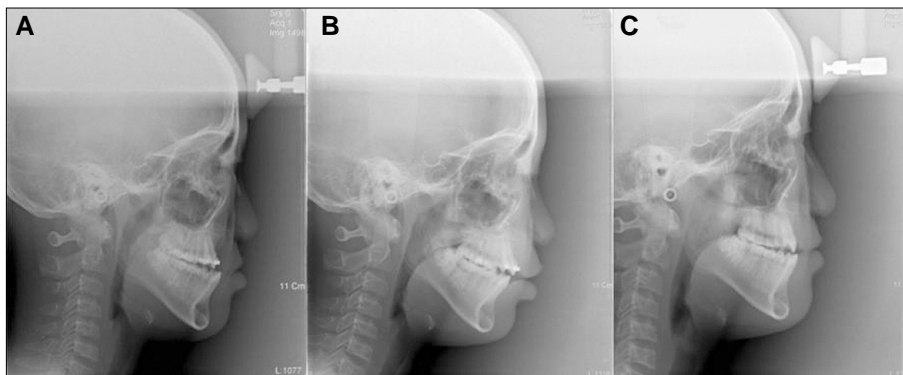


Fig. 9. Comparison of Lateral cephalogram. A. Preoperative, B. After distraction osteogenesis, C. Post-op 5 years 3 months.

Table 3. Cephalometric analysis of patient II

	T0	T1	T2	T3	T4	T5	T1-T0	T5-T1
SNA (°)	73.8	77.24	76.78	76.79	77.08	77.38	3.44	0.14
SNB (°)	75.58	71.79	72.89	74.24	75.27	78.42	-3.79	6.63
ANB (°)	-1.78	5.45	3.89	2.55	1.81	-1.04	7.23	-6.49
Point A to ver. reference line ¹ (mm)	79.24	81.22	82.49	84.42	86.28	88.42	1.98	7.20
Point A to hor. reference line ¹ (mm)	87.24	94.29	94.38	92.18	94.44	94.01	7.05	-0.28
Point B to ver. reference line ¹ (mm)	142.48	146.42	148.89	150.24	149.42	152.37	3.94	5.95
Point B to hor. reference line ¹ (mm)	79.42	77.71	79.89	80.42	80.84	84.24	-1.71	6.53
U1 to SN (°)	94.76	103.9	96.12	96.42	94.13	93.42	9.14	-10.48
Nasolabial angle (°)	92.48	88.51	82.1	80.93	89.61	88.42	-3.97	-0.09
Upper lip to E-line (mm)	-3.22	1.73	1.24	1.11	-1.85	-1.94	4.95	-3.67
Lower lip to E-line (mm)	5.42	4.83	4.88	4.72	1.76	2.42	-0.59	-2.41
Incisal overjet (mm)	-5.84	3.24	-0.01	-0.48	-1.24	-1.75	9.08	-4.99
Incisal overbite (mm)	-1.42	0.6	-0.22	-0.83	-0.42	-1.24	2.02	-1.84

(T0: before distraction osteogenesis [DO], T1: after DO, T2: 6 months after DO, T3: 1 year after DO, T4: 2 years after DO, T5: 5 years after DO, ver: vertical, hor: horizontal)

¹: The natural head position (NHP) horizontal and vertical reference lines⁷ were used for measuring amount of Point A and B to reference lines. Refer to Fig. 3.

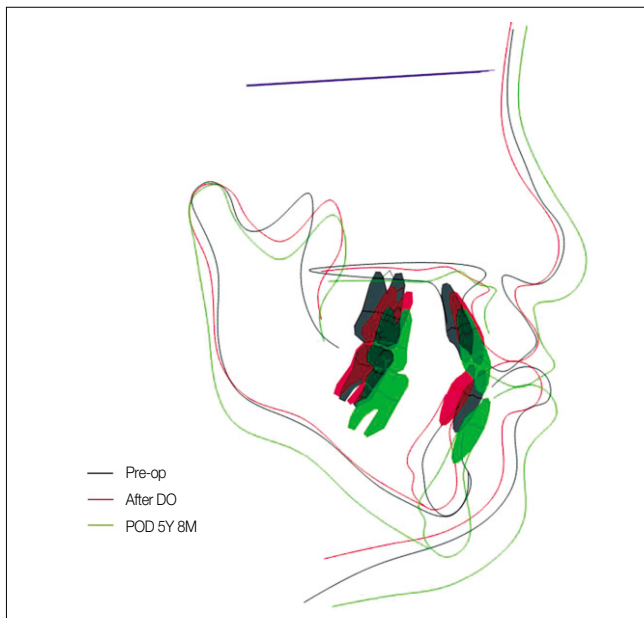

Fig. 10. Superimposition of Lateral cephalogram. (T0-Black, T1-Red, T5-Green)

III . Discussion

Distraction osteogenesis has been developed through improvements of osteotomy techniques and fixation of bone fragments. As Polley and Figueroa⁶ first performed distraction osteogenesis on patients with cleft deformities in the maxilla and midface, there have been numerous reports on successful forward movement of the maxilla by distraction osteogenesis^{4,8-10}. This method not only has the advantages of simplicity, safety and predictability, but also showed satisfactory outcomes in patients who have difficulty in undergoing conventional orthognathic surgery⁸. Distraction osteogenesis produces skeletal changes through traction force on callus, which accelerates tissue regeneration, especially in the soft tissue-deficient area surrounding the bone^{9,10}.

In conventional orthognathic surgery undergoing maxillary advancement, 5-80% of CLP patients showed post-operative relapse and long-term instability¹⁴⁻¹⁷. Cheung *et al.*¹¹ reported that the relapse rate of orthognathic surgery with respect to horizontal and vertical reference lines was 22% with long-term follow-up. Posnick and Dagys⁴ reported a vertical relapse of 19%, a horizontal relapse of 23% and a mean relapse of 6.9 mm. Thongdee and Samman¹² reported a horizontal relapse of 31% and a vertical relapse of 52% after maxillary surgical

movement in unilateral CLP with preceding alveolar bone grafting.

Louis *et al.*¹³ have shown that the relapse rate of orthognathic surgery becomes higher as the amount of maxillary advancement increases. Some investigators have demonstrated that the maximum of maxillary advancement achieved by conventional orthognathic surgery techniques is about 10 mm in CLP patients, therefore distraction osteogenesis can be performed when advancement over 10 mm is required^{13,14}. Even other investigators have stated that the maximum advancement by conventional orthognathic surgery techniques in CLP patients is 5 mm due to scar contracture^{14,15}. Based on these results, we have performed distraction osteogenesis in cases that require maxillary advancement of ≥ 5 mm. In our cases, we performed distraction osteogenesis with advancement of 10 mm in consideration of post-operative relapse and quantity we were to gain.

Cheung *et al.*¹⁸ have indicated that skeletal stability is better in distraction osteogenesis than in Le Fort I osteotomy, regardless of the magnitude of maxillary movement, because skeletal relapse occurs more frequently in Le Fort I osteotomy due to insufficient soft tissue. A previous meta-analysis in cleft children has suggested that the distraction is more effective in the treatment of severe cleft patients¹⁶. Rachmiel *et al.*¹⁷ had demonstrated that the relapse rate of distraction was smaller because of regeneration of membranous bone between the bone segments.

Kusnoto *et al.*²⁵ have proposed that the consolidation period should be adequately maintained because active bone formation occurs in the pterygoid region 6 weeks after maxillary distraction. In our cases, an adequate consolidation period of 12 weeks was given. In addition, after adequate maxillary movement was identified at surgery by activating distractors, the maxilla was not down-fractured with minimal dissection of soft tissue in the pterygomaxillary area and around the nasal cavity, which was based on the results reported by previous *in vitro* and *in vivo* studies^{18,19}.

In our cases, from the horizontal and vertical reference lines, Point A moved a mean of 6.89 mm forward and a mean of 2.10 mm downward after distraction. Because vector of intraoral distraction is anterior and inferior, about 7 mm of anterior movement was acquired. After a period of 5 years and 6 months, Point A moved a mean of 1.26 mm forward and a mean of 7.54 mm downward. This implies that a lower relapse rate in distraction osteogenesis than in orthognathic surgery may be attributed to the persistent growth of the maxilla after distraction osteogenesis, which is similar to the results reported by previous studies^{17,20,22}.

Distraction osteogenesis has been developed through numerous clinical and experimental studies and has various advantages over orthognathic surgery in cleft patients. Although postoperative normal maxillary growth was difficult to achieve due to scar contracture and tension from the upper lip in conventional method, distraction osteogenesis improved bone and soft tissue, and dentofacial structure through persistent maxillary growth.

In summary, distraction osteogenesis is thought to be able to provide improvements in facial aesthetic, a stable intermaxillary relationship and occlusion status due to persistent maxillary growth.

References

- Rachmiel A, Aizenbud D, Peled M. Long-term results in maxillary deficiency using intraoral devices. *Int J Oral Maxillofac Surg* 2005;34:473-9.
- Ross RB. Treatment variables affecting facial growth in complete unilateral cleft lip and palate. *Cleft Palate J* 1987;24:5-77.
- Erbe M, Stoelinga PJ, Leenen RJ. Long-term results of segmental repositioning maxilla in cleft palate patients without previously grafted alveolo-palatal cleft. *J Craniomaxillofac Surg* 1996;24:109-17.
- Posnick JC, Dagys AP. Skeletal stability and relapse patterns after Le Fort I maxillary osteotomy fixed with miniplates: the unilateral cleft lip and palate deformity. *Plast Reconstr Surg* 1994;94:924-32.
- McCarthy JG, Schreiber J, Karp N, Thorne CH, Grayson BH. Lengthening the human mandible by gradual distraction. *Plast Reconstr Surg* 1992;89:1-8.
- Polley JW, Figueroa AA. Management of severe maxillary deficiency in childhood and adolescence through distraction osteogenesis with an external, adjustable, rigid distraction device. *J Craniofac Surg* 1997;8:181-5.
- Madsen DP, Sampson WJ, Townsend GC. Craniofacial reference plane variation and natural head position. *Eur J Orthod* 2008; 30: 532-40.
- Kanno T, Takahashi T, Takano H, Funaki K, Ichida T. Simultaneous maxilla-mandibular distraction osteogenesis using a subcutaneous device for a bilateral cleft lip and palate patient. *Asian J Oral Maxillofac Surg* 2006;18:303-8.
- Figueroa AA, Polley JW, Friede H, Ko EW. Long-term skeletal stability after maxillary advancement with distraction osteogenesis using a rigid external distraction device in cleft maxillary deformities. *Plast Reconstr Surg* 2004;114:1382-92.
- Harada K, Sato M, Omura K. Maxillary distraction in patients with cleft deformity using a rigid external distraction device: a pilot study on the distraction ratio of the maxilla to the device. *Scand J Plast Reconstr Surg Hand Surg* 2004;38:277-80.
- Yamauchi K, Mitsugi M, Takahashi T. Maxillary distraction osteogenesis using Le Fort I osteotomy without intraoperative down-fracture. *Int J Oral Maxillofac Surg* 2006;35:493-8.
- Rachmiel A, Rozen N, Peled M, Lewinson D. Characterization of midface maxillary membranous bone formation during distraction osteogenesis. *Plast Reconstr Surg* 2002;109:1611-20.
- Satoh K, Mitsukawa N, Tosa Y, Kadamatsu K, Hosaka Y. Simultaneous hybrid of maxillary Le Fort I halo distraction and mandibular set-back for patients with severe cleft jaw deformity. *J Craniofac Surg* 2006;17:962-9.
- Proffit WR, Phillips C, Prewitt JW, Turvey TA. Stability after surgical orthodontic correction of skeletal Class III malocclusion. 2. Maxillary advancement. *Int J Adult Orthodon Orthognath Surg* 1991;6:71-80.
- Hoffman GR, Brennan PA. The skeletal stability of one-piece Le Fort I osteotomy to advance the maxilla; Part 1. Stability resulting from non-bone grafted rigid fixation. *Br J Oral Maxillofac Surg* 2004;42:221-5.
- Harada K, Sato M, Omura K. Long-term skeletal and dental changes in patients with cleft lip and palate after maxillary distraction: a report of three cases treated with a rigid external distraction device. *Cranio* 2005;23:152-7.
- Cheung LK, Chua HD, Hägg MB. Cleft maxillary distraction versus orthognathic surgery: clinical morbidities and surgical relapse. *Plast Reconstr Surg* 2006;118:996-1008.
- Cheung LK, Chua HD, Bendeus M. Distraction or osteotomy for the correction of maxillary cleft deformities: which is better? *Ann R Australas Coll Dent Surg* 2004;17:57-63.
- Thongdee P, Samman N. Stability of maxillary surgical movement in unilateral cleft lip and palate with preceding alveolar bone grafting. *Cleft Palate Craniofac J* 2005;42:664-74.
- Louis PJ, Waite PD, Austin RB. Long-term skeletal stability after rigid fixation of Le Fort I osteotomies with advancements. *Int J Oral Maxillofac Surg* 1993;22:82-6.
- Wang XX, Wang X, Yi B, Li ZL, Liang C, Lin Y. Internal mid-face distraction in correction of severe maxillary hypoplasia secondary to cleft lip and palate. *Plast Reconstr Surg* 2005;116:51-60.
- Cho BC, Kyung HM. Distraction osteogenesis of the hypoplastic midface using a rigid external distraction system: the results of a one to six-year follow-up. *Plast Reconstr Surg* 2006;118:1201-12.
- Cheung LK, Chua HD. A meta-analysis of cleft maxillary osteotomy and distraction osteogenesis. *Int J Oral Maxillofac Surg* 2006;35:14-24.
- Rachmiel A, Laufer D, Jackson IT, Lewinson D. Midface membranous bone lengthening: A one-year histological and morphological follow-up of distraction osteogenesis. *Calcif Tissue Int* 1998;62:370-6.
- Kusnoto B, Figueroa AA, Polley JW. Radiographic evaluation of bone formation in the pterygoid region after maxillary distraction with a rigid external distraction (RED) device. *J Craniofac Surg* 2001;12:109-17.
- Kanno T, Takahashi T, Ariyoshi W, Tsujisawa T, Haga M, Nishihara T. Tensile mechanical strain up-regulates Runx2 and osteogenic factor expression in human periosteal cells: implications for distraction osteogenesis. *J Oral Maxillofac Surg* 2005; 63:499-504.